

# Alexia With and Without Agraphia: An Assessment of Two Classical Syndromes

Claire A. Sheldon, George L. Malcolm, Jason J.S. Barton

**ABSTRACT: Background:** Current cognitive models propose that multiple processes are involved in reading and writing. **Objective:** Our goal was to use linguistic analyses to clarify the cognitive dysfunction behind two classic alexic syndromes. **Methods:** We report four experiments on two patients, one with alexia without agraphia following occipitotemporal lesions, and one with alexia with agraphia from a left angular gyral lesion. **Results:** The patient with occipital lesions had trouble discriminating real letters from foils and his reading varied with word-length but not with linguistic variables such as part of speech, word frequency or imageability. He read pseudo-words and words with regular spelling better, indicating preserved use of grapheme-to-phoneme pronunciation rules. His writing showed errors that reflected reliance on 'phoneme-to-grapheme' spelling rules. In contrast, the patient with a left angular gyral lesion showed better recognition of letters, words and their meanings. His reading was better for words with high imageability but displayed semantic errors and an inability to use 'grapheme-to-phoneme' rules, features consistent with deep dyslexia. His agraphia showed impaired access to both an internal lexicon and 'phoneme-to-grapheme' rules. **Conclusion:** Some cases of pure alexia may be a perceptual word-form agnosia, with loss of internal representations of letters and words, while the angular gyral syndrome of alexia with agraphia is a linguistic deep dyslexia. The presence or absence of agraphia does not always distinguish between the two; rather, writing can mirror the reading deficits, being more obvious and profound in the case of an angular gyral syndrome.

**RÉSUMÉ: Alexie avec et sans agraphie : revue de deux syndromes classiques. Contexte :** Selon les modèles cognitifs actuels, plusieurs processus sont impliqués dans la lecture et l'écriture. **Objectif :** Notre but était d'utiliser l'analyse linguistique pour clarifier la dysfonction cognitive sous-jacente à deux syndromes alexiques classiques. **Méthodes :** Nous rapportons quatre expériences effectuées chez deux patients, dont l'un présentait une alexie sans agraphie suite à des lésions occipitotemporales et l'autre une alexie avec agraphie suite à une lésion gyrale angulaire gauche. **Résultats :** Le patient porteur de lésions occipitales avait de la difficulté à distinguer de vraies lettres de simulacres de lettres et la lecture variait selon la longueur des mots, indépendamment de variables linguistiques comme la partie du discours, la fréquence des mots ou l'imageabilité. Il lisait des pseudo mots et il lisait mieux les mots dont l'épellation était régulière, ce qui indique que l'utilisation des règles de prononciation de graphème à phonème était préservée. À l'écriture on notait des erreurs qui témoignaient qu'il se fiait aux règles d'épellation de phonème à graphème. Par contre, le patient porteur d'une lésion gyrale angulaire gauche avait une meilleure reconnaissance des lettres et des mots ainsi que de leur signification. Sa lecture des mots dont l'imageabilité est élevée était meilleure, mais il faisait des erreurs de sémantique et était incapable d'utiliser les règles de graphème à phonème, témoignant d'une dyslexie profonde. Son agraphie témoignait d'une altération de l'accès à un lexique interne et aux règles de phonème à graphème. **Conclusion :** Certains cas d'alexie pure peuvent être une agnosie de perception de la forme des mots avec perte de la représentation interne des lettres et des mots alors que le syndrome gyral angulaire d'alexie avec agraphie est une dyslexie profonde linguistique. La présence ou l'absence d'agraphie ne permet pas toujours de faire la distinction entre les deux. L'écriture peut refléter les déficits de lecture qui sont plus évidents et plus sévères chez les patients atteints du syndrome gyral angulaire.

Can. J. Neurol. Sci. 2008; 35: 616-624

Alexia is traditionally classified according to the site of anatomic damage and to the presence or absence of deficits in writing and oral language.<sup>1</sup> Alexia without agraphia ('pure alexia') is associated with left occipital damage<sup>1-3</sup> while alexia with agraphia is associated with lesions of the left angular gyrus, and often accompanied by other left parietal signs, such as apraxia, anomia, and Gerstmann's syndrome.<sup>4</sup>

More recent studies have used linguistic and cognitive approaches to categorize alexia within a hierarchy of processing steps.<sup>1,5,6</sup> Peripheral alexias refer to 'sub-lexical' impairments in perceptual processing of letters and word-forms: reduced

perceptual efficiency results in a letter-by-letter strategy, with more difficulty for longer words, which have more perceptual elements to be processed. Central alexias are impairments in

From the Departments of Medicine (Neurology), Ophthalmology and Visual Science, and Psychology, University of British Columbia, Vancouver, BC, Canada.

RECEIVED JUNE 7, 2007. FINAL REVISIONS SUBMITTED MAY 5, 2008.

Correspondence to: Jason J S Barton, Neuro-ophthalmology Section D, VGH Eye Care Center, 2550 Willow Street, Vancouver, BC, Canada, V5Z 3N9.

translating perceptual data into meaning and speech, with phonological, surface, and deep subtypes. These subtypes reflect hypotheses that reading can occur via two routes: the 'indirect' route, in which pronunciation rules translate print to sound (grapheme-to-phoneme conversion), and the 'direct' route, in which the meaning and pronunciation of words is looked up in an internal lexicon. Phonological alexia is characterized by impaired grapheme-to-phoneme conversion while surface dyslexia is characterized by difficulty accessing the internal semantic lexicon, a process critical when reading words with irregular spelling. Deep dyslexia presents as a combination of both phonological and semantic errors.

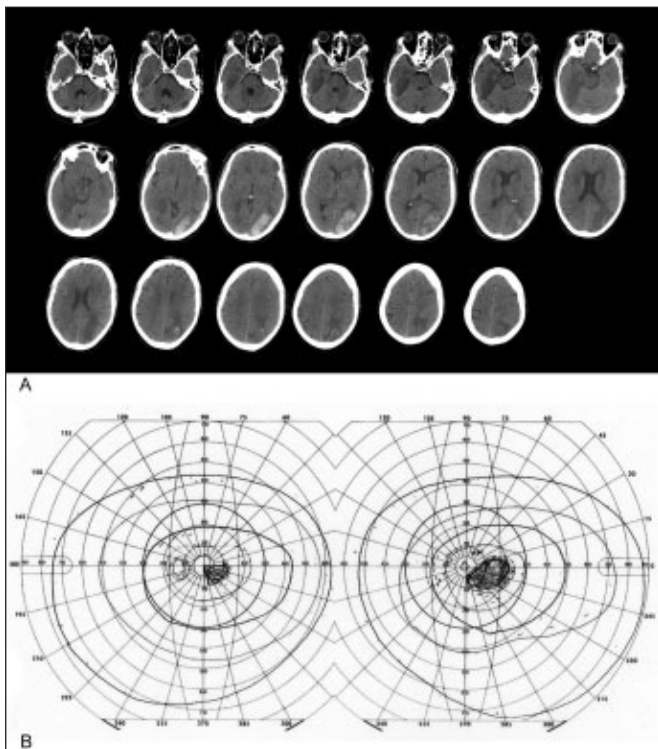
In this report we describe two patients, one with pure alexia from occipitotemporal lesions, and one with alexia with agraphia from an angular gyrus lesion. Our goal was to apply perceptual and linguistic tests of reading and writing to clarify our understanding of the cognitive pathophysiology underlying these syndromes.

### GENERAL METHODS

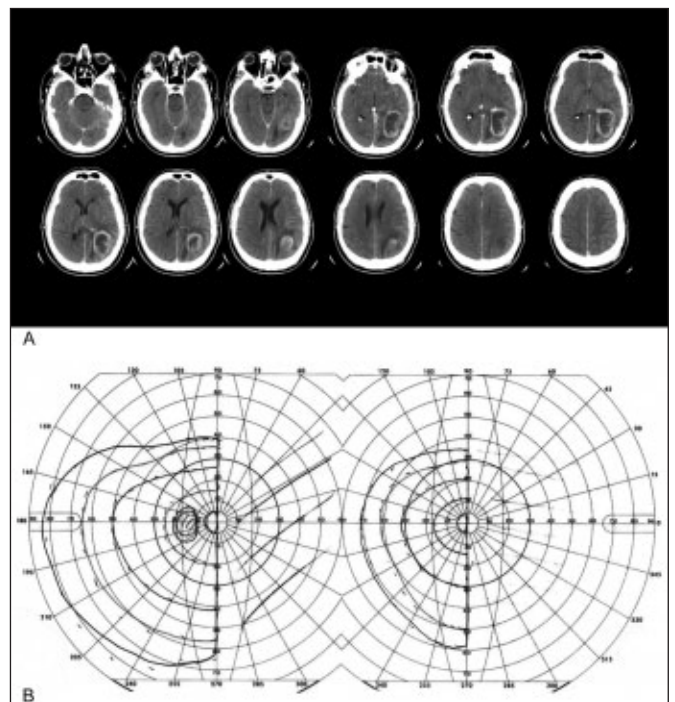
Patient JM(Occ) is a 69-year-old right-handed, English-speaking man with a Masters degree who is a retired mathematics teacher. Five months prior he had had a left occipital hemorrhage following anticoagulation for a deep

venous thrombosis, followed by a right occipital infarct during the same hospital stay. He complained of dyschromatopsia, impaired reading, and difficulty recognizing people. He hadn't noted problems with writing or recognizing other objects. On exam he had normal auditory comprehension, naming and spontaneous speech. Visual acuities were 20/20 in both eyes. Goldmann perimetry showed a small right homonymous paracentral scotoma. The Farnsworth-Munsell 100-hue test showed gross sorting errors for all hues. Reading was slow and laborious, but he wrote words and short sentences well to dictation and his own composition. Short-term memory for words on the Warrington Recognition Memory Test was normal (43/50). Recognition of line drawings was mildly impaired (he did not recognize a chair or a hammock). A test of famous face recognition confirmed prosopagnosia, and the Benton Face Recognition Test showed a severe impairment with facial perception (29/54). Neuro-imaging revealed a right posterior cerebral arterial infarction and residual left occipital hemorrhage, extending into medial temporal and parietal regions (Figures 1 and 3). In summary, he had central dyschromatopsia, alexia without agraphia, prosopagnosia, and a mild degree of object agnosia, a constellation that has been reported with bilateral medial occipital lesions.<sup>7,8</sup>

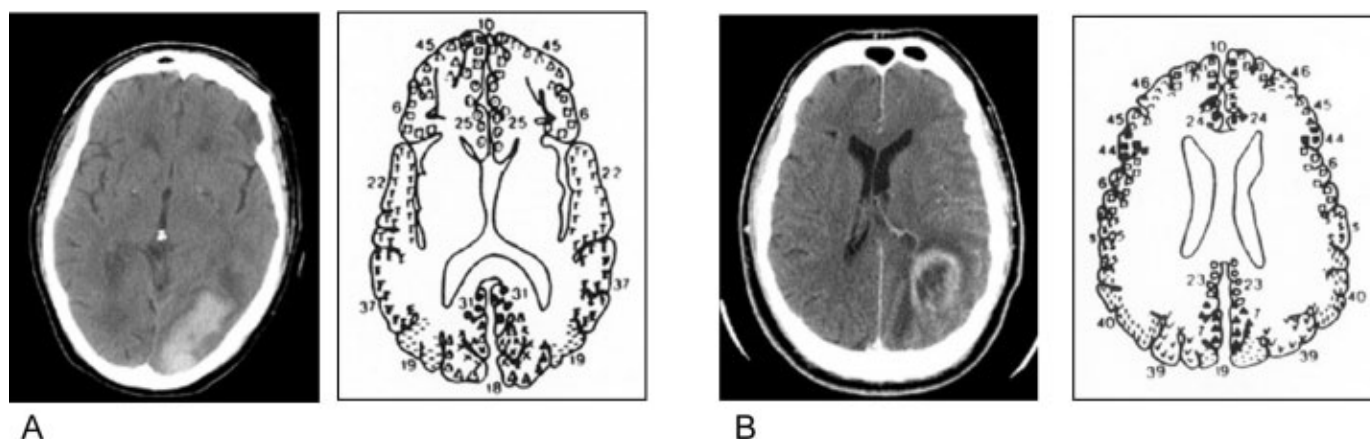
Patient MP(Par) is a 55-year-old right-handed, English-speaking high-school graduate who was a manager in a heavy equipment company. He presented with several weeks of daily



**Figure 1:** A. CT scan of JM(Occ)'s lesion showing left occipitotemporal damage. B. Goldmann perimetry of JM(Occ) showing a right homonymous paracentral scotoma (shaded region).



**Figure 2:** A. CT scan of MP(Par)'s lesion showing left temporoparietal damage. B. Goldmann perimetry of MP(Par) showing a complete right homonymous hemianopsia.



**Figure 3:** A. Comparison of JM(Occ)'s lesion with a corresponding template showing Brodmann's anatomically defined areas of the cerebral cortex. Areas #18 and #19 indicate the location of the visual association areas. B. Comparison of MP(Par)'s lesion with a corresponding template showing Brodmann's anatomically defined areas of the cerebral cortex. Area #39 and #40 indicates the locations of the angular and supramarginal gyri, respectively.

headaches. Neuro-imaging revealed a contrast-enhancing mass with vasogenic edema in the left angular gyrus (Figures 2 and 3). He had subtotal resection of the tumour, with pathology showing glioblastoma, and subsequently completed a course of radiation therapy and chemotherapy, following which he complained of trouble reading and writing. On examination visual acuities were 20/30 in the right eye and 20/25 in the left. Goldmann perimetry showed a dense macular-splitting right hemianopia (Figure 2). He had normal auditory comprehension and spontaneous speech, but occasional difficulty naming low-frequency items. Reading was severely impaired and writing showed numerous spelling and grammatical errors. He had trouble with simple arithmetical calculations, but did not show right/left disorientation or finger agnosia. Face and colour recognition were intact. Additional visual tests showed normal perception of curvature, angle, and line orientation using the Benton test, and normal recognition of famous faces. In summary, he presented with alexia with agraphia, acalculia, and a mild anomia, associated with a left lateral occipito-parietal lesion.

#### Apparatus and analysis

Experiments were run on a Macintosh G4 computer using Superlab 1.71 (Cedrus Inc, www.superlab.com) software in sessions over a period of five months. Subjects were seated 57 cm in front of the computer monitor. Stimuli sizes, ranging from 2 to 5° in height for letters and pictures, were easily visible for both patients.

The subjects performed a series of experiments, whose methods and results are detailed below. In each experiment statistical comparisons were made using  $\chi^2$  or ANOVA analysis, where appropriate, with level of significance set at  $\alpha = 0.05$ .

#### 1. Letter Recognition

The goal of the three tests in this first experiment was to determine whether the perceptual processing of letter-forms was normal. Difficulty processing letters would be more consistent

with a perceptual ('sub-lexical') dysfunction than a linguistic failure.

**Methods:** First, a letter/non-letter discrimination test presented subjects with 18 trials that showed two symbols sequentially for 2000ms each. One symbol was a capital letter and the other a mirror image of the same letter, and subjects were asked to indicate which was the real letter. Second, a vowel/consonant test presented five trials (one for each vowel), in which capital letters were shown, one a vowel and one a consonant, and subjects were asked to indicate which one was the vowel. Third, the embedded symbols test showed subjects ten words and ten non-words (words that contain one to three non-letters; e.g.  $\Delta$ APPLE, Z $\infty$ , H3@LTH7), one at a time in random order, and asked them to state whether the symbol string was a real word. Subjects indicated their response with a keypress, and both accuracy and reaction time were recorded.

**Results:** JM(Occ) had difficulty discriminating non-letters from real letters (13/18 correct), but had no difficulty identifying the vowel (5/5 correct). He incorrectly identified the non-word as a real word in 2/10 trials: 'FISH' as 'FISH' and 'Z $\infty$ ' as 'ZOO'. In contrast, MP(Par) correctly identified the properly oriented letter in 18/18 trials, the vowel in 5/5 trials, and all 10 non-words as non-words. The contrasts between JM(Occ) and MP(Par) showed a difference for letter identification ( $\chi^2(1, N = 36) = 3.9$ ,  $p < 0.05$ ). While the difference between the two subjects in accuracy for discriminating words from non-words did not reach statistical significance, ( $\chi^2 = (1, N = 20) = 2.2$ ,  $p = 0.13$ ), JM(Occ) took far longer than MP(Par) to complete this task: 27.1 s (s.d. 14.7) for JM(Occ) and 3.2 s (s.d. 1.4) for MP(Par) ( $p < 0.0001$ ). Thus JM(Occ) but not MP(Par) was impaired in identifying stimuli as real letters or words.

#### 2. Recognition and reading of real words and pseudo-words

The two tests of word reading in this section had two goals.

First, we determined whether reading varied with either perceptual or linguistic parameters. A hallmark of peripheral alexia from perceptual dysfunction is a word-length effect, in which the accuracy and/or reading time is proportional to the number of letters in the word.<sup>3,6</sup> On the other hand, central alexias show modulation by linguistic variables such as word frequency, word imageability (i.e. the ability of the word to conjure a visual image; 'concrete' vs. 'abstract'), parts of speech (i.e. nouns, modifiers and functors) and orthographic regularity of words (whether the word can be 'sounded out').<sup>9</sup> Second, we contrasted the reading of real words with that of pseudo-words: while peripheral alexias fail to show differences with respect to their abilities to read real vs. pseudo-words, phonological and deep, but not surface, dyslexics have an impaired ability to read pseudo-words (i.e. an impaired access to phonological knowledge).

**Methods:** In the first test subjects were shown 115 real words chosen from a published list of words of known word frequency

and imageability (Table 1).<sup>5,10,11</sup> Words varied in length from 2 to 11 letters and fell into one of ten categories: concrete high frequency, concrete low frequency, abstract high frequency, abstract low frequency, nouns, modifiers, functors, verbs, irregular and regular words.<sup>11</sup> In the second test pseudo-words and their corresponding real words (ten trials of each type; Table 1) were presented. In both tests words were shown one at a time with unlimited viewing time, in random order, and subjects were asked first to indicate with a keypress if the word was a real word, and second, to read it aloud. Immediately after the verbal response the experimenter documented the accuracy of the response by a second keypress. Results were analyzed for accuracy and reading time, as indicated by the total duration to the second key press.

**Results:** JM(Occ) recognized 40% (46/115) and pronounced correctly 51% (59/115) of the words (thus to direct questioning he could pronounce some words he did not recognize). Increasing word length reduced JM(Occ)'s reading accuracy ( $\chi^2$

**Table 1: Word list employed in reading and recognition of real words and pseudo-words\***

<i>Concrete - High Frequency</i>	<i>Concrete - Low Frequency</i>	<i>Abstract - High Frequency</i>	<i>Abstract - Low Frequency</i>
action	ambulance	go	applaud
brother	bomb	caught	fiction
chair	cabbage	colour	eldest
farm	clay	dear	jolly
notice	dad	famous	fuss
glass	estate	marry	indignation
fruit	fringe	moment	maintenance
village	iodine	peace	melody
whistle	movies	rich	swift
wound	plum	success	wicked
	squeak	tired	thirsty
<i>Nouns</i>	<i>Modifiers</i>	<i>Functor</i>	<i>Verb</i>
cabbage	beautiful	because	ambulate
kite	early	their	thrive
hammer	quickly	that	eat
antelope	friendly	which	sleep
boy	green	they	make
plant	soft	under	laugh
lantern	striped	the	sing
toilet	round	if	command
spider	carefully	and	absorb
lighthouse	vigorously	but	damage
eagle	big	despite	debate
thigh	sad	without	bleed
		instead	
		around	
<i>Regular words</i>	<i>Irregular words</i>	<i>Pseudo-words</i>	<i>Real words</i>
administer	colonel	mub	tub
hand	yacht	jat	hat
abdominal	island	sust	rust
spill	have	gort	fort
rug	borough	sild	mild
splash	stomach	stime	slime
enter	ratio	blape	blaze
dose	glacier	nolden	golden
limp	thigh	tolt	bolt
orchestra	leisure	zopped	topped
deputy	lose		

\* words selected from (5, 10, 11)



**Table 2: Comparison of JM(Occ)'s and MP(Par)'s ability to recognize correctly pseudo-words vs. real-words and to read words aloud**

	JM(Occ)		MP(Par)	
	Recognized	Read	Recognized	Read
Pseudo-words	10/10 *	5/10 *	5/10	0/10
Words	8/10	8/10 *	10/10	2/10

\* indicates a significant difference when comparing the fraction correct observed between the two subjects in the corresponding task ( $\alpha < 0.05$ , 1)

(9,  $N = 115$ ) = 19.9,  $p = 0.02$ ) and lengthened reading time by about 5 sec per letter (Figure 4A and B). For linguistic variables, there was a trend to significance for regularity, with JM(Occ) reading correctly 63% (7/11) of regular but 27% (3/11) of irregular words ( $\chi^2$  (1,  $N = 22$ ) = 2.9,  $p = 0.08$ ). JM(Occ)'s reading was not significantly affected by imageability or word frequency (Figure 5A). On the second test, JM(Occ) was 90% accurate (18/20) in discriminating pseudo-words from real words and correctly read 50% (5/10) of pseudo-words (Table 2).

MP(Par) recognized 77% (88/115) of words but could only correctly pronounce 18% (21/115). There was no effect of word length on MP(Par)'s accuracy or reading time (Figure 4). For linguistic variables, MP(Par)'s reading did not differ overall with the category of word (Figure 5A). However, while he read regular and irregular words equally well (18% for both), he was better at reading concrete (7/21 or 33% correct) than abstract words (1/22, or 4% correct) ( $\chi^2$  (1,  $N = 43$ ) = 5.9,  $p = 0.015$ ). With the second test, MP(Par) was 75% accurate (15/20) in discriminating pseudo-words from real words but could not read any pseudo-words (0/10): for example, while he could read "fort" and "hat", he could not read "gort" or "jat". We classified MP(Par)'s 94 errors by an established system (5): 2% were substitution errors, 10% were semantic errors, 11% were visual

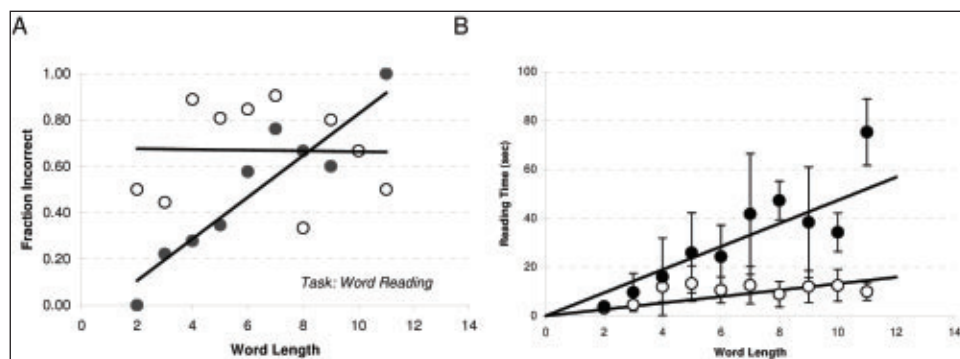
errors, 21% were undeterminable and, in the remaining 51%, MP(Par) did not offer a response. Substitution errors included reading 'sing' as 'song'; visual errors included reading 'quickly' as 'question' and 'movies' as 'moving'; semantic errors included 'beautiful' as 'pretty', 'but' as 'and' and 'cabbage' as 'vegetable'. MP(Par) also made a combined visual/semantic error in reading 'marry' as 'happy'.

The contrasts between JM(Occ) and MP(Par) showed that JM(Occ) was worse than MP(Par) at recognizing words ( $\chi^2$  (1,  $N = 115$ ) = 31.5,  $p < 0.0001$ ) but better than MP(Par) at reading real and pseudo-words aloud ( $\chi^2$  (1,  $N = 115$ ) = 27.7,  $p < 0.0001$  and  $\chi^2$  (1,  $N = 20$ ) = 6.7,  $p = 0.01$ , respectively).

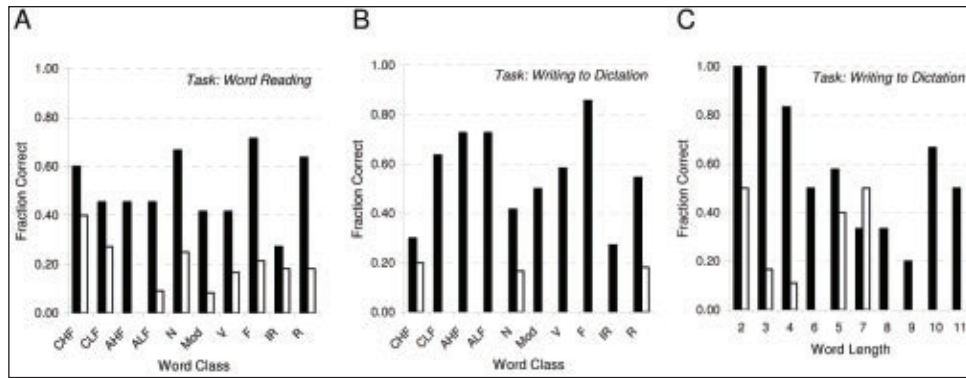
To summarize, JM(Occ) showed a word-length effect, a trend to an effect of orthographic regularity but not of other linguistic variables, and could read some pseudo-words, whereas MP(Par) showed no word-length effect, but rather an influence of imageability on reading, a more marked inability to pronounce pseudo-words, and produced semantic paralexias.

### 3. Reading comprehension in MP(Par)

Despite MP(Par)'s severe difficulty in reading words aloud, MP(Par) claimed to recognize many words. However, his high 77% rate of responding 'yes' to a question of 'do you recognize



**Figure 4:** The influence of word length on word reading accuracy and reading time. A. Fraction of words read incorrectly as a function of word length (number of characters in word) for JM(Occ) (●) and MP(Par) (○). B. Average reading time as a function of word length for JM(Occ) (●) and MP(Par) (○). Data points indicate the average reading time for a given word length ( $n = 2 - 26$ ); error bars are SD. Solid lines represent linear regression in A ( $r^2 = 0.85$  and  $0.001$  for JM(Occ) and MP(Par), respectively) and weighted non-linear regression analysis in B to the data points obtained from individual subjects (for JM(Occ), slope = 4.73 sec/letter,  $r^2 = 0.82$ ; for MP(Par), slope = 1.31 sec/letter,  $r^2 = 0.53$ ).



**Figure 5:** Parameters influencing reading and writing. Fraction of words read aloud correctly (A) and written correctly to dictation (B) as a function of word class for JM(Occ) (■) and MP(Par) (□); n = 11 - 14 in each group. C, Fraction of words written correctly as a function of word length (number of characters in word) for JM(Occ) (■) and MP(Par) (□) CHF = concrete high frequency, CLF = concrete low frequency, AHF = abstract high frequency, ALF = abstract low frequency, N = noun, Mod = modifier, V = verb, F = functor, IR = irregular, R = regular.

this word?’ could simply reflect a criterion bias rather than true recognition. To verify recognition, we examined whether he knew the meanings of written words.

**Methods:** We gave MP(Par) a picture/word matching test. This consisted of 20 pictures presented four times each (80 trials total). On each trial a word was written below the picture. On one trial the word was the correct (index) name, on one it was a

phonologically similar word, on one a semantically related word and on the last an unrelated word (see Table 3). MP(Par) was asked first to state if the word matched the picture and second to read the word aloud. Words were obtained from published lists: all were concrete and controlled for frequency effects. There was no time limit.

**Results:** MP(Par) was 15/20 correct on trials when pictures were shown with their real name: this 75% accuracy rate is nearly identical to his 77% rate of acknowledged word recognition in the previous experiment. In all five instances when MP(Par) claimed incorrectly that the picture did not match its index word (‘stomach’, ‘needle’, ‘fan’, ‘square’ and ‘paper’), he had difficulty reading the word aloud. On 2 of the 15 trials on which he did correctly match the picture and its index word (‘piano’ and ‘acrobat’), he read the index word incorrectly (‘pianist’ and ‘trapeze’). Thus, although correct matching was needed for MP(Par) to read index words, on occasion this lead to semantic paralexias.

MP(Par) was 100% accurate in recognizing that the picture did not match unrelated words or phonologically similar words. However, he incorrectly stated on 5 of 20 trials that a semantically related word matched the picture. On these five trials he did not read the word correctly, making semantic paralexical errors. For example, he incorrectly matched the word ‘orchestra’ with a picture of a ‘pianist’ and read the word as ‘symphony’, and incorrectly matched the word ‘soldier’ with a picture of a ‘sword’ and read the word as ‘knife’.

This experiment suggests that MP(Par) has relatively preserved word recognition and comprehension, although comprehension does not guarantee successful reading.<sup>12</sup> This test also suggests that his semantic paralexical reading errors originate while accessing word meaning prior to activating phonological output, consistent with hypotheses that semantic reading errors are generated because of compromised access to phonological output lexicon.<sup>13,14</sup>

**4. Writing words**

Few studies have assessed the reading and writing abilities of individual patients systematically in parallel. Some suggest that

**Table 3: Word list employed in reading comprehension in MP(Par)**

Index Word	Phonologically-Related Word	Semantically-Related Word	Non-Related Word
book	cook	card	bride
star	scar	moon	kitchen
mother	doctor	uncle	cushion
shoe	hat	foot	dump
carrot	cannon	salad	ring
bouquet	bodice	blossom	garage
fan	ram	water	kiss
king	wink	movies	hug
pianist	pinch	orchestra	drink
paper	party	ink	stem
oyster	ocean	water	fire
dog	door	armadillo	limp
church	child	school	scrub
stomach	store	tickle	war
sword	swing	soldier	iodine
acrobat	action	dance	jelly
money	muddy	income	butter
needle	kneel	prick	cut
square	squeak	rug	lake
Tree	beef	branch	train

the cognitive processes for writing parallel those of reading.<sup>15,16</sup> Patients with deep dyslexia may show ‘deep dysgraphia’<sup>17</sup> while those with letter-by-letter reading may exhibit ‘surface dysgraphia’.<sup>18</sup> However, others assert that alexic features may be dissociated from those of agraphia.<sup>19</sup>

**Methods:** Using the same real words as in the second experiment, the two subjects were asked to write words in response to dictation. There was no time limit and results were analyzed for accuracy. MP(Par) completed only one portion of this task.

**Results:** Despite denying writing problems, JM(Occ) wrote only 56.5% (65/115) of the words correctly. He was more successful when writing shorter than longer words ( $\chi^2$  (9, N = 115) = 22.4,  $p = 0.01$ ). Linguistic variables showed no effects. Writing of regular words did not differ significantly from irregular words ( $\chi^2$  (1, N = 22) = 1.71,  $p = 0.19$ ) (Figure 5B, C), and there was no effect of word imageability or word frequency, JM(Occ) rarely made errors of substitution, transposition or addition; the vast majority of his errors were phonological: for example, ‘bleed’ as ‘bleade’, ‘success’ as ‘suceess’, ‘striped’ as ‘strypt’ and ‘colonel’ as ‘kernell’.

MP(Par) demonstrated a marked agraphia (20% correct rate; 6/30), independent of word class or word length (Figure 5B, C). Common errors made by MP(Par) were addition, substitution and transpositions: ‘eagle’ as ‘eagaef’ (addition), ‘ambulance’ as ‘amburance’ (substitution) and ‘farm’ as ‘fram’ (transposition). He demonstrated an impaired understanding of the rules of phonology. For example, ‘spider’ was spelled as ‘sitre’, ‘kite’ as ‘kibe’, ‘hammer’ as ‘harer’. No semantic spelling errors were noted.

## DISCUSSION

We examined the performance of two subjects with different lesions and different traditional alexic syndromes on three different tasks. The results illustrate distinct contrasts in the perceptual and linguistic properties of not only their reading but also their writing abilities.

### *JM(Occ): Medial occipitotemporal damage and peripheral ‘word-form agnosia’*

JM(Occ)’s alexia appears to reflect a failure to generate accurate word-forms. He had trouble perceiving letters and with word-form decision tasks, and displayed a classic word-length effect. His reading was not affected by linguistic variables such as part of speech, word frequency, or imageability. These findings are characteristic of pure alexia. Patients with this disorder cannot access word knowledge and rely at best on a slow letter-by-letter reading strategy.<sup>3,5,6</sup> JM(Occ)’s neuro-imaging showed a left occipital hemorrhage and a right occipitotemporal infarct: the former is consistent with the association of pure alexia with lesions of the left medial occipital cortex.<sup>2,3,6,20</sup>

The traditional explanation of occipital alexia is a disconnection syndrome.<sup>21,22</sup> This postulates a failure of information transmission to language centers in the left angular gyrus from both the left hemifield, because of damage to callosal fibers in the splenium, and the right hemifield, usually because of right hemianopia, but sometimes from damage to fibers

surrounding the occipital horn of the lateral ventricle.<sup>23</sup> The disconnection hypothesis is most strongly supported by atypical cases, such as a combination of damage to the splenium and a right hemianopia from a lesion of the left lateral geniculate nucleus.<sup>24,25</sup>

However, others argue that some cases of pure alexia may represent an agnosia for visual word forms.<sup>26,27</sup> This ‘word-form agnosia’ may actually be a more generalized perceptual defect for certain complex visual stimuli, of which words and letters are the most prominent examples.<sup>3,8,28,29</sup> Word-form agnosia has been postulated to result from damage to the left fusiform gyrus, which fMRI experiments suggest contains a visual word-form area.<sup>30,31</sup>

Two features not usually considered part of pure alexia further support a hypothesis of impaired word-form processing in JM(Occ). First is his trend to greater difficulty for words with irregular spelling. Typically this is considered a feature of surface dyslexia, attributed to an inability to access semantic information or activate the stored sound of the word,<sup>5</sup> so that reading can only be accomplished through the phonological route. Loss of word-form knowledge thus results in difficulty with irregular words, for which phonological rules of pronunciation are unhelpful. Second, JM(Occ) also demonstrated a similar reliance on phoneme-to-grapheme rules in his writing. This type of agraphia has also been described with some forms of surface dyslexia.<sup>6,15</sup>

In summary, JM(Occ) has trouble identifying letters and the more letters in a word the more difficulty he has identifying the word. His spelling errors as well as his difficulties pronouncing irregular words suggest degraded knowledge of word forms. He employs grapheme-to-phoneme rules to achieve better pronunciation of regular than irregular words and more successful pronunciation of pseudo-words than MP(Par). JM(Occ) similarly relies on phoneme-to-grapheme rules when writing. A perceptual or ‘peripheral’ word-form agnosia with loss of internal representations of letters and word forms would account for the majority of his deficits, and is consistent with a lesion of the left fusiform gyrus.

### *MP(Par): Left angular gyral lesion and central dyslexia*

MP(Par) has preserved perception of letters and better explicit recognition of words, which he demonstrates with equally good matching of words to pictures. He shows no effect of word length on reading. These features suggest that perceptual processing of letters and words is relatively intact. Rather, many aspects of his reading are consistent with deep dyslexia.<sup>5,12</sup> These include better reading of words with high imageability, semantic paralexias, and a severe inability to use phonological rules to read pseudo-words. Although MP(Par)’s reading was best for concrete high-frequency nouns and worst for modifiers, he did not show a statistically significant part-of-speech effect, which is usually another feature of deep dyslexia. This may reflect the severity of his defect with all classes of words or, as others have suggested, an extension of the imageability effect on his reading (i.e. nouns tend to have higher imageability than other words).<sup>5</sup>

The origins of deep dyslexia remain controversial. It may represent either damage to multiple left hemispheric reading modules or the loss of left hemispheric reading skill, with residual reading reflecting the abilities of the right hemisphere.



MP(Par)'s better reading of nouns and words with high imageability and his better access to semantic information (in the form of accurate picture-word matching) are consistent with a hypothesized right hemispheric ability to store semantic but not phonological information.<sup>32,33</sup> Neuroanatomic data for deep dyslexia have been limited because this rare condition is most often associated with large perisylvian lesions and almost always accompanied by a profound aphasia.<sup>9</sup> There are uncommon reports of more focal temporoparietal lesions and clinical syndromes. One case with longstanding resection of a left temporoparietal tumour had 'profound language disturbances' and a hemiplegia that suggests more frontal involvement than described.<sup>34,35</sup> A second patient with a post-traumatic subdural hematoma and left parietal contusion had deep dyslexia and agraphia (whose characteristics were not examined) with a severe anomia as the only other deficit.<sup>36</sup> Another patient with trauma to the left inferior-middle temporal gyrus presented with deep dyslexia, agraphia (again, not characterized) and normal oral comprehension.<sup>37</sup>

MP(Par) had only a mild anomia and his lesion was centered on the angular gyrus, though, as with all tumours, the limits of his lesion are not sharply demarcated. A recent meta-analysis of fMRI studies concluded that the angular gyrus is activated during semantic access and the neighboring posterior superior temporal gyrus during grapheme-to-phoneme conversion.<sup>38</sup> From MP(Par)'s data, we suggest that the classic syndrome of alexia with agraphia is characterized by deep dyslexia and a corresponding deep dysgraphia, and that the angular gyrus may be a key substrate for this linguistic deficit.

#### ***JM(Occ) and MP(Par): agraphic disorders***

Although JM(Occ)'s clinical and radiologic features are consistent with pure alexia, more detailed assessment of his writing showed significant spelling errors consistent with excessive reliance on phoneme-to-grapheme rules. As with his alexia, JM(Occ)'s writing deficits likely reflect loss of information about visual word-forms. This supports claims that the visual word form area also serves as a graphemic-output lexicon (18). Whether these subtler deficits in writing are typical of all cases of so-called pure alexia is unclear. It may be that the presence or absence of surface dysgraphia may distinguish agnostic forms of pure alexia from the disconnection variety, since writing would not be affected by the latter.

Likewise, MP(Par)'s writing mirrors his reading defect. Just as his pseudo-word reading shows a severe inability to use grapheme-to-phoneme conversion rules, his writing errors show no phonological relation to the correct word. While he did not show any semantic substitution errors in writing, this does not imply that he has only phonological agraphia: in that disorder, preserved semantic access to the lexicon allows correct spelling of real words,<sup>18</sup> which he did not show. Thus, his writing demonstrates impaired phoneme-to-grapheme and semantic routes, consistent with a deep dysgraphia mirroring his deep dyslexia.

In summary, our examination of these two patients with different classic syndromes of alexia show that at least some variants of pure (occipital) alexia are likely due to a word-form agnosia that creates parallel deficits in reading and writing. In contrast, alexia with agraphia (angular alexia) is associated with

better perceptual processing of words but more significant linguistic dysfunction, generating parallel deep dyslexia and deep dysgraphia. These data suggest that medial occipital and angular gyral lesions are distinguished not so much by whether writing is intact but by whether both reading and writing show perceptual or linguistic-based deficits.

#### **ACKNOWLEDGEMENTS**

JB was supported by the Canada Research Chair program and a Michael Smith Foundation for Health Research Senior Scholarship. We thank P. Teal and G. Redekop for patient referrals. We dedicate this paper to the memory of MP(Par), whose patience and cooperation were invaluable.

#### **REFERENCES**

1. Black SE, Behrmann M. Localization in Alexia. In: Kertesz A, editor. Localization and neuroimaging in neuropsychology. San Diego: Academic Press; 1994. p. 331-76.
2. Dalmas JF, Dansilio S. Visuographic alexia: a new form of a peripheral acquired dyslexia. *Brain Lang.* 2000;75(1):1-16.
3. Behrmann M, Nelson J, Sekuler EB. Visual complexity in letter-by-letter reading: "pure" alexia is not pure. *Neuropsychologia.* 1998;36(11):1115-32.
4. Goethals M, Santens P. Posterior cortical atrophy. Two case reports and a review of the literature. *Clin Neurol Neurosurg.* 2001; 103(2):115-19.
5. Coslett HB. Acquired dyslexia. *Semin Neurol.* 2000;20(4):419-26.
6. Bub D. Alexia and related reading disorders. *Neurol Clin.* 2003; 21(2):549-68.
7. De Renzi E, di Pellegrino G. Prosopagnosia and alexia without object agnosia. *Cortex.* 1998;34(3):403-15.
8. Buxbaum LJ, Glosser G, Coslett HB. Impaired face and word recognition without object agnosia. *Neuropsychologia.* 1999; 37(1):41-50.
9. Marshall JC, Newcombe F. Patterns of paralexia: a psycholinguistic approach. *J Psycholinguist Res.* 1973;2(3):175-99.
10. Marchand Y, Friedman RB. Impaired oral reading in two atypical dyslexics: a comparison with a computational lexical-analogy model. *Brain Lang.* 2005(3):93:255-66.
11. Coltheart M. The MRC psycholinguistic database. *Q J Exp Psychol.* 1981;33A:497-505.
12. Newton PK, Barry C. Concreteness effects in word production by not word comprehension in deep dyslexia. *Cog Neuropsychol.* 1997;14:481-509.
13. McLeod P, Shallice T, Plaut DC. Attractor dynamics in word recognition: converging evidence from errors by normal subjects, dyslexic patients and a connectionist model. *Cognition.* 2000;74(1):91-114.
14. Colangelo A, Buchanan L. Semantic ambiguity and the failure of inhibition hypothesis as an explanation for reading errors in deep dyslexia. *Brain Cogn.* 2005;57(1):39-42.
15. Beeson PM. Remediation of written language. *Top Stroke Rehabil.* 2004;11(1):37-48.
16. Ogden JA. Phonological dyslexia and phonological dysgraphia following left and right hemispherectomy. *Neuropsychologia.* 1996;34(9):905-18.
17. Cipolotti L, Warrington EK. Does recognizing orally spelled words depend on reading? An investigation into a case of better written than oral spelling. *Neuropsychologia.* 1996;34(5):427-40.
18. Rapsak SZ, Beeson PM. The role of left posterior inferior temporal cortex in spelling. *Neurology.* 2004;62(12):2221-9.
19. Kim HJ, Chu K, Lee KM, Kim DW, Park SH. Phonological agraphia after superior temporal gyrus infarction. *Arch Neurol.* 2002;59(8):1314-16.
20. Mao-Draayer Y, Panitch H. Alexia without agraphia in multiple sclerosis: case report with magnetic resonance imaging localization. *Mult Scler.* 2004;10(6):705-7.



21. Bub DN, Arguin M, Lecours AR. Jules Dejerine and his interpretation of pure alexia. *Brain Lang.* 1993;45(4):531-59.
22. Geschwind N. Disconnexion syndromes in animals and man. I. *Brain.* 1965;88(2):237-94.
23. Damasio AR, Damasio H. Hemianopia, hemiachromatopsia and the mechanisms of alexia. *Cortex.* 1986;22(1):161-9.
24. Stommel EW, Friedman RJ, Reeves AG. Alexia without agraphia associated with spleniogeniculate infarction. *Neurology.* 1991;41(4):587-8.
25. Tamhankar MA, Coslett HB, Fisher MJ, Sutton LN, Liu GT. Alexia without agraphia following biopsy of a left thalamic tumor. *Pediatr Neurol.* 2004;30(2):140-2.
26. Warrington EK, Shallice T. Word-form dyslexia. *Brain.* 1980; 103(1):99-112.
27. Benito-Leon J, Sanchez-Suarez C, Diaz-Guzman J, Martinez-Salio A. Pure alexia could not be a disconnection syndrome. *Neurology.* 1997;49:305-6.
28. Rentschler I, Treutwein B, Landis T. Dissociation of local and global processing in visual agnosia. *Vision Res.* 1994;34(7): 963-71.
29. Miozzo M, Caramazza A. Varieties of pure alexia: the case of failure to access graphemic representations. *Cogn Neuropsychol.* 1998;15(1/2):203-38.
30. Sakurai Y. Varieties of alexia from fusiform, posterior inferior temporal and posterior occipital gyrus lesions. *Behav Neurol.* 2004;15:35-50.
31. Cohen L, Martinaud O, Lemer C, Lehericy S, Samson Y, Obadia M, et al. Visual word recognition in the left and right hemispheres: anatomical and functional correlates of peripheral alexias. *Cereb Cortex.* 2003;13(12):1313-33.
32. Coslett HB, Monsul N. Reading with the right hemisphere: evidence from transcranial magnetic stimulation. *Brain Lang.* 1994;46(2):198-211.
33. Coltheart M. Deep dyslexia is right-hemisphere reading. *Brain Lang.* 2000;71(2):299-309.
34. Colangelo A, Stephenson K, Westbury C, Buchanan L. Word associations in deep dyslexia. *Brain Cogn.* 2003;53(2):166-70.
35. McEwen S, Westbury C, Buchanan L, Libben G. Semantic information is used by a deep dyslexic to parse compounds. *Brain Cogn.* 2001;46(1-2):201-5.
36. Nolan KA, Volpe BT, Burton LA. The continuum of deep/surface dyslexia. *J Psycholinguist Res.* 1997;26(4):413-24.
37. Glosser G, Friedman RB. The continuum of deep/phonological alexia. *Cortex.* 1990;26(3):343-59.
38. Jobard G, Crivello F, Tzourio-Mazoyer N. Evaluation of the dual route theory of reading: a meta-analysis of 35 neuroimaging studies. *Neuroimage.* 2003;20(2):693-712.