

The effect of the hookworm *Ancylostoma ceylanicum* on the mucosal architecture of the small intestine in hamsters

L.M.M. Alkazmi^{1,2}, M.S. Dehlawi^{1,3} and J.M. Behnke^{1*}

¹School of Biology, University of Nottingham, University Park, Nottingham, NG7 2RD, UK: ²Biology Department, Faculty of Applied Sciences, Umm Al-Qura University, Makkah, Saudi Arabia: ³Department of Biological Sciences, King Abdul Aziz University, Jeddah, Saudi Arabia

Abstract

Hookworms are known to cause marked changes to the intestinal mucosa, especially in relation to erosion of the villi. However, since the development of enteropathy has not been examined thoroughly through quantitative experiments on infected animals, the results of experiments conducted in hamsters infected with *Ancylostoma ceylanicum* are reported. Changes to intestinal architecture were first apparent between 12 and 14 days after infection, and then increased in intensity for 3–4 weeks, persisting for as long as worms were present (> 63 days). Following infection, the height of villi declined from a mean of 1002 μm in naïve controls to less than 200 μm and as low as 18 μm in one case. The depth of the crypts of Lieberkuhn increased from a baseline value of 166 μm in naïve controls to in excess of 600 μm within 6 weeks of infection. Mitotic figures had a baseline value of 5.5 per villus-crypt unit, and this rose to in excess of 25 in some experiments. Changes were dependent on the intensity of the parasite burden on day 20, but by 30 days after infection changes in all three values were maximal and density-dependent relationships were no longer clearly apparent. Villus height and crypt depth returned to near normal values within a week of the removal of worms, although group means for both remained different from naïve controls for at least 3 weeks after treatment. Cellular division, as reflected in numbers of mitotic figures, stayed elevated for over 5 weeks after removal of worms. The results suggest that enteropathy in hookworm infections stems from a combination of intestinal immune responses and from the grazing activities of the adult worms on the mucosal surface, but is not sufficient *per se* for expulsion of this parasite.

Introduction

Enteropathy is a common feature of many infectious and non-infectious intestinal conditions. It can include changes to the architecture of the mucosa itself (e.g. changes in the height of the villi and the depth of the crypts of Lieberkuhn), arising from altered rates of cell division, reflected also in numbers of mitotic figures per villus-crypt unit, as well as upregulation of epithelial cell turnover, infiltration of the mucosa by inflammatory cells

such as mast cells and eosinophils and changes in the capacity of the gut to absorb and secrete fluids including various nutrients (e.g. fats and vitamins) (MacDonald *et al.*, 1999; Cliffe *et al.*, 2005). Enteropathy can stem from inappropriate immune responses to food antigens and components of the symbiotic intestinal bacterial flora, through components of the host's response to infection, as well as from the direct activities of the infectious organisms, via damage to the mucosa by released toxins or feeding activities (Castro, 1990; Behnke, 1991; Cooper *et al.*, 1992; Garside *et al.*, 2000; MacDonald *et al.*, 2000; Graham *et al.*, 2004).

There has been a longstanding interest in the enteropathy associated with intestinal nematode

*Author for correspondence
Fax: +44 (0) 115 951 3206
E-mail: jerzy.behnke@nottingham.ac.uk

infections (Symons, 1965, 1976; Ferguson & Jarrett, 1975; Coop *et al.*, 1979), although progress in understanding the underlying mechanisms has accelerated in the last two decades through the use of genetically modified mouse strains. Much of this analytical work has used the mouse–*Trichinella spiralis* model and this has generated hypotheses based on immunologically driven mechanisms of enteropathy, both Th2-mediated (Garside *et al.*, 1992; Lawrence *et al.*, 1998) and, more recently, mediated via innate immunity (McDermott *et al.*, 2005). The key parameters quantified in such studies have been villus height, crypt depth and mucosal cellular division as reflected by mitotic figures.

Analysis of enteropathy in hookworm infections is complicated by the fact that these parasites, unlike the common laboratory models of *T. spiralis*, *Nippostrongylus brasiliensis* and *Trichuris muris*, actually feed on the mucosa, ripping off and internalizing boluses of tissue (Kalkofen, 1970; Loukas *et al.*, 2005). Feeding results in considerable blood loss, both through worm uptake (Wells, 1931; Cheng-Li *et al.*, 1966) and from haemorrhage into the gut lumen, the combination leading to the typical hookworm induced iron-deficiency anaemia (Roche & Layrisse, 1966; Kalkofen, 1970; Pritchard *et al.*, 1991). Studies on humans infected with hookworms, based either on post-mortem samples of the intestine or on biopsy specimens obtained through endoscopy, have shown that the intestinal mucosa can be severely eroded and inflamed, the latter involving mastocytosis and goblet cell hyperplasia (Sheehy *et al.*, 1962), but the relevance of these changes has been a point of considerable controversy (Miller, 1979). Many such studies have lacked truly reliable controls, those that were used being based on samples from patients suffering from other diseases or subjects from impoverished communities where the diet was deficient (Prociv, 1997); hence the observed enteropathy could not easily be causally associated with hookworm infection (Azziz & Siddiqui, 1968; Burman *et al.*, 1970; Behnke, 1991; Kelly *et al.*, 2004).

Experimental work is limited to observations on single (Carroll *et al.*, 1984, 1985) or small numbers of dogs (Migasena *et al.*, 1972). To our knowledge, there have been no well controlled quantitative studies assessing the chronological development of enteropathological changes during hookworm infection (in models where worms develop to the adult stage but see Carroll *et al.*, 1986), their relationship to varying levels of infection, or the effects of subsequent removal of worms by chemotherapy. In the present paper, exploiting the hamster-adapted strain of *A. ceylanicum* (Behnke, 1990), results are reported of five experiments that were conducted to examine the relationship between infection with this hookworm and development of enteropathy.

Materials and methods

Ancylostoma ceylanicum

The strain of *A. ceylanicum* used has been maintained at the University of Nottingham since 1984 and was originally obtained from Dr Rajasekariah of Hindustan CIBA-Geigy Ltd, Bombay, India. It is believed to be of dog origin. The methods employed for maintenance of the parasite, for worm recovery and faecal egg counts have all

been described previously in full (Garside & Behnke, 1989; Behnke *et al.*, 1997).

Hamsters

Golden hamsters (DSN strain) were originally obtained from Harlan Olac in 1983 and since then have been maintained in the animal house of the School of Biology as a closed colony. Animals were kept under conventional animal house conditions. Pelleted food and tap water were supplied *ad libitum*. Cages were cleaned twice weekly to prevent reinfection. Animals were first weighed one or two weeks before infection and thereafter twice weekly until the completion of each experiment.

Since the colony was maintained under conventional animal house conditions, the animals were exposed to various microorganisms present in the environment. In order to prepare hamsters for infection and reduce other competing intestinal microorganisms, all animals allocated to experiments were pre-treated for one week with Emtryl (May & Baker, dimetridazole at a concentration of 1 g l^{-1} in drinking water), then for another week with Terramycin (Pfizer, oxytetracycline hydrochloride, 3 g l^{-1} in drinking water), and were returned to normal drinking water for one week prior to infection.

Worms were removed from infected animals (experiment 5) by treatment with ivermectin (Ivomec super' MSD AGVET, Division of Merk Sharp and Dohme Limited, Holland). A stock concentration of $200\text{ }\mu\text{g ml}^{-1}$ drug was made by a 1 in 50 dilution using distilled water and this was used to treat at $200\text{ }\mu\text{g kg}^{-1}$ body weight.

Quantification of changes to gut architecture

At autopsy, pieces of tissue were taken from the intestine (each about 1 cm square) approximately 10 cm below the pyloric sphincter, and fixed in Clark's fixative (75% ethanol and 25% glacial acetic acid V/V). Samples were placed in 50% ethanol for 10 min, transferred into tap water for another 10 min, and then placed in preheated 1N HCl at 60°C for 7.5 min. They were then transferred to tap water for 10 min. Samples were washed three times in tap water and then placed in 2 ml of Schiffs reagent for 20–30 min. Stained samples were washed in tap water to remove excess stain. The muscularis layers were gently removed with fine forceps and the section was cut to provide lines of villi and crypts using a cataract knife before being placed onto microscope slides with a drop of 45% acetic acid and gently covered with a cover slip. The samples were then viewed under a microscope fitted with a calibrated eyepiece graticule and the lines of 20 randomly chosen villi and crypts were measured. The slides were then gently compressed until the crypts had disrupted and mitotic figures were counted under high power ($\times 40$).

Experimental design

The effect of infection with Ancylostoma ceylanicum on mucosal architecture

Two experiments were carried out in which villus height, crypt depth and the number of mitotic figures per villus-crypt unit were monitored at different times during

infection. In experiment 1, 26 hamsters and in experiment 2, 30 hamsters were infected with 100 third stage larvae (L3). Additionally, 14 and 15 hamsters, respectively, were left uninfected as the control groups. Infected hamsters were killed in groups of 3–5 at weekly intervals from day 7 to day 42 post-infection (pi). Control groups of 4–5 were killed on the first day of the experiment (day 0, when the infection was given to the experimental group), day 14 and day 42.

*The effect of varying the worm burden with *Ancylostoma ceylanicum* on mucosal architecture*

Two experiments were carried out in which the dose of administered larvae was varied in order to ascertain whether the changes in mucosal architecture were dependent on the number of worms present. In experiment 3, 50 hamsters were used, 10 of which were left uninfected, and the remaining 40 were infected with doses ranging from 50 L3 ($n = 10$), 100 L3 (10), 150 L3 (5), 200 L3 (5) to 250 L3 (5). On day 12 after infection 5 hamsters from each group were killed for assessment of worm burdens and intestinal architecture. The remaining animals (5 controls, 5 each infected with 50 and 100 L3) were killed 18 days later on day 30 pi. The infections in animals destined for autopsy on day 30 were restricted to 100 and below to limit possible mortality. Experiment 4 comprised 30 hamsters, 5 uninfected naïve control animals and 5 each infected with 30, 60, 100, 150 and 200 L3. All the animals were killed for worm counts and assessment of intestinal architecture on day 20 pi.

*The effect of removing adult *Ancylostoma ceylanicum* on day 28 after infection on mucosal architecture*

Experiment 5 comprised 60 female hamsters in total. Fifteen (group 1) were not infected or treated and provided naïve control data on days 28, 49 and 63 of the experiment. Twenty five animals (group 2) were infected with 50 L3 and were autopsied on days 28, 35, 42, 49 and 63 pi. The final group (group 3) comprised 20 animals infected as in group 2, but given a single oral dose of ivermectin on day 28 pi and autopsied on days 35, 42, 49 and 63 pi.

Statistical analysis

The frequency distributions of data were tested for goodness of fit to negative binomial, positive binomial and Poisson models by χ^2 as described by Elliott (1977), using bespoke software. Analysis was then by one-way or two-way ANOVA in GLIM (SPSS version 9.0.0) with or without relevant co-variables (e.g. days after infection to assess changes with time and control for time effects when estimating significance of other factors). Each model was assessed for goodness of fit by R^2 , and the residuals were checked for approximately normal distribution. If data did not conform to the assumptions of parametric analyses, transformation was used to normalize the distribution (e.g. $\log_{10}(x + 10)$) and where a satisfactory transformation could not be achieved the effect of treatment was analysed by the non-parametric Mann-Whitney U test (for two group comparison) and the Kruskal-Wallis one-way ANOVA if

more than two groups were compared. The final statistical models fitted to the data are explained more comprehensively in the results section.

Results

Range of values observed in uninfected hamsters

As there is very little information available in the literature on the range of normal values for villus height, crypt depth and number of mitoses in hamsters, and in our DSN strain in particular, data were pooled from a range of experiments. Forty eight of these values were from hamsters that contributed to the experiments reported later in this paper, and 25 were from other experiments.

Mean villus height (10 cm from the pyloric sphincter) was $1002.4 \pm 9.66 \mu\text{m}$. However, the variance was relatively high (61 818.8) and the distribution did not conform to a normal distribution, but rather to a negative binomial (see legend to fig. 1 for analysis). The distribution showed a negative skew, arising from the five hamsters that had values of less than $850 \mu\text{m}$ and fewer than expected in the class range 951–1000 μm .

Mean crypt depth was $166.6 \pm 3.56 \mu\text{m}$ with a variance of 924.7, but assessment by the Chi-squared test showed that the distribution was not significantly different from the normal distribution, even though some categories exceeded expected counts, particularly among the deeper crypts. The frequency distribution was equally well described by the negative binomial distribution.

The mean number of mitotic figures per villus-crypt unit was 5.5 ± 0.22 , with a variance of 3.5, and the frequency distribution was well described by the normal distribution, although it was not significantly different from the negative binomial.

*Temporal changes in mucosal architecture during infection with *Ancylostoma ceylanicum* (experiments 1 and 2)*

Worm burdens

The worm burdens recovered at autopsy from the infected animals are illustrated in fig. 2. This shows that in experiment 1 more worms established compared with experiment 2 (one-way ANOVA in GLIM with experiment as a fixed factor and days as covariate on $\log_{10}(\text{worm burden} + 10)$ transformed data, for main effect of experiment $F_{1,52} = 42.7$, $P < 0.001$), and in experiment 1 worm burdens declined with time to an average of 15.3 ± 6.5 by day 42 post-infection (see legend of fig. 2 for statistical analysis), representing a 61% reduction in worm burden. In contrast in experiment 2, where initial establishment (as adjudged by day 7 worm counts) was much lower, there was no significant loss of worms with time, indicating stable worm burdens, despite the variation in means between successive weeks.

Effect of infection on the height of small intestinal villi

In both experiments there was a marked difference in villus height between infected and naïve animals (fig. 3 and legend). On the day of infection, in experiment 1, villus height was lower than expected (mean of

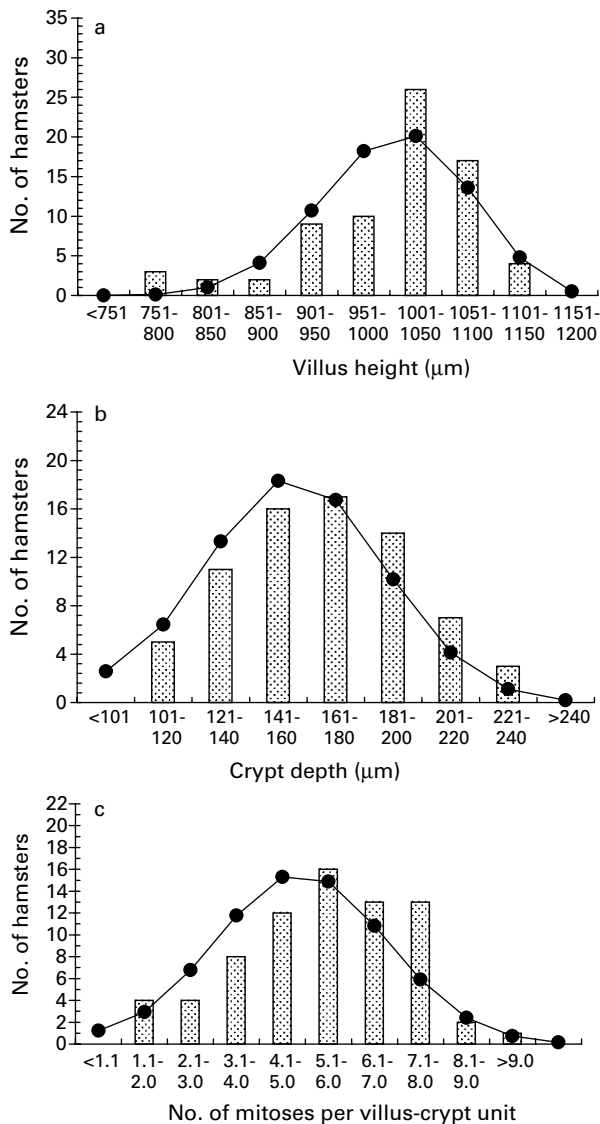


Fig. 1. Frequency distributions for the height of villi (a), depth of crypts (b) and number of mitoses per villus-crypt unit (c) from uninfected, naïve hamsters. The data-set is based on 73 hamsters pooled from a number of experiments to show the range of values that were obtained with naïve hamsters from our colony. These values therefore form the baselines for these parameters against which changes in infected animals were assessed. Columns show the number of hamsters in each class range and the line graph the best-fit expected distribution for each data-set. a. The frequency distribution for villus height did not conform to a normal distribution ($\chi^2_4 = 19.5$, $P = 0.001$), but the best fit was to the negative binomial ($\chi^2_5 = 7.5$, $P = 0.19$). The illustrated expected distribution is for that of the negative binomial. b. The distribution of crypt depths was not significantly different from the normal distribution ($\chi^2_5 = 7.7$, $P = 0.17$; the illustrated expected distribution), but was also not significantly different from the binomial, Poisson and negative binomial distributions (in all cases $P > 0.6$). c. The distribution of number of mitoses per villus-crypt unit was not significantly different from the normal distribution ($\chi^2_5 = 8.2$, $P = 0.14$; the illustrated expected distribution), but was also not significantly different from the binomial, Poisson and negative binomial distributions (in all cases $P > 0.12$).

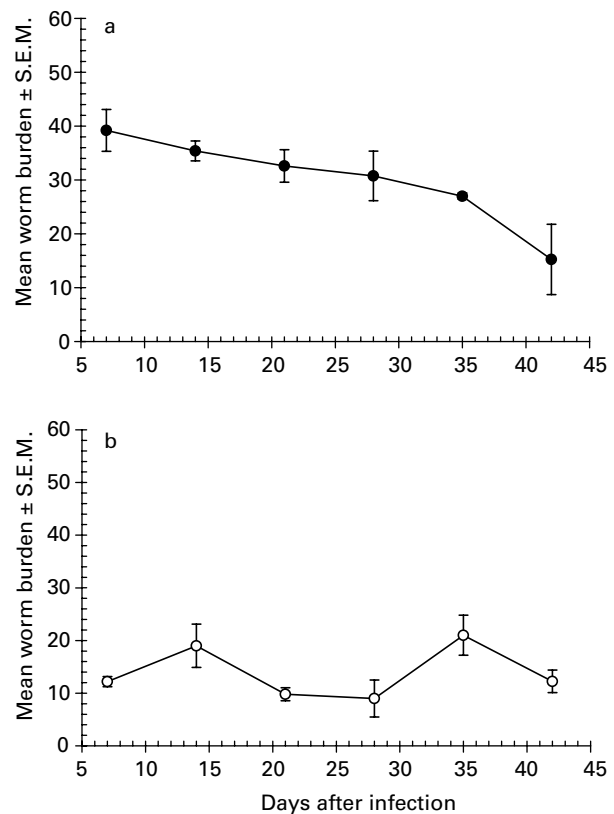


Fig. 2. Worm burdens of hamsters at weekly intervals after infection with 100 L3 of *Ancylostoma ceylanicum* in experiments 1 (a) and 2 (b). a. Regression of \log_{10} (worm burden + 10) on days gives $F_{1,24} = 20.35$, $\beta = -0.00785$, $P < 0.001$, adjusted $R^2 = 43.6\%$. b. Regression of \log_{10} (worm burden + 10) on days gives $F_{1,27} = 0.02$, $P = \text{NS}$, adjusted $R^2 = -0.04\%$.

$772.6 \pm 46.7 \mu\text{m}$ compared with background mean in naïve animals of $1002.4 \pm 9.66 \mu\text{m}$ (fig. 1), perhaps suggesting a mild contaminating intestinal infection, but the values for naïve hamsters on days 14 and 42 were well within the normal range and very similar. In experiment 2, the mean values ranged from 1060 to $1093.5 \mu\text{m}$, well within the normal range, but there was a slight but significant upward drift with time (regression of villus height on time after infection, in naïve animals only, $\beta = 0.80 \pm 0.36$, $t = 2.24$, $P = 0.043$, adjusted $R^2 = 22.3\%$), representing an increase in villus height of 3.4%.

In contrast, in both experiments the height of villi in infected animals declined sharply after a week of infection (fig. 3a). In experiment 1, villus height fell by 42% by day 14, and then continued to decline with the lowest values being recorded on day 28 (regression of villus height on time after infection, in infected animals only, $\beta = -13.0 \pm 2.15$, $t = -6.053$, $P < 0.001$, adjusted $R^2 = 62.9\%$). On the final day of the experiment villi were 59.7% shorter in infected animals compared with naïve controls on the same day. In experiment 2, villus height was 49.16% lower compared with infected animals on day 14 and 82.9% lower on day 42. Again villus height fell

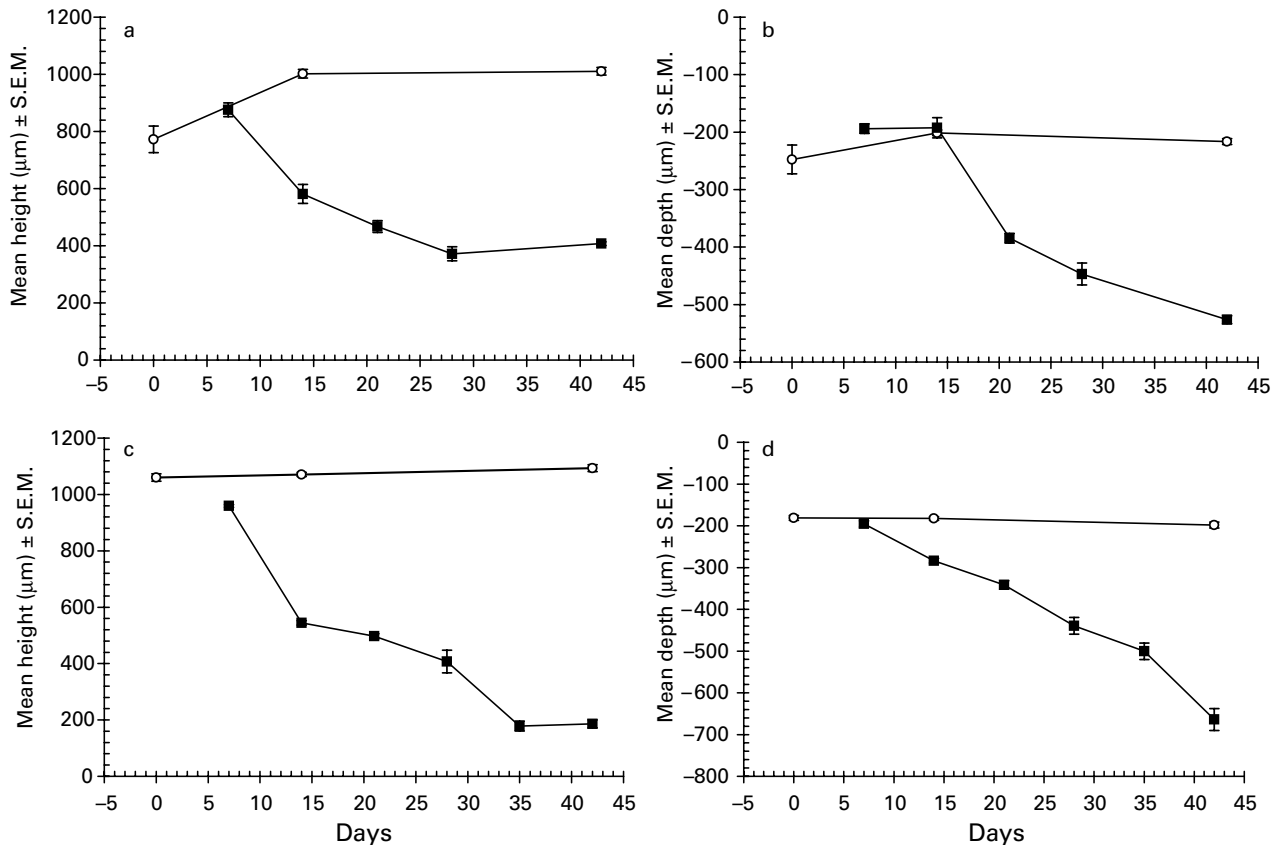


Fig. 3. Effect of infection with *Ancylostoma ceylanicum* on the height of villi (a and c) and the depth of crypts of Lieberkuhn (b and d) in experiments 1 (a and b) and 2 (c and d). Note that although naïve control groups were actually killed on day 0, the day of infection, for the purpose of statistical analysis they were fitted as day 7 to correspond with the day on which the first infected group of animals was killed. ○, Naïve animals; ■, infected animals. a. Experiment 1. Two-way ANOVA in GLIM with time after infection and treatment (infected or not infected) as fixed factors on villus height, for main effect of treatment $F_{1,27} = 183.1$, $P < 0.001$; for main effect of time $F_{1,27} = 22.3$, $P < 0.001$; for the two-way interaction between time and treatment $F_{2,27} = 93.2$, $P < 0.001$. Adjusted model $R^2 = 94.7\%$. b. Experiment 1. Two-way ANOVA in GLIM with time after infection and treatment (infected or not infected) as fixed factors on crypt depth, for main effect of treatment $F_{1,27} = 48.5$, $P < 0.001$; for main effect of time $F_{4,27} = 61.1$, $P < 0.001$; for the two-way interaction between time and treatment $F_{2,27} = 91.7$, $P < 0.001$. Adjusted model $R^2 = 94.3\%$. c. Experiment 2. Two-way ANOVA in GLIM as in a, for main effect of treatment $F_{1,36} = 1317.5$, $P < 0.001$; for main effect of time $F_{5,36} = 170.0$, $P < 0.001$; for the two-way interaction between time and treatment $F_{2,36} = 273.4$, $P < 0.001$. Adjusted model $R^2 = 98.9\%$. d. Experiment 2. Two-way ANOVA in GLIM as in c but on \log_{10} (crypt height) transformed dependent variable, for main effect of treatment $F_{1,36} = 404.7$, $P < 0.001$; for main effect of time $F_{5,36} = 100.1$, $P < 0.001$; for the two-way interaction between time and treatment $F_{2,36} = 136.3$, $P < 0.001$. Adjusted model $R^2 = 97.2\%$.

consistently with time (regression of villus height on time after infection, in infected animals only, $\beta = -20.6 \pm 1.57$, $t = -13.12$, $P < 0.001$, adjusted $R^2 = 86\%$).

Effect of infection on the depth of the crypts of Lieberkuhn

In both experiments there was a marked time-dependent increase in crypt depth in infected compared with naïve animal (fig. 3b,d). The crypts of naïve animals in experiment 1 were longer than the normal range (fig. 1) with means on days 0, 14 and 42 being 48.6%, 20.8% and 29.8%, greater than the mean value of 166.6 µm recorded for naïve animals. In experiment 2 the mean values of 181, 182.5 and 198 µm, on days 0, 14 and 42 were within the normal range but depth increased significantly, albeit

marginally, with time (regression of \log_{10} (crypt depth) on time after infection, in naïve animals only, $\beta = -0.00097 \pm 0.0001$, $t = 2.30$, $P = 0.039$, adjusted $R^2 = 23.4\%$).

However, it is very clear that crypt depth increased markedly following infection in both experiments, the means diverging significantly between the two groups (the two-way interactions in fig. 3b and d legend) and falling continuously throughout the experiment (regression of crypt depth on time after infection, in infected animals only, experiment 1 $\beta = -10.534 \pm 0.91$, $t = 11.5$, $P < 0.001$, adjusted $R^2 = 86.3\%$ and experiment 2 (\log_{10} (crypt depth) transformed dependent variable) $\beta = -0.014 \pm 0.001$, $t = 23.0$, $P < 0.001$, adjusted $R^2 = 94.8\%$).

Effect of infection on the mitotic number

In both experiments there was a marked change in the number of mitoses observed in villus-crypt units after infection (fig. 4), but there were also changes in the naïve hamsters that complicated interpretation. All the mean values in naïve animals were well within the normal range (fig. 1, 1–9 mitoses per villus-crypt unit), but in experiment 1 there was a consistent fall in mitoses with time (regression of mitotic figures on time after infection, in naïve animals only, $\beta = -0.092 \pm 0.27$, $t = -3.39$, $P = 0.006$, adjusted $R^2 = 46.6\%$). No significant change with time was evident in experiment 2, in which the means were higher, relative to experiment 1, on all three days.

For technical reasons it was not possible to measure mitoses in infected hamsters in experiment 1 on days 35 and 42, but the marked rise in mean counts earlier in infection is clearly evident in fig. 4a, as is the significant

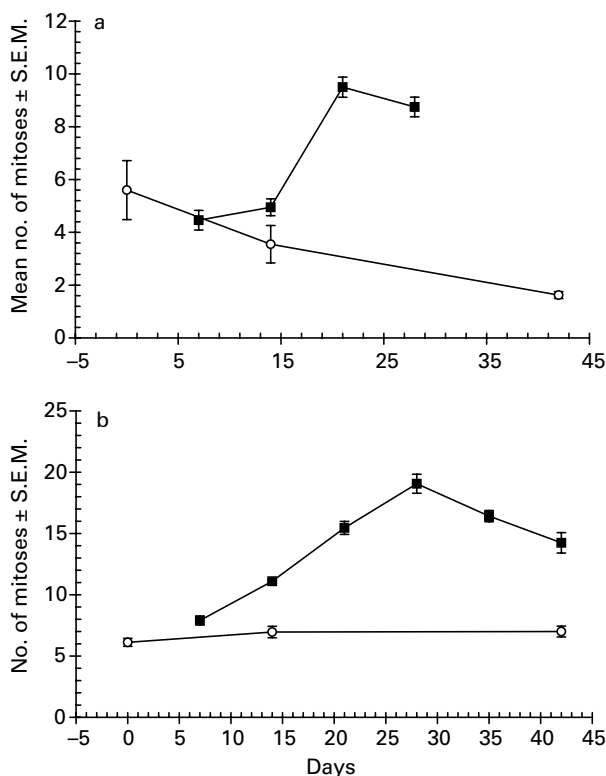


Fig. 4. Effect of infection with *Ancylostoma ceylanicum* on the number of mitotic figures per villus-crypt unit in the small intestine in experiments 1 and 2. ○, Naïve animals; ■, infected animals. a. Experiment 1. Two-way ANOVA in GLIM with time after infection and treatment (infected or not infected) as fixed factors on number of mitoses, for main effect of treatment $F_{1,24} = 0.45$, $P = \text{NS}$; for main effect of time $F_{4,24} = 17.6$, $P < 0.001$; for the two-way interaction between time and treatment $F_{1,24} = 4.34$, $P = 0.0481$. Adjusted model $R^2 = 79.7\%$. b. Experiment 2. Two-way ANOVA in GLIM as for part a. For main effect of treatment $F_{1,36} = 106.3$, $P < 0.001$; for main effect of time $F_{5,36} = 53.2$, $P < 0.001$; for the two-way interaction between time and treatment $F_{2,36} = 13.8$, $P < 0.001$. Adjusted model $R^2 = 93.9\%$.

divergence between infected and naïve animals with time (the two-way interaction in legend to fig. 4a). However, even at the height of the response on day 21 the mean value was only just outside the normal range (fig. 1). In contrast, the response peaked on day 28 in experiment 2 at a mean count of 19, more than twice the maximum value in the normal range and 2.8 times higher than the average for the naïve controls in this experiment.

The effect of varying the worm burden on mucosal architecture

Using data from experiments 3 and 4, analyses of the relationship between the measured parameters and worm burdens were conducted 12 (experiment 3), 20 (experiment 4) and 30 (experiment 3) days after infection. Twelve days after infection worm burdens ranged from 6 to 112 worms, 20 days pi the range was 3 to 35 worms and 30 days pi was 8 to 36. Thus on each of the three days a range of parasite burdens was established and dose-dependent changes in architecture should have been apparent.

On day 12 after infection, there was no evident directional quantitative relationship between worm burdens and any of the three parameters measured (r_s ranged from -0.05 to 0.24 , $n = 30$, $P = \text{NS}$). In control hamsters the mean villus height was $641.5 \pm 65.0 \mu\text{m}$, lower than expected for the normal range, but values in hookworm-infected hamsters were higher at $877.7 \pm 34.2 \mu\text{m}$ and this difference was significant (naïve vs. infected, Mann-Whitney U-test, $U = 16$, $n = 30$, $z = -2.59$, $P = 0.01$). Crypt depth in uninfected hamsters was $158.5 \pm 10.8 \text{ mm}$, which is well within the normal range, and the mean value was slightly higher in the infected animals ($178.0 \pm 4.8 \mu\text{m}$) but there was no significant difference between the two groups (naïve vs. infected, Mann-Whitney U-test, $U = 33$, $n = 30$, $z = -1.64$, $P = \text{NS}$). The number of mitoses in naïve animals was 9.31 ± 0.48 per villus-crypt unit, and slightly higher at 10.9 ± 0.5 in infected animals. The former was just outside the normal range, but there was no significant difference between the groups (naïve vs. infected, Mann-Whitney U-test, $U = 33$, $n = 30$, $z = -1.64$, $P = \text{NS}$).

On days 20 and 30 all three relationships were highly significant, with negative relationships between worm burden and villus height on both days and positive relationships for worm burden and crypt depth, and number of mitoses (fig. 5, and see legend for statistical analysis). It can be seen from these data, that on day 20 the dose-dependent nature of the relationships was apparent at low parasite burdens (< 10 worms), but then a ceiling effect was observed with little further change (villus height and mitoses), although crypt depth continued to increase (fig. 5b). However, by day 30 the significant correlations were almost entirely attributable to the firm root provided by the control group, and among the infected animals no dose-dependent relationship, as such, was evident.

The effect of removing *Ancylostoma ceylanicum* on mucosal architecture

All the hamsters in groups 2 and 3 became infected as adjudged by worm counts for group 2 (mean worm

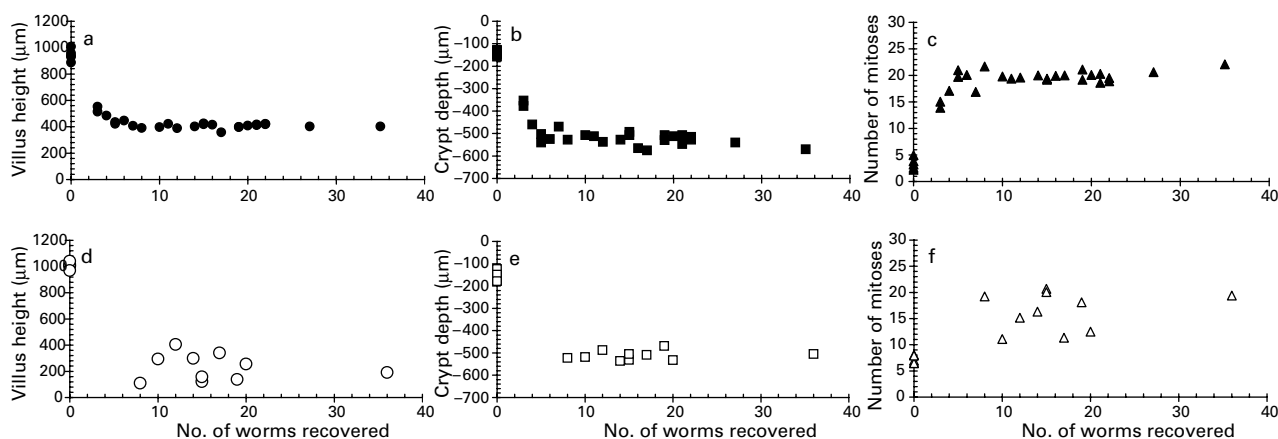


Fig. 5. The effect on villus height (a and d, circles), crypt depth (b and e, squares) and number of mitotic figures/villus-crypt unit (c and f, triangles) on days 20 (a–c, filled in symbols) and 30 (d–f, open symbols) after infection with varying parasite burdens. Each symbol represents a value from an individual hamster. a. $R_s = -0.68$, $n = 30$, $P < 0.001$; b. $R_s = 0.74$, $n = 30$, $P < 0.001$; c. $R_s = 0.62$, $n = 30$, $P < 0.001$; d. $R_s = -0.69$, $n = 15$, $P = 0.005$; e. $R_s = 0.63$, $n = 15$, $P = 0.012$; f. $R_s = 0.73$, $n = 15$, $P = 0.002$.

recoveries on days 28, 35, 42, 49 and 63 after infection were 10.0 ± 2.1 , 19.4 ± 4.5 , 14.8 ± 4.1 , 9.2 ± 1.5 , and 8.4 ± 1.0 , respectively; there was no significant difference in worm burdens between these times, Kruskal-Wallis test $\chi^2_4 = 8.2$, $P = 0.09$ and faecal egg counts on days 22 and 23 after infection in group 3. The faecal egg counts of hamsters in group 3 varied in the range 2000 to 5000 eggs per gram of faeces on days 22 and 23, but were completely negative on days 31 and 32 (3 and 4 days after administration of ivermectin). Furthermore, no worms were recovered at autopsy from any of these animals.

The data illustrated in fig. 6 show that the control and infected but not treated groups behaved much as in earlier experiments, infection being associated with a dramatic decline in villus height (fig. 6a), increase in crypt depth (fig. 6b) and an increase in the mitotic activity (fig. 6c). As in previous experiments, these changes were already clearly evident on day 28 after infection when group 3 was treated with anthelmintic. Figure 6b shows that crypt depth recovered almost completely within a week of treatment, villus height took somewhat longer with means in the infected-treated group 3 lower than those of naïve controls (group 1) until the end of the experiment. Similarly, mitotic activity stayed elevated after treatment until the end of the experiment on day 63, albeit considerably lower than in the animals that continued to harbour worms (group 2).

Discussion

The experiments reported in the present paper have demonstrated clearly the marked changes that occur in the intestines of hamsters infected with the hookworm *Ancylostoma ceylanicum*. Changes were detected at the levels of cellular proliferation and in the marked alteration of the mucosal architecture in the anterior small intestine. These changes were dependent on the presence of worms, the number of worms present (density-dependent) and the duration of the infection.

To the best of our knowledge these are the first quantitative and time course data describing changes in mucosal architecture during hookworm infections.

There was little significant change in villus and crypt measurements during the early phase of infection, up to 7 days pi (experiments 1 and 2) when the worms are growing as third and fourth stage larvae; even by 12 days pi (experiment 3) there was no indication that either parameter differed significantly from values in naïve controls. In hamsters, *A. ceylanicum* moults to the preadult stage 6–11 days pi (Ray *et al.*, 1972; Garside & Behnke, 1989) and it is only after this time that blood loss is evident in a decline in haematocrit (Garside & Behnke, 1989) and haemoglobin levels (Bungiro *et al.*, 2001). The present experiments showed that soon after the L4/preadult moult villus height fell rapidly and crypt depth increased. Villus atrophy was particularly marked, with a reduction from a baseline value of $1002 \mu\text{m}$ to often less than $200 \mu\text{m}$, and in some cases almost complete loss of villi. For example in experiment 5 villus length declined to a mean of just $14 \mu\text{m}$ on day 63 in animals that harboured a mean of 8.4 worms, and yet the impressive resilience of hamsters to infection was clearly evident in an absence of any significant weight loss. Seven days before infection the group mean weight was $134.6 \pm 5.6 \text{ g}$ and on day 63 pi, $138.3 \pm 4.9 \text{ g}$, an increase of 3.7 g compared to an increase of 6.5 g by naïve controls in the corresponding period.

The changes in mucosal architecture were not only related to time after infection, but also to the intensity of infection. We carried out three dose-response experiments and in each established a wide range of worm burdens. There was no evidence of any change in parameters 12 pi, and by day 30 pi, the only differences observed were between infected and uninfected animals. Among the infected animals, there was no convincing correlation with increasing worm burdens. This presumably reflects a ceiling effect, and although all three parameters showed some variation in infected animals, and between experiments including some extreme values

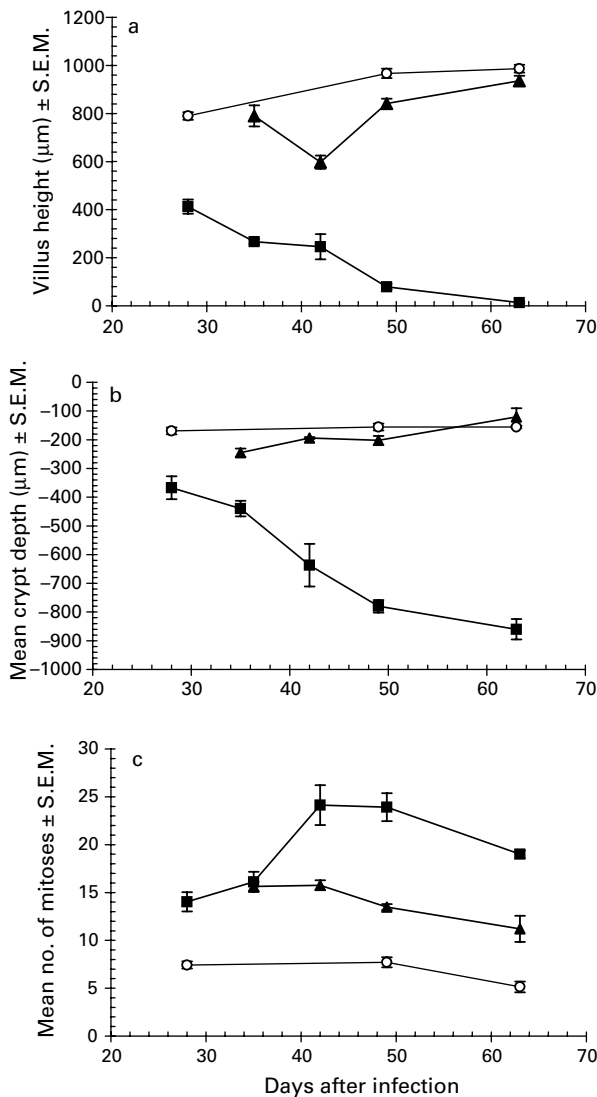


Fig. 6. The effect of removing *Ancylostoma ceylanicum*, by treatment with anthelmintic, on mucosal architecture. ○, Naïve uninfected hamsters; ■, infected hamsters; ▲, hamsters that were infected and then treated with anthelmintic 28 days after infection in order to remove the worms. a. Effect on villus height two-way ANOVA in GLM with time after infection and treatment (not infected, infected not treated and infected treated) as fixed factors on villus height, for main effect of treatment $F_{2,48} = 838.3$, $P < 0.001$; for main effect of time $F_{4,48} = 6.8$, $P < 0.001$; for the two-way interaction between time and treatment $F_{5,48} = 48.0$, $P < 0.001$. Adjusted model $R^2 = 97.2\%$. b. Effect on crypt depth. Statistical model as in part a, with crypt depth as the dependent variable, for main effect of treatment $F_{2,48} = 317.7$, $P < 0.001$; for main effect of time $F_{4,48} = 15.4$, $P < 0.001$; for the two-way interaction between time and treatment $F_{5,48} = 27.8$, $P < 0.001$. Adjusted model $R^2 = 93.1\%$. c. Effect on mitoses per villus-crypt unit. Statistical model as in part a, with number of mitoses per villus-crypt unit as the dependent variable, for main effect of treatment $F_{2,48} = 121.1$, $P < 0.001$; for main effect of time $F_{4,48} = 13.4$, $P < 0.001$; for the two-way interaction between time and treatment $F_{5,48} = 9.4$, $P < 0.001$. Adjusted model $R^2 = 86.9\%$.

(villus height on day 63 pi in experiment 5), at the treatment group level these probably reflect the maximum possible change. The most convincing evidence for a dose-related effect on mucosal architecture was observed in experiment 4, when animals were culled on day 20 pi. Quite clearly here, villus length had not yet fallen to its maximum (below 200 µm), crypt hyperplasia and mitoses per villus-crypt unit had not increased to their respective maxima. Among the lower worm burdens, i.e. 10 and fewer worms, a dose response was evident (fig. 5).

Our data also show that recovery from infection is very rapid indeed and this accords with the general observations both that the intestine has immense reserve, capacity for renewal and recovers rapidly from insult (Ido *et al.*, 2005; Radtke & Clevers, 2005), and that local intestinal pathology at the site of attachment disappears rapidly after the worms have moved on to new feeding sites in the intestine (Burman *et al.*, 1970; Kalkofen, 1974). Hookworms create lesions, ulcer-like patches, at their sites of attachment which heal within 6–24 h (Kalkofen, 1970, 1974; Prociw, 1997) and it is possible that some of the tissue samples taken for measurement of mucosal architecture contained very recent attachment sites. However, the worm burdens were relatively low and adults of this species are distributed throughout the anterior half of the small intestine of hamsters (Rajasekariah *et al.*, 1985) rather than aggregating specifically 10 cm from the pylorus in the sections taken for measurements, and although this may be one explanation of the extreme values for villus height in some animals, the likelihood that worms had recently fed in all the hamsters in the sections taken for analysis is minimal. Hence, we do not consider this to be a significant complication in interpreting our data and, moreover, the overall consistency of the changes that we recorded argues against such an explanation. In our experiments, a marked improvement, as reflected in a return to values characteristic of uninfected animals was observed by 7 days after treatment. Both villus and crypt values were within the control range throughout the following 4 weeks of infection despite the group means being generally lower than those of the control group. Interestingly, the number of mitotic bodies per villus-crypt units remained elevated and well above controls, on day 63 pi, 5 weeks after the worms had been removed.

The majority of hookworms feed on the intestinal mucosa, changing feeding sites at 4–6 h intervals (Kalkofen, 1970), although some species penetrate well into the submucosa (Bonne, 1942; Verma *et al.*, 1968; Kalkofen, 1974; Loukas *et al.*, 2005). Since there is little evidence of anaemia earlier than day 7 pi and no villous atrophy or crypt hyperplasia before day 12 pi (Garside & Behnke, 1989; Menon & Bhopale, 1985), deep grazing on the mucosa with associated blood loss is probably only associated with the pre-adult and adult stages of *A. ceylanicum*. Therefore, the slow decline of villus height is consistent with the onset of grazing on the mucosal surface by adult worms.

Nevertheless, villous atrophy, crypt hyperplasia and an increase in mitotic activity are all well known to be associated with intestinal immune responses to gastrointestinal nematode infections (Garside *et al.*, 2000). Two

mechanisms, perhaps not entirely mutually exclusive, have been proposed to explain the generation of enteropathy in mice infected with *T. spiralis*. Some authors believe that enteropathy is Th2 dependent, mediated by nitric oxide (Lawrence *et al.*, 2000), whose synthesis is upregulated by TNF probably released from mast cells, and by IL-4 (Lawrence *et al.*, 1998). More recently McDermott *et al.* (2005) concluded that enteropathy in *T. spiralis* infection was mediated by IL-13 derived from NK cells and was not T-cell dependent and hence was a function of the non-adaptive, innate immune response. In hookworm infections villous atrophy may be partially explained also by the grazing activities of the adult worms. Whilst changes in crypt depth and mitotic activity are unlikely to be a direct consequence of worm feeding, they could reflect a homeostatic up-regulation of mucosal turnover to compensate for tissues lost to the worms or, as in other intestinal infections, a Th2 mediated mucosal response to infection with worms. As shown by Garside *et al.* (1990) and Alkazmi (2004), primary infections in hamsters are associated with mastocytosis and goblet cell hyperplasia, suggesting a Th2 driven mucosal response to the worms.

Another aspect of these results that is worth commenting on concerns the relationships between the extent of the enteropathy and changes of worm burdens over time, and in relation to the number of worms present. In experiment 1 in the present study, where relatively high worm burdens were initially established, there was a continued downward drift in parasite numbers from week 1 onwards (61% loss of worms between days 7 and 42 pi), whereas in experiments 2 and 5, where fewer worms established initially, there was no evidence of worm loss. Given this difference in worm burdens and kinetics of infection, it is interesting to note that in experiment 1, where worm burdens were greater and loss of worms did take place, villus height did not fall as low as in experiments 2 and 5, where, despite fewer worms, villus height continued to be eroded until weeks 5 (experiment 2) and 9 (experiment 5). Similarly, in experiment 1 crypt depth was shallower in week 6 compared with experiments 2 and 5. These observations suggest that where protective mechanisms are elicited and worm loss is initiated, mucosal damage may be limited, which in turn implies that worm feeding, rather than host response, may be a major contributor to the enteropathy. However, the dose response data argue against the idea that villus height is primarily attributable to worm feeding (fig. 5). On day 20 for example, when the worms were adult and the infection was several days into patency, despite an overall negative relationship between worm burden and villus height, when the uninfected animals were excluded from consideration the relationship became very weak. In fact, in the range 5–35 worms, villus height was very similar. We might have expected 35 feeding worms to abrade the intestinal mucosa to a considerably greater degree than just 5.

Perhaps the most impressive aspect of the present data is the duration over which the enteropathy was sustained without any obvious weight loss by hamsters, or loss of worms (experiment 2). In contrast to the mouse–*T. spiralis* model, where enteropathy is rapidly ameliorated after the worms have been expelled in weeks 2 and 3 (Lawrence

et al., 1998), here almost complete loss of villi was still evident on day 63 pi (fig. 6) when worms were present. Hookworm infections in hamsters therefore provide a useful model for studying chronic enteropathy in the small intestine, with possible relevance to diseases such as coeliac and Crohn's disease in which enteropathy can be a lifelong condition (MacDonald & Montelone, 2005). It is most likely that the changes that we observed were a consequence of a largely ineffective immune response against the worms, enhanced in the case of villous atrophy by the grazing activities of the worms themselves. The exact contributions of innate and adaptive immune responses and worm feeding activities to this phenomenon remain to be elucidated.

Acknowledgements

The authors thank the Ministry of High Education of the Kingdom of Saudi Arabia for the provision of a postgraduate studentship for LMMA and for travel funds for MSD. The authors are also grateful to Dr Catherine Lawrence and Prof. P. Garside for training provided for LMMA in the initial stages of this project and for their comments on the manuscript, and to Prof. D. Wakelin for his advice on earlier drafts of the manuscript.

References

- Alkazmi, L.M.M. (2004) Mucosal immunity to the hookworm *Ancylostoma ceylanicum*, PhD thesis, University of Nottingham.
- Aziz, M.A. & Siddiqui, A.R. (1968) Morphological and absorption studies of small intestine in hookworm disease (ancylostomiasis) in West Pakistan. *Gastroenterology* **55**, 242–250.
- Behnke, J.M. (1990) Laboratory animal models. pp. 105–128 in Schad, G.A. & Warren, K.S. (Eds) *Hookworm disease. Current status and new directions*. London, Taylor and Francis.
- Behnke, J.M. (1991) Pathology. pp. 51–91 in Gilles, H.M. & Ball, P.A.J. (Eds) *Human parasitic diseases, Volume 4, hookworm infections*. Amsterdam, Elsevier.
- Behnke, J.M., Guest, J. & Rose, R. (1997) Expression of acquired immunity to the hookworm *Ancylostoma ceylanicum* in hamsters. *Parasite Immunology* **19**, 309–318.
- Bonne, C. (1942) Invasion of the wall of the human intestine by ancylostomes. *American Journal of Medicine* **22**, 507–509.
- Bungiro, R.D., Greene, J. Jr, Kruglov, E. & Capello, M. (2001) Mitigation of hookworm disease by immunization with soluble extracts of *Ancylostoma ceylanicum*. *Journal of Infectious Diseases* **183**, 1380–1387.
- Burman, N.N., Sehgal, A.K., Chakravarti, R.N., Sodhi, J.S. & Chhuttani, P.N. (1970) Morphological and absorption studies of small intestine in hookworm infestation (ankylostomiasis). *Indian Journal of Medical Research* **58**, 317–325.
- Carroll, S.M., Grove, D.I. & Heenan, P.J. (1986) Kinetics of cells in the intestinal mucosa of mice following oral infection with *Ancylostoma ceylanicum*. *International Archives of Allergy and Applied Immunology* **79**, 26–32.

- Carroll, S.M., Robertson, T.A., Papadimitriou, J.M. & Grove, D.I. (1984) Transmission electron microscopical studies of the site of attachment of *Ancylostoma ceylanicum* to the small bowel mucosa of the dog. *Journal of Helminthology* **58**, 313–320.
- Carroll, S.M., Robertson, T.A., Papadimitriou, J.M. & Grove, D.I. (1985) Scanning electron microscopy of *Ancylostoma ceylanicum* and its site of attachment to the small intestinal mucosa of dogs. *Zeitschrift für Parasitenkunde* **71**, 79–85.
- Castro, G.A. (1990) Intestinal pathology. pp. 283–316 in Behnke, J.M. (Ed.) *Parasites: immunity and pathology*. London, Taylor & Francis.
- Cheng-Li, W., Hsiao-Su, H., Hsing-Chen, W. & Yu-Fang, P. (1966) The blood sucking activities of hookworms with special reference to the volume of blood withdrawn by *Ancylostoma caninum*. *Chinese Medical Journal* **85**, 11–20.
- Cliffe, L.J., Humphreys, N.E., Lane, T.E., Potten, C.S., Booth, C. & Grecis, R.K. (2005) Accelerated intestinal epithelial cell turnover: a new mechanism of parasite expulsion. *Science* **308**, 1463–1465.
- Coop, R.L., Angus, K.W. & Sykes, A.R. (1979) Chronic infection with *Trichostrongylus vitrinus* in sheep. Pathological changes in the small intestine. *Research in Veterinary Science* **26**, 363–371.
- Cooper, E.S., Whyte-Alleng, C.A., Finzi-Smith, J.S. & MacDonald, T.T. (1992) Intestinal nematode infections in children: the pathophysiological price paid. *Parasitology* **104**, S91–S103.
- Elliott, J.M. (1977) *Some methods for the statistical analysis of samples of benthic invertebrates*. Freshwater Biological Association, Cumbria, UK.
- Ferguson, A. & Jarrett, E.E.E. (1975) Hypersensitivity reaction of the small intestine: thymus independent reactions of experimental 'Partial villous atrophy'. *Gut* **16**, 114–117.
- Garside, P. & Behnke, J.M. (1989) *Ancylostoma ceylanicum* in the hamster. Observations on the host–parasite relationship during primary infection. *Parasitology* **98**, 283–289.
- Garside, P., Behnke, J.M. & Rose, R.A. (1990) Acquired immunity to *Ancylostoma ceylanicum* in hamsters. *Parasite Immunology* **12**, 247–258.
- Garside, P., Grecis, R.K. & Mowat, A.M. (1992) T lymphocyte dependent enteropathy in murine *Trichinella spiralis* infection. *Parasite Immunology* **14**, 217–225.
- Garside, P., Kennedy, M.W., Wakelin, D. & Lawrence, C.E. (2000) Immunopathology of intestinal helminth infection. *Parasite Immunology* **22**, 605–612.
- Graham, S., Courtois, P., Malaisse, W.J., Rozing, J., Scott, F.W. & Mowat, A.M. (2004) Enteropathy precedes type 1 diabetes in the BB rat. *Gut* **53**, 1437–1444.
- Ido, A., Numata, M., Kodama, M. & Tsubouchi, H. (2005) Mucosal repair and growth factors: recombinant human hepatocyte growth factor as an innovative therapy for inflammatory bowel disease. *Journal of Gastroenterology* **40**, 925–931.
- Kalkofen, U.P. (1970) Attachment and feeding behaviour of *Ancylostoma caninum*. *Zeitschrift für Parasitenkunde* **33**, 339–354.
- Kalkofen, U.P. (1974) Intestinal trauma resulting from feeding activities of *Ancylostoma caninum*. *American Journal of Tropical Medicine and Hygiene* **23**, 1046–1053.
- Kelly, P., Menzies, I., Crane, R., Zulu, I., Nickols, C., Feakins, R., Mwansa, J., Mudenda, V., Katubulushi, M., Greenwald, S. & Farthing, M. (2004) Responses of small intestinal architecture and function over time to environmental factors in a tropical population. *American Journal of Tropical Medicine and Hygiene* **70**, 412–419.
- Lawrence, C.E., Paterson, J.C.M., Higgins, L.M., MacDonald, T.T., Kennedy, M.W. & Garside, P. (1998) IL-4 regulated enteropathy in an intestinal nematode infection. *European Journal of Immunology* **28**, 2672–2684.
- Lawrence, C.E., Paterson, J.C.M., Wei, X.-Q., Liew, F.Y., Garside, P. & Kennedy, M.W. (2000) Nitric oxide mediates intestinal pathology but not immune expulsion during *Trichinella spiralis* infection in mice. *Journal of Immunology* **164**, 4229–4234.
- Loukas, A., Constant, S.L. & Bethony, J.M. (2005) Immunobiology of hookworm infection. *FEMS Immunology and Medical Microbiology* **43**, 115–124.
- MacDonald, T.T. & Monteleone, G. (2005) Immunity, inflammation, and allergy in the gut. *Science* **307**, 1920–1925.
- MacDonald, T.T., Bajaj-Elliott, M. & Pender, S.L.F. (1999) T cells orchestrate intestinal mucosal shape and integrity. *Immunology Today* **20**, 505–510.
- MacDonald, T.T., Monteleone, G. & Pender, L.F. (2000) Recent developments in the immunology of inflammatory bowel disease. *Scandinavian Journal of Immunology* **51**, 2–9.
- McDermott, J.R., Humphreys, N.E., Forman, S.P., Donaldson, D.D. & Grecis, R.K. (2005) Intraepithelial NK cell-derived IL-13 induces intestinal pathology associated with nematode infection. *Journal of Immunology* **175**, 3207–3213.
- Menon, S. & Bhopale, M.K. (1985) *Ancylostoma ceylanicum* (Looss, 1911) in golden hamsters (*Mesocricetus auratus*): pathogenicity and humoral immune response to a primary infection. *Journal of Helminthology* **59**, 143–146.
- Migasena, S., Gilles, H.M. & Maegraith, B.G. (1972) Studies in *Ancylostoma caninum* infection in dogs II. Anatomical changes in the gastrointestinal tract. *Annals of Tropical Medicine and Parasitology* **66**, 203–207.
- Miller, T.A. (1979) Hookworm infection in man. *Advances in Parasitology* **17**, 315–384.
- Pritchard, D.I., Quinnell, R.J., Moustafa, M., McKean, P.G., Slater, A.F.G., Raiko, A., Dale, D.D.S. & Keymer, A.E. (1991) Hookworm (*Necator americanus*) infection and storage iron depletion. *Transactions of the Royal Society of Tropical Medicine and Hygiene* **85**, 235–238.
- Prociw, P. (1997) Pathogenesis of human hookworm infection: insight from a 'new' zoonosis. *Chemical Immunology* **66**, 62–98.
- Radtke, F. & Clevers, H. (2005) Self-renewal and cancer of the gut: two sides of a coin. *Science* **307**, 1904–1909.
- Rajasekariah, G.R., Dhage, K.R., Deb, B.N. & Bose, S. (1985) *Necator americanus* and *Ancylostoma ceylanicum*: development of protocols for dual infection in hamsters. *Acta Tropica* **42**, 45–54.

- Ray, D.K., Bhopale, K.K. & Shrivastava, V.B.** (1972) Migration and growth of *Ancylostoma ceylanicum* in golden hamsters. *Journal of Helminthology* **46**, 357–362.
- Roche, M. & Layrisse, M.** (1966) The nature and causes of hookworm anemia. *American Journal of Tropical Medicine and Hygiene* **15**, 1031–1100.
- Sheehy, T.W., Meroney, W.H., Cox, R.S. Jr & Soler, J.E.** (1962) Hookworm disease and malabsorption. *Gastroenterology* **42**, 148–156.
- Symons, L.E.A.** (1965) Kinetics of the epithelial cells and morphology of the villi and crypts in the jejunum of the rat infected by the nematode *Nippostrongylus brasiliensis*. *Gastroenterology* **49**, 158–168.
- Symons, L.E.A.** (1976) Scanning electron microscopy of the jejunum of the rat infected by the nematode *Nippostrongylus brasiliensis*. *International Journal for Parasitology* **6**, 107–111.
- Verma, S., Sehgal, A.H., Chakravarti, R.N. & Chuttani, P.N.** (1968) Intestinal villi in the dog and effect of *Ancylostoma caninum* infection. *Journal of Pathology and Bacteriology* **95**, 568–571.
- Wells, H.S.** (1931) Observations on the blood sucking activities of the hookworm *Ancylostoma caninum*. *Journal of Parasitology* **17**, 167–182.

(Accepted 22 February 2006)
2006 Cambridge University Press