

Editorial Review

Literature review of alloplastic materials in ossiculoplasty

M. W. YUNG, PH.D., F.R.C.S., D.L.O.

Key words: Ossicular Prosthesis; Biocompatible Materials

The use of alloplastic materials in ossicular reconstruction has a long history. However, many new materials have been described and become commercially available without any evidence that they are superior to the existing ones. The aim of the present literature review is to understand why changes in materials used for ossicular reconstruction have occurred.

The literature review was conducted using a Medline search. In addition, the references of each captured publication were examined to identify earlier publications that had escaped the Medline search. In general, there has been a paucity of long-term follow-up studies. Only one randomized study comparing one alloplastic material to another was identified (Plastipore vs Ceravital).¹ Virtually all the reports were either a series on one particular type of ossicular prosthesis or compared results of different prostheses based on historical data. It has been difficult to compare the results from different reports because of many other variables affecting the outcome of ossiculoplasty such as the state of the middle ear and the stage of the ossiculoplasty. The criteria used by different authors to report success varied between reports e.g. different ways of calculating the frequency average from the audiogram and different levels of post-operative air-bone gap being used to describe 'success'. Some authors only reported extrusion but not exposure of the prosthesis. Furthermore, some surgeons modified their surgical techniques during the study period e.g. placing cartilage over the head plate of the prosthesis.

In order to make the comparison between different reports meaningful, the author considered both extrusion and exposure of the prosthesis as 'prosthesis-related complications'. A post-operative air-bone gap of 20 dB or less was used as the criterion for success following ossiculoplasty since this was described by the majority of the authors in their reports. Particular attention was given to the length of the follow-up period, the average fre-

quency for reporting of hearing results and the difference in the surgical techniques, in particular the use of cartilage over the head plate of the prosthesis.

Of many alloplastic materials that have been described, not many have stood the test of time. In Figure 1, a time line with the specific year when each alloplastic material was first reported in clinical use is shown.^{2–13} Some materials were more popular than others, at least for a period. Some are still being used at the present time. These specific alloplastic materials are highlighted on the time line and are given a more detailed review.

The first report of using alloplastic material in ossiculoplasty was made in 1952, when Wullstein used an oval strut of vinyl-acrylic 'palavit' as an acoustic transmitter between the mobile footplate and the tympanic membrane graft.² Poor results with this material quickly caused him to abandon its use. Following the success of using polyethylene rods in stapes surgery, Shea and Austin used a length of polyethylene 90 tubing to reconstruct the ossicles in tympanoplasty.^{4,14} Some surgeons, including House¹⁵ and Hayden¹⁶ reported initial success with this material. Others, such as Shambaugh, reported a high rate of post-operative labyrinthine damage of up to 15 per cent of cases.¹⁷ Inflammatory tissue reactions have also been histologically confirmed following the use of polyethylene grafts in the oval windows of cats.^{18,19}

In 1962, Austin reported the use of polytetrafluoroethylene (PTFE) tubing as a hollow 'umbrella like' columella in ossiculoplasty. The greater compatibility of PTFE, which is ensheathed by mucosa in the middle ear, has been demonstrated in experimental animals.^{18,19} In 1969, Palva *et al.* first reported using metallic implants in chronic otitis media.⁵ Whereas both PTFE and metals give favourable results in stapes surgery, these solid plastic and metallic materials have not been so successful in tympanoplasty procedures. Manifestations of absorption at the ossicular interfaces and spontaneous rejection from the tympanic membrane have been observed.^{20–24} The results of these materials were so disappointing, that by the time of the

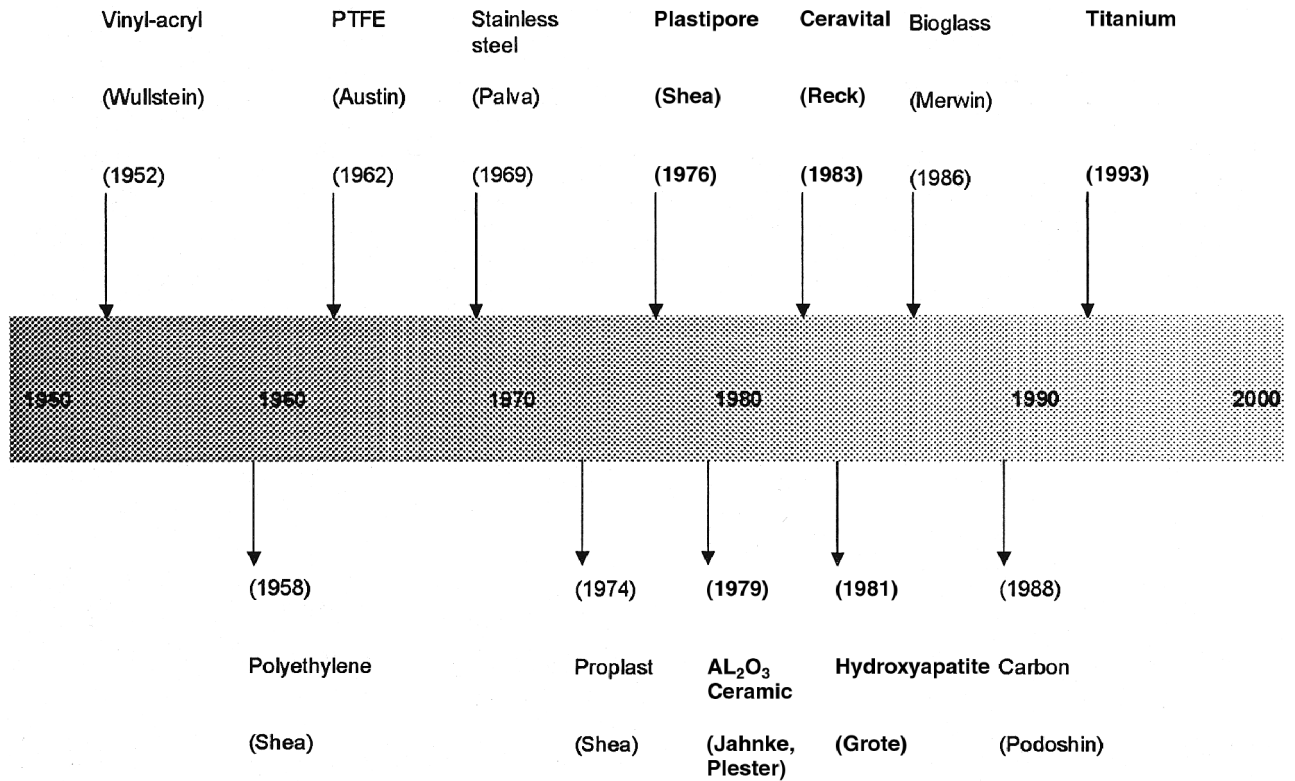


FIG. 1

A time line showing the specific year when each alloplastic material was introduced for clinical use (the highlighted alloplastic materials are discussed in greater length in the text).

Fourth Shambaugh-Shea Workshop on middle-ear surgery in 1971, there was general agreement that these solid plastic and metallic implants had no place in the surgical treatment of chronic otitis media.²⁴

The interest in alloplastic materials in ossiculoplasty was rekindled with the introduction of Proplast[®] in 1974 and Plastipore[®] in 1976 by Shea.^{6,7} Proplast is a composite of PTFE and vitreous carbon. It contains pores that make up 70 to 90 per cent of its volume and hence the ossicular prosthesis is that of a resilient black felt sponge. Plastipore[®] is a semi-soft white sponge of high-density polyethylene because it is also 70 to 90 per cent porous. Both Proplast[®] and Plastipore[®] have sufficient porosity to encourage tissue

ingrowths. Shea eventually abandoned Proplast[®] in favour of Plastipore[®] because he felt the latter to be superior in structure.²⁵

Plastipore was the first commercialised alloplastic material used worldwide. Shea and Emmett advocated that the head of the prosthesis should be placed under the eardrum to allow tissue ingrowths into the prosthesis head.²⁵ Although the short-term result was encouraging, there was an unacceptable long-term extrusion rate. Smyth reported a 12 per cent extrusion rate at five years and Portmann reported a 30 per cent extrusion rate at two years when the Plastipore[®] prosthesis was placed in direct contact with the tympanic membrane.^{26,27} Using a

TABLE I

A COMPARISON OF THE FUNCTIONAL RESULTS AND EXTRUSION RATES OF PLASTIPORE OSSICULAR PROSTHESES AMONGST DIFFERENT CLINICAL REPORTS

Author (year)	No. cases	Follow-up period	Extrusion/Exposure	Post-op	Post-op
				ABG = <20 dB	ABG = <20 dB
				PORP	TORP
Smith ²⁶	116	5 years	12%		
Portmann <i>et al.</i> ²⁷	146	2 years	30%		
House <i>et al.</i> ³³	1040*	2 months	3.7%	69% (4 freq)	61% (4 freq)
Bayazit <i>et al.</i> ³²	156*	<1 year	4.2%	63% (3 freq)	43% (3 freq)
Brackman <i>et al.</i> ³¹	1042*	6 months–4 years	7%	53%	33%
Jackson <i>et al.</i> ³⁰	141*	1–4 years	10%	43%	49%
Mangham <i>et al.</i> ¹	53*	3 years		59% (3 freq)	27% (3 freq)
Slater <i>et al.</i> ²⁹	37*	4 years	1.3% at 6 months	80% (3 freq)	44% (3 freq)

*Indicates that cartilage disks were used to interpose between the prosthesis and tympanic membrane; ABG = air-bone gap; 4 freq = 4 frequency average of 0.5, 1, 2 and 3 KHz; 3 freq = 3 frequency average of 0.5, 1 and 2 KHz

TABLE II

A COMPARISON OF THE FUNCTIONAL RESULTS AND EXTRUSION RATES OF ALUMINIUM OXIDE OSSICULAR PROSTHESES AMONGST DIFFERENT CLINICAL REPORTS

Author (year)	No. cases	Follow-up period	Extrusion/ Exposure	Post-op ABG = <20 dB	Post-op ABG = <20 dB
				PORP	TORP
Yamamoto <i>et al.</i> ³⁵	173	1–5 years	7%	66%	53%
Plester <i>et al.</i> ³⁴	112	2 years		Combined PORP & TORP = 64%	

post-operative air-bone gap of 10 dB or less as the criterion for success, Smyth reported a success rate of 51 per cent at one year dropping to 19 per cent at five years following Plastipore total ossicular reconstruction prosthesis (TORP) reconstruction.²⁶ Kerr examined 16 Proplast[®] and 52 Plastipore[®] prostheses removed at revision surgery. He noticed that multinucleated foreign body giant cells were present in large numbers in both types together with histological evidence of breakdown of the prostheses.²⁸

Many authors tried to reduce the extrusion of Plastipore by placing a cartilage disc over the prosthesis. This modification of technique has reduced the extrusion rate to less than 10 per cent, at least in many medium-term studies.^{29–33} In spite of many other alloplastic materials being introduced since then, Plastipore is still favoured by some otologists.^{32,33} Table I listed the prosthesis extrusion/exposure rates and the functional results reported by different authors. Other clinical reports that do not contain data that could be compared directly were not included. From two separate reports provided long-term follow-up data (three and four years) on Plastipore, the success rate of Plastipore partial ossicular reconstruction prosthesis PORP was 59 per cent and 80 per cent and that of Plastipore TORP was 27 per cent and 44 per cent, when a three-frequency average (0.5, 1 and 2 KHz) was used to calculate the post-operative air-bone gap.^{1,29} Both reports involved interposition of cartilage between the tympanic membrane and the head plate of the prosthesis.

An aluminium oxide ceramic (Al₂O₃) ossicular prosthesis was introduced by Jahnke and Plester into clinical practice in 1979.⁸ At least from the relatively few clinical reports in the literature, the results were comparable to that of Plastipore (Table II).^{34,35} Like Plastipore, cartilage interposition is recommended between the prosthesis and the tympanic membrane.

A piece of perichondrium needs to be placed between the footplate and the Al₂O₃ TORP to reduce the risk of perforation of the footplate. It is not entirely clear why this material was never accepted widely amongst otologists, when there was no major concern over its biocompatibility.

Ceravital was another alloplastic material that was very popular in the 1980s before it was eventually withdrawn from the market. It is a glass ceramic material composed of the oxides of silicon, calcium, phosphorus, sodium, potassium and magnesium.³⁶ It is bioactive and when implanted bonds to adjacent bone.³⁷ The first clinical report on the use of a Ceravital ossicular prosthesis was by Beck in 1983.⁹ He recommended that the surface of the prosthesis that comes in contact with the eardrum should be coated with autogenous bone paste in order to induce growth of a layer of autologous bone between the eardrum and the implant. Ceravital ossicular prostheses were marketed initially by Ernst Leitz, Wetzlar, Germany and subsequently by Xomed, Jacksonville, USA.

Several authors have reported good short- and medium-term results with Ceravital ossicular prostheses with reference to hearing gain and extrusion rate.^{1,9,37–41} In one particular report by Austin, the prosthesis extrusion/exposure rate of the prostheses was reported to be 29 per cent. However, he did not use autologous bone paste between the head plate of the prosthesis and the tympanic membrane as recommended by the manufacturer.⁴¹ In clinical trials with a longer follow up, it became apparent that some prostheses became absorbed eventually. The absorption rate was quoted to be 0.7 per cent, 1.6 per cent and 5.1 per cent in three different reports (Table III).^{1,9,37} However, a high number of patients in these trials were lost to long-term follow up. The concern was enough for the manufacturer to stop the production of the Ceravital prosthesis. In a more systematic long-term follow-up study of up to

TABLE III

A COMPARISON OF THE ABSORPTION AND EXTRUSION RATES OF CERAVITAL OSSICULAR PROSTHESES AMONGST DIFFERENT CLINICAL REPORTS

Authors (year)	No. cases	Follow-up period	Absorption rate	Extrusion/Exposure rate
Portmann <i>et al.</i> ²⁷	50	1 year (mean)	0	8%
Babighan ³⁸	70	1–3 years	0	8%
Blayney <i>et al.</i> ³⁷	128	2 years (mean)	1.6%	3%
Gersdorff <i>et al.</i> ³⁹	53	2 years (mean)	0	4%
Niparko <i>et al.</i> ⁴⁰	37	3 years (mean)	0	3%
Reck ⁹	1056	7 years (maximum)	0.7%	
Mangham <i>et al.</i> ¹	39	3 years (mean)	5%	
Austin ^{41*}		1 year		29%

*Bone paste was not used between the prosthesis and tympanic membrane

TABLE IV

A COMPARISON OF THE FUNCTIONAL RESULTS AND EXTRUSION RATES OF HYDROXYAPATITE OSSICULAR PROSTHESES AMONGST DIFFERENT CLINICAL REPORTS

Author (year)	No. cases	Follow-up period	Extrusion/Exposure	Post-op	Post-op
				ABG = <20 dB	ABG = <20 dB
				PORP	TORP
House ³³	127	3 months	7.9%	57% (4 freq)	39% (4 freq)
Wehr ⁴³	42	1 years	30%	89% (3 freq)	78% (3 freq)
Murakami ⁴⁴	106	2 years	7.5%	62%	56%
Shinohara ⁴⁵	106	>5 year	16%		
Grote ⁴⁶	170	3–8 years (mean = 5 yrs)	4%	84%	64%

ABG = air-bone gap; 4 freq = 4 frequency average of 0.5, 1, 2 and 3 KHz; 3 freq = 3 frequency average of 0.5, 1 and 2 KHz

14 years, the incidence of absorption of Ceravital was found to be 36 per cent and only 16 per cent of the implanted ears maintained a good audiological outcome.⁴²

The most popular alloplastic material to date is hydroxyapatite (HA) or calcium triphosphate. It is a bioactive ceramic that resembles the mineral matrix of bone. The clinical results of hydroxyapatite in middle-ear reconstruction was first reported by Grote in 1981.¹⁰ It is still being used world wide and has so far stood the test of time. The prosthesis extrusion/exposure rate is generally observed to be less than 10 per cent (Table IV).^{33,43–46} However, it is surprising that there were not many long-term follow-up studies in the literature. Grote observed four per cent extrusion in a long-term study using hydroxyapatite. Using a post-operative air-bone gap of 20 dB or less as 'success', he reported 84 per cent success for PORP and 64 per cent success for TORP.⁴⁶ The only exception to the relatively 'favourable' results of hydroxyapatite was the long-term study by Shinohara, which reported a prosthesis extrusion/exposure rate of 16 per cent.⁴⁵ One of the difficulties in comparing the results of various clinical reports is that the surgical techniques differ amongst surgeons, with some surgeons using cartilage sheets over the prosthesis to prevent extrusion.⁴⁷

The biocompatible nature of hydroxyapatite allows the head plate of the ossicular prosthesis to be placed directly in contact with the tympanic membrane. In order to make the hydroxyapatite prosthesis more user-friendly, various composite hydroxyapatite prostheses have been subsequently developed. These prostheses consist of a hydroxyapatite head plate and a malleable shaft made from

other materials, so that they can be trimmed easily with a scalpel. These materials include Plastipore,⁴⁸ Polycel (thermal-fused Plastipore), PTFE,⁴⁸ FLEX HA (a mixture of hydroxyapatite and Silastic[®]) and HAPEX (hydroxyapatite reinforced polyethylene composites). Some prostheses even incorporate a stainless steel core in the shaft to aid sound conduction.⁴⁹ The various combinations result in an explosion of the number of designs of composite hydroxyapatite prostheses. This makes direct comparison of results between different surgeons even more difficult. On the whole, these composite hydroxyapatite prostheses also had a medium and long-term extrusion rate of less than five per cent, but the success rate varies greatly between reports. The results of three different composite hydroxyapatite prostheses are listed in Table V.^{47–49}

Ossicular prostheses made from bioglass were first introduced by Merwin in 1986.¹¹ Although commercially available, they have not gained worldwide popularity and hence the number of clinical reports is relatively small. Ossicular prostheses made from carbon were also tested in a clinical trial by Podoshin in 1988. In spite of their biocompatibility, carbon ossicular prostheses are not available commercially because the material is brittle and difficult to handle.¹² Furthermore, in a small clinical study using carbon fibre reinforced carbon as the ossicular prosthesis, Blayney *et al.* reported a 40 per cent extrusion rate at nine months and a further eight per cent with inflammatory responses around the implant.⁵⁰

Titanium (Ti) was established as an excellent biocompatible material by Branemark in the 1970s.⁵¹ It was first introduced as an alloplastic material for ossiculoplasty in 1993.¹³ The material is light and

TABLE V

A COMPARISON OF THE FUNCTIONAL RESULTS AND EXTRUSION RATES OF DIFFERENT COMPOSITE OSSICULAR PROSTHESES AMONGST DIFFERENT CLINICAL REPORTS. THESE PROSTHESES ALL HAVE A HYDROXYAPATITE HEAD PLATE

Author (year)	Type of prosthesis	No. cases	Follow-up period	Extrusion/Exposure	Post-op	Post-op
					ABG = <20 dB	ABG = <20 dB
					PORP	TORP
Goldenberg ⁴⁸	HA head + Plastipore shaft	186	7–18 months	4.5%	Combined PORP & TORP = 49% (4 freq)	
Black ⁴⁹	HA head + PTFE shaft	125	6–18 months	4.8%	68% (3 freq)	62.5% (3 freq)
Colletti <i>et al.</i> ⁴⁷	HA head + Plastipore coated steel shaft	65	5 years	0%	Combined PORP & TORP = 69% (4 freq)	

ABG = air-bone gap; HA = hydroxyapatite; PTFE = polytetrafluoroethylene; 4 freq = 4 frequency average of 0.5, 1, 2 and 3 KHz; 3 freq = 3 frequency average of 0.5, 1 and 2 KHz

TABLE VI

A COMPARISON OF THE FUNCTIONAL RESULTS AND EXTRUSION RATES OF TITANIUM OSSICULAR PROSTHESIS AMONGST DIFFERENT CLINICAL REPORTS

Author (year)	No. cases	Follow-up period	Extrusion/ Exposure	Post-op	Post-op
				ABG = <20 dB PORP	ABG = <20 dB TORP
Begall <i>et al.</i> ⁵¹	528 (14 hospitals)	6 months	4%		
Wang <i>et al.</i> ⁵²	124	>1 years	0%	Combined PORP & TORP = 49%	
Zenner <i>et al.</i> ⁵³	114	1–2 years		70% (at 2 KHz)	60% (at 2 KHz)
Dalchow <i>et al.</i> ¹³	1304	6–72 months	1%	Combined PORP & TORP + 76% (4 freq)	

ABG = air-bone gap; 4 freq = 4 frequency average of 0.5, 1, 2 and 3 KHz

strong, allowing many possibilities in the prosthetic design. The shaft of the prosthesis can be thin and yet rigid. All the current designs have an open head plate rather than a solid plate. It allows the surgeons to observe the position of the bottom end of the prosthesis during the placement of the prosthesis. The bottom end of the Ti PORP fits better over the stapes head due to its 'claw-like' design instead of a 'cup-like' design. A piece of cartilage needs to be interposed between the head plate and the tympanic membrane to prevent extrusion. Like hydroxyapatite, Ti ossicular prostheses are being marketed worldwide. As new designs of Ti prosthesis are developing all the time, it makes the direct comparison of clinical results in the literature more difficult, particularly as some manufacturers are producing composite prosthesis using Ti for the head plate and hydroxyapatite for the shaft. On the whole, medium-term follow-up reports on the Ti ossicular prosthesis indicate that the extrusion rate is less than five per cent and a 'success' rate comparable to that of the hydroxyapatite prosthesis (Table VI).^{13,52–54}

In summary, the three most popular alloplastic materials used in ossiculoplasty at the present time are Plastipore, hydroxyapatite and titanium. However, there are a large number of different designs of prostheses. Many are composite prostheses combining two or three different alloplastic materials. Prostheses with a Plastipore or titanium head plate require the interposition of a cartilage disc between the prosthesis and the tympanic membrane, whereas hydroxyapatite prostheses can be placed directly in contact with the tympanic membrane. On the whole, the rate of extrusion of modern alloplastic ossicles is between five to 10 per cent. Such a complication is often due to the pathology in the middle-ear cleft rather than prosthesis-related. It is impossible to draw a conclusion on which is the best prosthesis, as there is a paucity of prospective randomized trials and systematic long-term follow-up studies.

References

- Mangham CA, Lindeman RC. Ceravital versus Plastipore in tympanoplasty: a randomised prospective trial. *Ann Otol Rhinol Laryngol* 1990;**99**:112–6
- Wullstein HL. Operationen am Mittelohr mit Hilfe des freien Spaltlappen-Transplantates. *Arch Otorhinolaryngol* 1952;**161**:422–35
- Shea JJ. Fenestration of the oval window. *Ann Otol Rhinol Laryngol* 1958;**67**:932–51
- Austin DF. Vein graft tympanoplasty: Two-year report. *Trans Am Acad Ophthalmol Otolaryngol* 1963;**67**:198–208
- Palva T, Palva A, Karja J. Results with 2- or 3-legged wire columellization in chronic ear surgery. *Ann Otol* 1971;**80**:760–5
- Shea JJ, Homsy CA. The use of Proplast in otologic surgery. *Laryngoscope* 1974;**84**:1835–45
- Shea JJ. Plastipore total ossicular replacement prosthesis. *Laryngoscope* 1976;**86**:239–40
- Jahnke K, Plester D, Heimke G. Aluminiumoxide-Keramik, ein Bioinertes Material für die Mittellohrchirurgie. *Arch Otorhinolaryngol* 1979;**223**:373–6
- Reck R. Bioactive glass ceramic: a new material in tympanoplasty. *Laryngoscope* 1983;**93**:196–9
- Grote J. Tympanoplasty with calcium phosphate. *Arch Otol* 1984;**110**:197–9
- Merwin GE. Bioglass middle ear prosthesis: preliminary report. *Ann Otol Rhinol Laryngol* 1986;**95**:78–82
- Podoshin L, Fradis M, Gertner R. Carbon-carbon middle ear prosthesis: A preliminary clinical human trial report. *Otolaryngol Head Neck Surg* 1988;**99**:278–81
- Dalchow CV, Grun D, Stupp HF. Reconstruction of the ossicular chain with titanium implants. *Otolaryngol Head Neck Surg* 2001;**125**:628–30
- Shea JJ. Tympanoplasty in chronic right otitis media: a case report. *Memphis Med* 1958;**33**:271–5
- House HP. Polyethylene in middle ear surgery. *Arch Otolaryngol* 1960;**71**:926–31
- Hayden GD. Results with polyethylene T-strut in the restoration of hearing. *Laryngoscope* 1961;**71**:5054–61
- Shambaugh GE. Developmental anomalies of the sound conduction apparatus and their surgical correction. *Ann Otol Rhinol Laryngol* 1952;**61**:873
- Goldman DJ, Nalebuff J, Druss JG. Experimental observations on prosthetic materials in stapedial surgery with special reference to the use of Teflon. *Laryngoscope* 1962;**72**:169–81
- Withers BT, Hatfield SE, Richmond RW. Drum and middle ear grafts in cats. *Laryngoscope* 1963;**73**:1022–43
- Guilford FR. Tympanoplasty: Use of prostheses in conduction mechanism. *Arch Otolaryngol* 1964;**80**:80–6
- Jobe R, Iverson R, Vistnes L. Bone deformation beneath alloplastic implants. *Plast Reconstr Surg* 1973;**51**:169–73
- Proctor B. What happens in type III tympanoplasty. *Laryngoscope* 1965;**75**:1307–19
- Sheehy JL. Ossicular problems in tympanoplasty. *Arch Otolaryngol* 1965;**81**:115–22
- Palva T, Palva A, Karja J. Ossicular reconstruction in chronic ear surgery. *Arch Otolaryngol* 1973;**98**:340–8
- Shea JJ, Emmett JR. Biocompatible ossicular implants. *Arch Otolaryngol* 1978;**104**:191–6
- Symth GDL. TORPs – How have they fared after five years? *J Laryngol Otol* 1983;**97**:991–3
- Portmann M, Bebear JP, Bagot D, Arc M, Vazel P, Paiva A, *et al.* Comparative study of different ossicular prostheses in tympanoplasty (Proplast, Plastipore, Ceravital). Analysis of clinical results, histopathological and hearing in the long term (250 cases). In: Grote JJ, ed. *Biomaterials in Otolaryngology*. Boston: Martinus Nijhoff Publishers, 1984,177–86
- Kerr AG. Proplast and Plastipore. *Clin Otolaryngol* 1981;**6**:187–91
- Slater PW, Rizer FM, Schuring AG, Lippy WH. Practical use of total and partial ossicular replacement prostheses in ossiculoplasty. *Laryngoscope* 1997;**107**:1193–8

- 30 Jackson CG, Glasscock ME, Schwaber MK, Nissen AJ, Christiansen SG. Ossicular chain reconstruction: The TORP and PORP in chronic ear disease. *Laryngoscope* 1983;**93**:981–8
- 31 Brackmann DE, Sheehy JL, Luxford WM. TORPs and PORPs in tympanoplasty: A review of 1042 operations. *Otolaryngol Head Neck Surg* 1984;**92**:32–7
- 32 Bayazit Y, Goksu N, Beder L. Functional results of Plastipore prostheses for middle ear ossicular chain reconstruction. *Laryngoscope* 1999;**109**:709–11
- 33 House JW, Teufert KB. Extrusion rates and hearing results in ossicular reconstruction. *Otolaryngol Head Neck Surg* 2001;**125**:135–41
- 34 Plester D, Jahnke K. Ceramic implants in otologic surgery. *Am J Otol* 1981;**3**:104–8
- 35 Yamamoto E. Long-term observations on ceramic ossicular replacement prosthesis (CORP). *Laryngoscope* 1988;**98**:402–4
- 36 Bromer H, Deutscher K, Blencke B, Pfeil E, Strunz V. Properties of the bioactive implant material 'Ceravital'. *Sci Ceram* 1977;**9**:219–25
- 37 Blayney AW, Bebear JP, Williams KR, Portmann M. Ceravital in ossiculoplasty: experimental studies and early clinical results. *J Laryngol Otol* 1986;**100**:1359–66
- 38 Babighian G. Bioactive ceramics versus Proplast implants in ossiculoplasty. *Am J Otol* 1985;**6**:285–90
- 39 Gersdorff MCH, Maisin JP, Munting E. Comparative study of the clinical results obtained by means of Plastipore and ceramic ossicular prosthesis and bone allografts. *Am J Otol* 1986;**7**:294–7
- 40 Niparko JK, Kemink JL, Graham MD, Kartush JM. Bioactive glass ceramic in ossicular reconstruction: a preliminary report. *Laryngoscope* 1988;**98**:822–5
- 41 Austin D. Columellar tympanoplasty. *Am J Otol* 1985;**6**:464–7
- 42 Brewis C, Orrell J, Yung MW. Ceravital revisited: Lessons to be learned. *Otol Neurotol* 2003;**24**:20–3
- 43 Wehrs RE. Incus interposition and ossiculoplasty with hydroxyapatite prostheses. *Otolaryngol Clin N Am* 1994;**27**:677–88
- 44 Murakami Y, Hisamatsu K, Nozawa I, Ogino J, Ganbo T. Ossicular chain reconstruction with the use of alloplastic prosthesis; a comparative study in chronic middle ear disease. *Pract Otol* 1995;**79**:177–84
- 45 Shinohara T, Gyo K, Saiki T, Yanagihara N. Ossiculoplasty using hydroxyapatite prostheses: long-term results. *Clin Otolaryngol* 2000;**25**:287–92
- 46 Grote JJ. Reconstruction of the middle ear with hydroxyapatite implants: long-term results. *Ann Otol Rhinol Laryngol* 1990;**144**(suppl):12–6
- 47 Colletti V, Fiorino FG. Malleus-to-footplate prosthetic interposition: Experience with 265 patients. *Otolaryngol Head Neck Surg* 1999;**120**:437–44
- 48 Goldenberg RA. Ossiculoplasty with composite prostheses. PORP and TORP. *Otolaryngol Clin N Amer* 1994;**27**:727–45
- 49 Black B. Design and development of a contoured ossicular replacement prosthesis: clinical trials of 125 cases. *Am J Otol* 1990;**11**:85–9
- 50 Blayney AW, Romero Rio JA, Williams KR, Guilhaume A, Bagot D'Arc M, Portmann M. Experimental and clinical aspects of carbon as a middle ear prosthesis. *Clin Otolaryngol* 1986;**11**:189–97
- 51 Branemark PI, Adell R, Breine U, Hansson BO, Lindstrom J, Ohlsson A. Intra-osseous anchorage of dental prosthesis. I. Experimental studies. *Scand J Plast Reconstr Surg* 1969;**3**:81–100
- 52 Begall K, Zimmermann H. Rekonstruktion der Gehörknöchelchenkette mit Titan-Implantaten. *Laryngo-Rhino-Otol* 2000;**79**:139–45
- 53 Wang X, Song J, Wang H. Results of tympanoplasty with titanium prosthesis. *Otolaryngol Head Neck Surg* 1999;**121**:606–9
- 54 Zenner HP, Stegmaier A, Lehner R, Baumann I, Zimmermann R. Open Tübingen titanium prostheses for ossiculoplasty: a prospective clinical trial. *Otol Neurotol* 2001;**22**:582–9

Address for correspondence:
Mr M. W. Yung,
Department of Otolaryngology,
The Ipswich Hospital,
Heath Road,
Ipswich IP5 4PD, UK.