The Journal of Laryngology & Otology

cambridge.org/jlo

Management of supraglottic stenosis using interarytenoid Z-plasty: how I do it

Hussein Jaffal, Parker Tumlin and Erica McArdle

Department of Otolaryngology–Head and Neck Surgery, West Virginia University, Morgantown, WV, USA

Short Communication

Hussein Jaffal takes responsibility for the integrity of the content of the paper

Cite this article: Jaffal H, Tumlin P, McArdle E. Management of supraglottic stenosis using interarytenoid Z-plasty: how I do it. *J Laryngol Otol* 2024;1–4. https://doi.org/10.1017/S0022215124000926

Received: 3 February 2024
Revised: 17 March 2024
Accepted: 29 March 2024

Keywords:
Laryngomalacia; airway obstruction; laryngostenosis; otorhinolaryngologic surgical procedures; pediatrics

Corresponding author:
Hussein Jaffal;
Email: hussein.jaffal@hsc.wvu.edu

Abstract

Background. Supraglottoplasty is the primary surgical treatment of congenital laryngomalacia. Supraglottic stenosis is a rare complication of supraglottoplasty that is difficult to manage.
Methods. This study presents a new endoscopic mucosa-sparing Z-plasty double transposition flap technique that was used to manage supraglottic stenosis following supraglottoplasty for severe congenital laryngomalacia in an eight-month-old infant.
Results. At 10 months post-operatively, the patient remained asymptomatic and flexible laryngoscopy showed adequate supraglottic patency.
Conclusion. Endoscopic interarytenoid Z-plasty is a safe and effective technique in the management of paediatric supraglottic stenosis.

Introduction

Supraglottic stenosis is a rare complication of supraglottoplasty performed for laryngomalacia and has been reported to occur in up to 4 per cent of cases.[1] It is thought to result from excessive mucosal resection, especially in the interarytenoid area. When managing supraglottic stenosis, endoscopic interventions are preferred over open procedures when possible.[2] While mucosa preservation is essential to prevent restenosis, only two previous reports have presented endoscopic, mucosa-sparing techniques. Yilmaz described a Z-plasty technique to expand the supraglottic airway in adults with supraglottic stenosis not related to supraglottoplasty.[3] Sandu *et al.* reported on a technique to manage post-supraglottoplasty supraglottic stenosis using rotation mucosal flaps to cover the divided scar of the aryepiglottic folds.[4]

We present an endoscopic mucosa-sparing Z-plasty double transposition flap technique that was used to manage post-supraglottoplasty supraglottic stenosis in an infant with history of severe congenital laryngomalacia.

Case report

A case of supraglottic stenosis following supraglottoplasty treated with an interarytenoid Z-plasty is described. Institutional review board approval was obtained and the authors assert that all procedures contributing to this work comply with the ethical standards of the relevant national and institutional guidelines on human experimentation (West Virginia University Institutional Review Board) and with the Helsinki Declaration of 1975, as revised in 2008. Consent was obtained from the patient's legal guardian to present the treatment course as well as intra-operative images and video recordings.

The patient was an eight-month-old female with a history of severe congenital laryngomalacia. She previously underwent supraglottoplasty at 12 days of age, with bilateral division of the aryepiglottic fold and excision of redundant supra-arytenoid tissue. This was followed by revision supraglottoplasty at six weeks of age consisting of division of the aryepiglottic folds. Both procedures we performed using cold-steel instruments. For the first two months of life she had severe, poorly controlled gastroesophageal reflux and recurrent vomiting. She required a nasogastric tube for feeding until she underwent gastrostomy tube placement and she had severe oral aversion. Additionally, she had intrauterine drug exposure and was diagnosed with chromosomal duplication and diaphragmatic flutter. Following the second supraglottoplasty procedure, her airway symptoms resolved and she was discharged home. Over the subsequent months she developed stridor that worsened progressively. On clinic follow up at the age of eight months, she was reported to have frequent apnoeic spells with perioral cyanosis. Flexible laryngoscopy showed fixed supraglottic narrowing consistent with supraglottic stenosis without the ability to visualise the vocal folds.

The patient was admitted and underwent direct laryngoscopy and bronchoscopy along with endoscopic repair of supraglottic stenosis using interarytenoid Z-plasty. Anaesthesia was induced using sevoflurane and a propofol infusion was used to maintain spontaneous breathing. Dexamethasone was administered (0.5 mg/kg).

Direct laryngoscopy confirmed supraglottic stenosis with thick supra-arytenoid scar tissue extending anteriorly and causing a fixed obstruction (Figure 1). Bronchoscopy

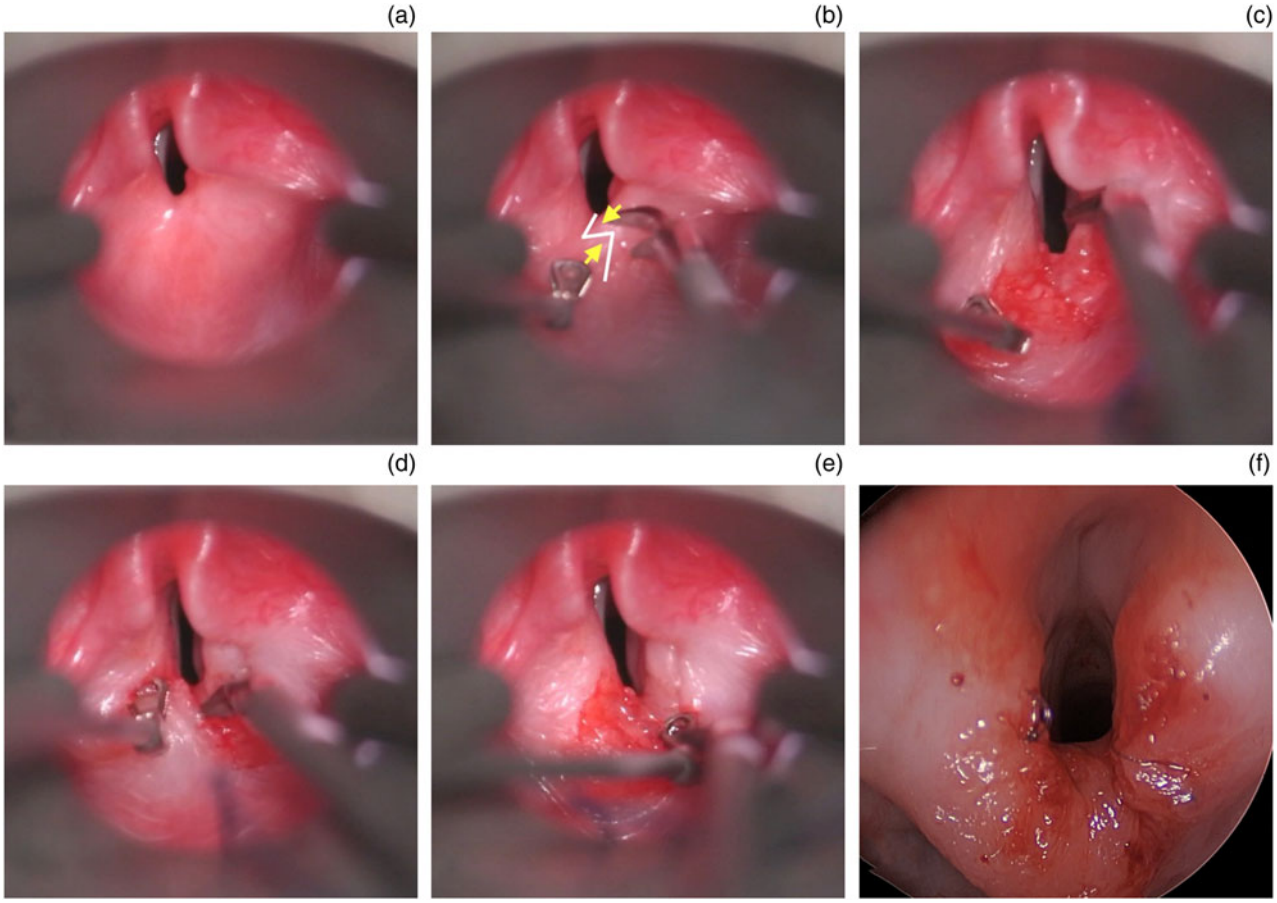

Figure 1. Surgical technique. (a) Suspension microlaryngoscopy with supraglottic stenosis noted. (b) Planned incision lines for interarytenoid Z-plasty. Yellow arrows point to the planned mucosal flaps. (c) Z-plasty incisions have been made and mucosal flaps elevated. (d) The left posterior flap is advanced and rotated anteriorly. (e) The right anterior flap is advanced and rotated posteriorly. (f) Supraglottis following interarytenoid Z-plasty and suture placement.

was performed using a rigid endoscope and no other airway abnormalities were noted. The arytenoids cartilages were mobile on palpation with a right-angle probe. The larynx was suspended using a small Lindholm laryngoscope, and binocular microscopy was used for visualisation.

Triangular microlaryngoscopy forceps were used for retraction while curved microlaryngoscopy scissors were used to incise the mucosa overlying the interarytenoid scar to create a triangular-shaped mucosal flap (Figures 1 and 2). The base of the triangular mucosal flap was the posterior aspect of the left arytenoid mucosa. Scar tissue deep to the mucosal flap was excised while undermining the flap.

A second triangular shaped mucosal flap with its base along the anterior aspect of the right arytenoid mucosa was created in a similar fashion. Mobilisation of the flaps was assessed using forceps. The left flap was then rotated and advanced anteriorly and secured using a 7-0 polydioxanone suture (PDS) in a simple interrupted fashion. The right flap was rotated and advanced posteriorly. Additional 7-0 PDS sutures were placed in a simple interrupted fashion. Four sutures were used. Care was taken to not place excess tension on the flaps.

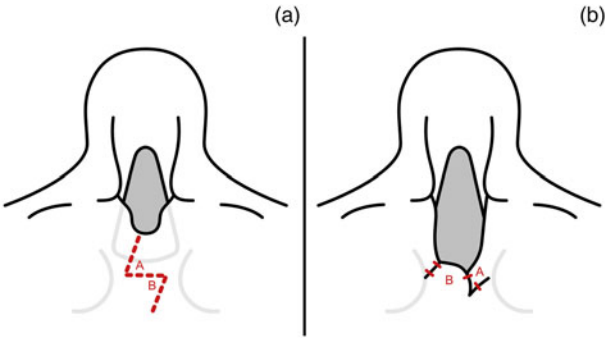

Figure 2. Illustration of the interarytenoid Z-plasty. (a) Planned incision lines. (b) Flaps (A and B) rotated and sutured.

The procedure resulted in significant improvement in the patency of the supraglottic airway with adequate mucosal cover (Figure 1). The video details the set up and the technique used (Supplementary material).

The patient was admitted to the paediatric step-down unit post-operatively. Famotidine was restarted and an additional dose of dexamethasone was administered. Her post-operative course was uneventful, and she was breathing comfortably on room air without stridor. The patient was discharged home on post-operative day 1.

The patient was seen at 3, 4, 6 and 10 months post-operatively. Her apnoeic spells and stridor had resolved, and she continued to be free of any airway or obstructive sleep symptoms. Flexible laryngoscopy was performed at every post-operative visit, with a stable finding of mild residual supraglottic stenosis (Figure 3). The patient has also undergone a sedated procedure not related to airway with use of a laryngeal mask airway without airway concerns. The patient had experienced severe oral aversion, which improved with feeding and swallowing therapy. At 10 months post-operatively she underwent a modified barium swallow study with no aspiration or

https://doi.org/10.1017/S0022215124000926 Published online by Cambridge University Press

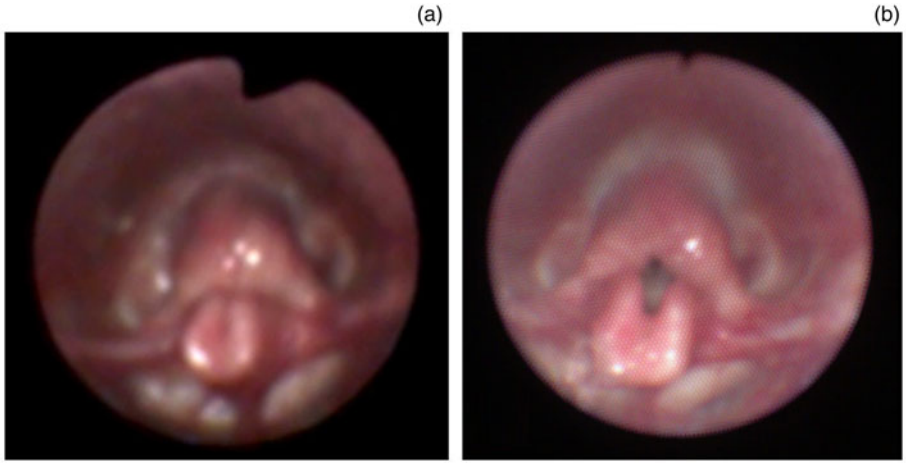

Figure 3. Flexible laryngoscopy. (a) The pre-operative awake flexible laryngoscopy during inspiration. (b) The 10-month post-operative awake flexible laryngoscopy during inspiration.

penetration with thin liquids and she was mostly orally fed with a plan to remove her gastrostomy tube.

Discussion

Supraglottic stenosis is a rare major complication of supraglottoplasty.[1] It consists of cicatricial narrowing of the supraglottic airway resulting in fixed obstruction, as opposed to the dynamic obstruction with laryngomalacia. A meta-analysis comparing unilateral with bilateral supraglottoplasty showed that supraglottic stenosis was more likely to occur with bilateral supraglottoplasty.[5] This supports the commonly held theory that supraglottic stenosis can result from excessive mucosal resection during supraglottoplasty. Other potential contributory factors may include young age, presence of a nasogastric tube and gastroesophageal reflux. However, proving an association is difficult given the rarity of occurrence and/or possible under-reporting of supraglottic stenosis following supraglottoplasty.

Our patient underwent standard, conservative supraglottoplasty with preservation of the interarytenoid mucosa yet she developed supraglottic stenosis. She was 12 days old at the time of the first supraglottoplasty and she had a nasogastric feeding tube and intractable vomiting for several weeks. Additionally, she was underweight and was found to have chromosomal duplication.

Previous reports on surgical techniques to treat supraglottic stenosis are limited to case reports and very small case series. The choice of the surgical technique depended on several factors, such as aetiology, severity, patient age and surgeon's experience. Endoscopic, open and combined techniques were described.[2] Most reports discussing the endoscopic management of post-supraglottoplasty supraglottic stenosis mention scar division or excision, without reported attention to preserving the mucosal cover.[1] When possible, it is preferrable to attempt endoscopic techniques with minimal or no mucosal resection.

To our knowledge, only one group described a mucosa-sparing, endoscopic technique to treat post-supraglottoplasty supraglottic stenosis in children.[2,4] All five infants (age range two to six months) had cicatricial shortening of the aryepiglottic that which was divided using carbon dioxide (CO_2) laser. Bilateral mucosal rotation flaps were developed from the pyriform sinus mucosa and sutured over the divided aryepiglottic folds. Epiglottopexy was also performed.

Z-plasty is a widely used technique in cutaneous scar revision. Endoscopic Z-plasty for the treatment of supraglottic stenosis was first reported by Yilmaz, who used this technique in nine adult patients with supraglottic stenosis.[3] All patients had supraglottic stenosis that resulted from partial laryngectomy, surgery for bilateral vocal fold paralysis, trauma or systemic lupus erythematosus. The technique involves using a CO_2 laser to make Z-plasty incisions in the stenotic segment, followed by submucosal removal of scar and approximation of mucosal flaps using Vicryl sutures.

We present a novel endoscopic mucosa-sparing technique with good outcomes. To our knowledge, our report is the first to describe endoscopic Z-plasty in the treatment of paediatric post-supraglottoplasty supraglottic stenosis. Z-plasty allows releasing scar contracture and lengthening of scar. This was the rationale behind using this technique to address the interarytenoid scar.

Unlike most previous reports, we used cold-steel instruments to create the mucosal cuts and to excise scar tissue, which offers several advantages over a laser. Firstly, it allows total mucosal preservation, in contrast to the laser, which is likely to cause some mucosal loss by direct vaporisation and/or heat injury, even when attempting to create precise cuts. This is particularly important given the small size of the infant larynx. Secondly, cold-steel instruments can be more precise when creating cuts and elevating mucosal flaps. Thirdly, the resulting oedema is minimal. Fourthly, no particular equipment or precautions are needed, which saves time and cost, unlike with a laser. Lastly, the use of microlaryngeal scissors can ensure healthy mucosal edges for suturing and appropriate healing. In our case, very minimal bleeding from mucosal edges was easily controlled with topical diluted epinephrine.

Scar excision was carried out judiciously to avoid creating a laryngeal cleft and causing aspiration. Because mucosa is spared, this procedure can be repeated with additional scar removal if symptomatic stenosis recurs. Of note, it is important to rule out posterior glottic stenosis with a careful palpation and assessment of arytenoid mobility.

Our technique was performed with the patient breathing spontaneously. Intubation was not required by virtue of optimal communication with an experienced paediatric aesthesia team. The tubeless technique provides a wide field for visualisation and instrumentation, which is of utmost importance when working on the infant larynx with two instruments. Intubation, even when brief and

https://doi.org/10.1017/S0022215124000926 Published online by Cambridge University Press

intermittent, would reduce efficiency and may affect the sutures. We used PDS, which is a reliable suture material that is smooth and easy to handle.

We avoided tracheostomy, and the patient was asymptomatic few hours after the procedure and was discharged on post-operative day 1. She continued to be free of any airway symptoms on the most recent follow up, 10 months post-operative.

- Supraglottic stenosis is a rare and difficult to manage complication of supraglottoplasty
- Endoscopic repair is preferable over open techniques or tracheostomy
- This study reports a novel endoscopic mucosa-sparing Z-plasty technique that was used to manage supraglottic stenosis following supraglottoplasty in an infant
- The described technique allows a mucosa-sparing resection of the scar with low risk of stenosis

The risk of supraglottic stenosis can be reduced by careful and judicious mucosal excision during supraglottoplasty. Nevertheless, other potential contributing factors, such as frequent vomiting, gastroesophageal reflux, presence of a nasogastric tube and age, warrant attention and further investigation.

Conclusion

Endoscopic interarytenoid Z-plasty can be considered in the management of paediatric supraglottic stenosis. This technique is safe and effective, and can help avoid tracheostomy.

Supplementary material. The supplementary material for this article can be found at https://doi.org/10.1017/S0022215124000926.

Competing interests. None declared

References

1 Denoyelle F, Mondain M, Gresillon N, Roger G, Chaudre F, Garabedian EN. Failures and complications of supraglottoplasty in children. *Arch Otolaryngol Head Neck Surg* 2003;**129**:1077–80
2 Colliard A, Ishii A, De Sandre C, Gorostidi F, Sandu K. Decoding supraglottic stenosis. *Eur Arch Otorhinolaryngol* 2020;**277**:293–300
3 Yılmaz T. Endoscopic Z-plasty for treatment of supraglottic stenosis: experience on nine patients. *Laryngoscope* 2021;**131**:E534–9
4 Sandu K, Perez MH, Longchamp D, Chollet M, Gorostidi F. Endoscopic treatment of post-supraglottoplasty stenosis. *Clin Otolaryngol* 2018;**43**:1640–3
5 Avillion MP, Neighbors CLP, Biello A, Anderson LC, Liming BJ, Camacho M. Unilateral vs bilateral supraglottoplasty: a meta-analysis of rates of return to surgery and supraglottic stenosis. *Otolaryngol Head Neck Surg* 2019;**161**:742–53