


Makiko Nishioka<sup>1</sup> , Kenji Hoshino<sup>1</sup> and Shinya Ugaki<sup>2</sup>

## Brief Report

**Cite this article:** Nishioka M, Hoshino K, and Ugaki S (2023) Late bacterial endocarditis after percutaneous atrial septal defect closure. *Cardiology in the Young* **33**: 138–140. doi: [10.1017/S1047951122001366](https://doi.org/10.1017/S1047951122001366)

Received: 21 February 2022  
Accepted: 7 April 2022  
First published online: 28 April 2022

**Keywords:**

Infective endocarditis; methicillin-resistant *Staphylococcus aureus*; atrial septal defect; Figulla Flex II Occluder; endothelialisation

**Author for correspondence:** Makiko Nishioka, Department of Pediatric Cardiology, Saitama Children's Medical Center, 1-2, Shintoshin, Chuo-ku, Saitama-shi, Saitama, 330-8777, Japan. Tel: +81-48-601-2200. E-mail: [nishioka.makiko@saitama-pho.jp](mailto:nishioka.makiko@saitama-pho.jp)

<sup>1</sup>Department of Pediatric Cardiology, Saitama Children's Medical Center, Saitama 330-8777, Japan and <sup>2</sup>Department of Pediatric Cardiovascular Surgery, Saitama Children's Medical Center, Saitama 330-8777, Japan

**Abstract**

Percutaneous atrial septal defect closure is widely used as an alternative to surgical repair in many hospitals. Infective endocarditis related to occluding devices is commonly known, but following that atrial septal defect closure with a device in a child is rare. This report describes an 11-year-old girl who developed late-stage bacterial endocarditis following incomplete endothelialisation after a percutaneous procedure.

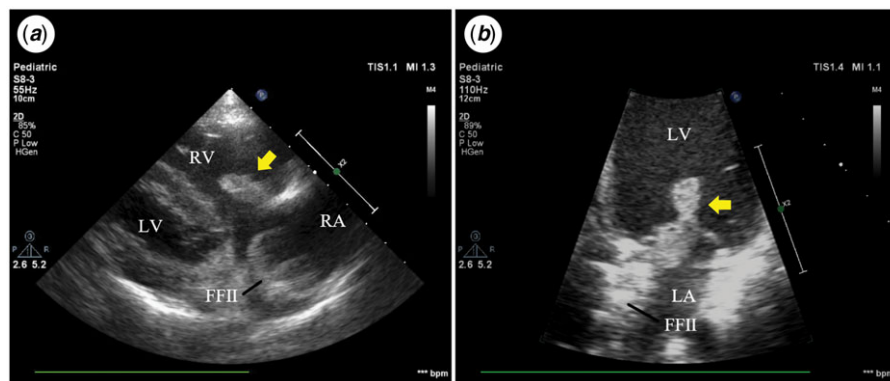
The Occlutech Figulla Flex II (FFII) Occluder (Occlutech GmbH, Jena, Germany) is a commonly used percutaneous transcatheter device for closing atrial septal defects. As percutaneous device closure is a less invasive alternative to surgical repair, it has been commonly used for anatomically suitable atrial septal defects in recent years. The success rates of the percutaneous approach are comparable to that of the surgical approach for atrial septal defects anatomically suitable for this procedure.<sup>1</sup> Many patients do not experience severe complications following percutaneous treatment. Infective endocarditis is a relatively rare but very severe complication associated with atrial septal defects closure devices.<sup>2</sup> Despite advances in diagnostic and therapeutic techniques, morbidity and mortality rates in IE cases remain high. Therefore, the current guidelines recommend 6 months of antibiotic prophylaxis after device implantation, based on animal study results.<sup>3</sup> In particular, IE following atrial septal defect closure with an occluding device in a child is rare. We report a case of late bacterial endocarditis in an 11-year-old girl with incomplete endothelialisation after percutaneous device closure of atrial septal defects.

An 11-year-old girl with a secundum atrial septal defect (17.7 mm) underwent percutaneous repair with a 21-mm FFII occluder device in July 2017. She presented with a 2-week history of persistent fever, ankle pain, and coxalgia in June 2021. Additionally, she developed mucosal bleeding from the palpebral conjunctiva and oral mucosa, Janeway lesion, and Osler's node. She had no notable medical history except for the treatment of atrial septal defects. Her vital signs were stable, except for the body temperature (40°C). She did not experience septic shock. While she had not received dental treatment, she had lost her deciduous tooth 1 month before presentation. Sepsis was not clearly associated with the loss of the deciduous tooth. Laboratory results indicated bacterial infection but no signs of pancytopenia, abnormal blood clotting, and multiple organ failure. Blood culture revealed methicillin-resistant *Staphylococcus aureus*. Cardiomegaly and lung consolidation were barely noticeable on chest radiography. Electrocardiogram findings were normal. Fundoscopy revealed the presence of Roth spots in both eyes. Transthoracic echocardiography revealed large hypermobile masses on her tricuspid and mitral valves. The mass on the tricuspid valve and on the mitral valve was 18 mm and 17 mm, respectively (Fig 1). No residual atrial septal defect shunt, valve regurgitation, and destruction were observed. Because several cerebral microemboli were already detected on brain magnetic resonance imaging during hospitalisation, we decided to perform an urgent surgery to resect the vegetations and infected device, followed by patch closure for the atrial septal defect using fresh pericardium. During surgery, we found that neo-endothelialisation of the occluder device was partially insufficient (especially at the hub) and that the metallic mesh was exposed (Fig 2), although adhesions around the disc rim were very strong. The vegetation extended to the surface of the disc. Postoperatively, the first-degree atrioventricular block persisted for several weeks. However, sinus rhythm recovered spontaneously. She received approximately 6 weeks of vancomycin therapy (10–30 mg/kg/day) after blood culture was negative for infection, followed by 5 months of Bactrim (sulfamethoxazole and trimethoprim) at 10 mg/kg/day. We temporarily substituted vancomycin for daptomycin for 1 week because of drug-associated granulocytopenia and drug eruption. She was discharged without any neurological deficits due to effective exercise therapy. At the most recent follow-up echocardiography, we observed mild tricuspid regurgitation, no mitral regurgitation, and normal cardiac function.

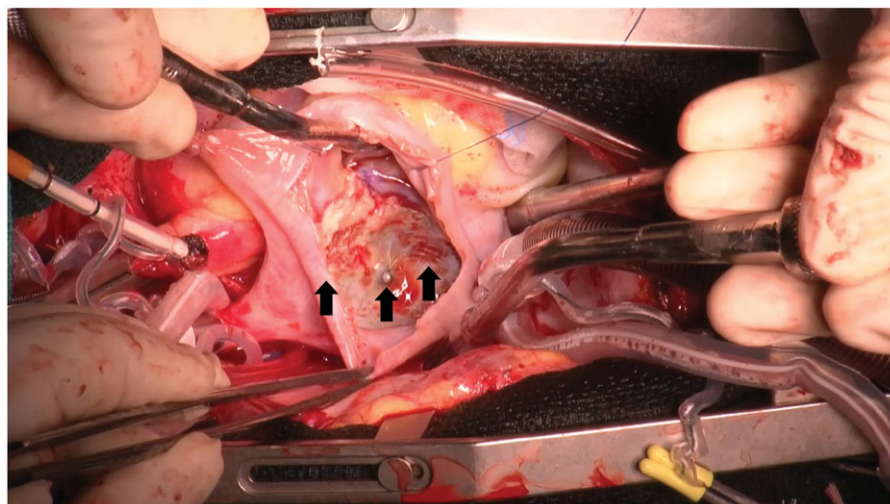
In many cases, transcatheter repair of atrial septal defect is safe, non-invasive, and effective. Percutaneous closure of atrial septal defect has been reported since the 1970s.<sup>4</sup> Compared with the early counterparts, current occlusion devices have improved markedly; therefore, percutaneous device closure is performed widely instead of surgical repair in many hospitals.

**Figure 1.** Transthoracic echocardiography images at hospitalisation. Large vegetations are on the tricuspid and mitral valve (arrows). They are hypermobile and extended to the occluding device.

RA = right atrium, LA = left atrium, RV = right ventricle, LV = left ventricle, FFII = The Occlutech Figulla Flex II.



**Figure 2.** Neo-endothelialisation of the occluder device is partially insufficient, and the metallic mesh is exposed (arrows), although the very strong adhesion around the disc rims.



The percutaneous approach is not complicated. Device malposition, fracture, atrio-aortic erosion, residual shunt, cardiac arrhythmias, cardiac tamponade, valve regurgitation, thrombosis, and infective endocarditis is the known significant complications of occluding device deployment. However, the incidence of late infective endocarditis is significantly low. The European Society of Cardiology, American College of Cardiology, and American Heart Association recommend 6 months of antibiotic prophylaxis following percutaneous device closure of atrial septal defects, as devices for atrial septal defects are fully endothelialised within 1–3 months after deployment in several animal studies.<sup>5,6</sup> However, the same may not be applicable to humans. It is unclear whether complete endothelialisation occurs within 6 months in humans after deployment of closure devices for atrial septal defects. Insufficient endothelialisation of the disc may increase the risk of infective endocarditis. Some cases of late infective endocarditis associated with closure devices for atrial septal defects involved implanted devices that were not completely endothelialised, although over 6 months had elapsed since deployment.<sup>7–9</sup> Tanabe et al. reported neo-endothelialisation in humans in vivo. They evaluated neo-endothelialisation on the surface of discs with angioscopy 6 months after device implantation.<sup>10</sup> They described that the neo-endothelialisation of the devices varied among the study patients and that the patients treated with a large device might show poor endothelialisation. Moreover, the endothelialisation of the central areas was insufficient. They considered that incomplete endothelialisation was related to the device size, right ventricular systolic pressure, and enlargement of the right ventricle

volume overload.<sup>10</sup> The period until complete endothelialisation in humans may differ substantially among individuals. The current guidelines are primarily focused on appropriate antibiotic prophylaxis for infective endocarditis. Our report suggests that clinicians should decide the need for prolonged antibiotic administration after large occluder device deployment flexibly to prevent severe complications, such as late infective endocarditis.

**Acknowledgements.** We thank the members of the cardiac team and the infection control team for their attentive medical care.

**Financial support.** This research received no specific grant from any funding agency, commercial, or not-for-profit sectors.

**Conflicts of interest.** The authors declare that they have no competing interests.

**Patient consent.** The patient's mother provided written consent for the publication of this case report.

**Social media synopsis.** We report a rare case of late bacterial endocarditis in an 11-year-old girl with incomplete endothelialisation after percutaneous device closure of ASD.

## References

1. Du ZD, Hijazi ZM, Kleinman CS, Silverman NH, Larntz K. Comparison between transcatheter and surgical closure of secundum atrial septal defect in children and adults: Results of a multicenter nonrandomized trial. *J Am Coll Cardiol* 2002; 39: 1836–1844.

2. Masura J, Gavora P, Podnar T. Long-term outcome of transcatheter secundum-type atrial septal defect closure using Amplatzer septal occluders. *J Am Coll Cardiol* 2005; 45: 505–507.
3. Walter W, Taubert KA, Gewitz M. AHA Guideline Prevention of Infective Endocarditis Guidelines From the American Heart Association: a Guideline from the American Heart Association Rheumatic Fever, Endocarditis, and Kawasaki Disease Committee, Council on Cardiovascular Disease in the Young, and the Council on Clinical Cardiology, Council on Cardiovascular Surgery and Anesthesia, and the Quality of Care and Outcomes Research Interdisciplinary Working Group. *Circulation* 2007; 116: 1736–1754.
4. King TD, Thompson SL, Steiner C, Mills NL. Secundum atrial septal defect: nonoperative closure during cardiac catheterization. *JAMA J Am Med Assoc* 1976; 235: 2506–2509.
5. Sharafuddin MJA, Gu X, Titus JL, Urness M, Cervera-Ceballos JJ, Amplatz K. Transvenous closure of secundum atrial septal defects: Preliminary results with a new self-expanding nitinol prosthesis in a swine model. *Circulation* 1997; 95: 2162–2168.
6. Lock JE, Rome JJ, Davis R, et al. Transcatheter closure of atrial septal defects. Experimental studies. *Circulation* 1989; 79: 1091–1099.
7. Amedro P, Soulatges C, Fraisse A. Infective endocarditis after device closure of atrial septal defects: Case report and review of the literature. *Catheter Cardiovasc Interv* 2017; 89: 324–334.
8. Zahr F, Katz WE, Toyoda Y, Anderson WD. Late bacterial endocarditis of an amplatzer atrial septal defect occluder device. *Am J Cardiol* 2010; 105: 279–280.
9. Jha NK, Kiraly L, Murala JSK. Late endocarditis of Amplatzer atrial septal occluder device in a child. *World J Cardiol* 2015; 7: 703–706.
10. Tanabe Y, Suzuki T, Kuwata S, et al. Angioscopic evaluation of atrial septal defect closure device neo-endothelialization. *J Am Heart Assoc* 2021; 10: e019282.