

# Vasculitic Basilar Artery Thrombosis in Chronic *Candida Albicans* Meningitis

D.A. Grimes, B. Lach and P.R. Bourque

**ABSTRACT: Background:** Cerebrovascular complications of meningitis have been most extensively documented in the setting of acute bacterial or chronic tuberculous meningitis. Involvement of major cerebral vessels is rare and basilar artery thrombosis has not been reported in fungal meningitis secondary to candida infection. **Methods:** We describe the clinical course and neuropathological findings in a woman with chronic meningitis due to *Candida albicans*. **Results:** The diagnosis remained elusive antemortem despite analysis of 7 large volume CSF samples and examination of a meningeal and cortical biopsy. Death followed extensive brainstem and temporo-occipital infarction secondary to basilar artery thrombosis. The basilar artery occlusion was secondary to an intense, granulomatous and necrotizing basal meningitis focally extending to the media and intima. **Conclusions:** This paroxysmal and devastating complication of untreated chronic candida meningitis reinforces that a trial of empirical therapy with both antituberculous and antifungal agents should be considered in most cases of chronic culture-negative lymphocytic meningitis.

**RÉSUMÉ: Thrombose de l'artère basilaire due à une vasculite dans la méningite chronique à *Candida albicans*.**

**Introduction:** Les complications vasculaires cérébrales de la méningite ont été documentées exhaustivement dans le cadre des méningites bactériennes aiguës ou de la méningite tuberculeuse chronique. Les gros vaisseaux cérébraux sont rarement impliqués et la thrombose de l'artère basilaire n'a jamais été rapportée dans la méningite mycotique secondaire à une infection à candida. **Méthodes:** Nous décrivons l'évolution clinique et les constatations neuropathologiques chez une femme atteinte de méningite chronique à *Candida albicans*. **Résultats:** Le diagnostic nous a échappé pendant le suivi de la patiente, en dépit de l'analyse de 7 échantillons de LCR et de l'examen de biopsies des méninges et du cortex. Un infarctus massif du tronc cérébral et de la région temporo-occipitale secondaire à une thrombose de l'artère basilaire a causé le décès de la patiente. L'occlusion de l'artère basilaire était secondaire à une méningite intense de la base, qui était nécrosante et granulomateuse, et s'étendait focalement à la média et à l'intima. **Conclusion:** Cette complication abrupte et dévastatrice d'une méningite chronique à candida non traitée souligne la recommandation qu'un essai thérapeutique empirique au moyen d'agents antituberculeux et antifongiques devrait être considéré dans la majorité des cas de méningite lymphocytaire chronique avec culture négative.

Can. J. Neurol. Sci. 1998; 25: 76-78

Cerebrovascular complications of meningitis include infarction from arterial or venous thrombosis, vasculitis, vasospasm and formation of arterial aneurysms, sometimes with subarachnoid hemorrhage. These adverse outcomes have been most extensively documented in the setting of acute bacterial or chronic tuberculous meningitis. In cases of central nervous system (CNS) candidiasis, arterial wall fungal invasion and vasculitis have been reported in small and intermediate diameter cerebral vessels.<sup>1-3</sup> However, clinically evident thrombosis of a major cerebral artery has not yet been documented.

We describe a case of paroxysmal vasculitic basilar artery thrombosis in a patient with untreated chronic meningitis due to *Candida albicans*. This case illustrates dramatically the diagnostic challenge of chronic lymphocytic meningitis and the potential risks of empirical therapy with steroid medications.

## CASE REPORT

A 37-year-old woman was admitted to our institution with a 3 week history of increasing headache, nausea, vomiting and confusion.

She had a past history of non-insulin dependent diabetes mellitus, abdominal hysterectomy and uncomplicated atrial septal repair at age 23. There was no history of neurological disease, head trauma or travel. In the previous three years, she had been closely followed at another institution for recurrent subcutaneous abscesses involving the abdominal wall, thigh and upper arm. On multiple biopsies, these abscesses were shown to involve the subcutaneous adipose tissue with cultures positive for fecal organisms. Some of the blood cultures were positive for *E Coli* and enterococci. Investigations for an underlying immunodeficiency yielded negative or normal results, including HIV serology, lymphocyte immunophenotyping and tests of neutrophil function. Infectious disease and dermatology consultants involved in her care suspected factitious panniculitis. Treatment consisted of debridement and prolonged courses of oral and intravenous antibiotics. One year prior to her presentation, a hickman catheter was used over a period of several months because of difficulties with peripheral venous access. In

From the Division of Neurology, Division of Pathology and Laboratory Medicine, University of Ottawa, Ottawa Civic Hospital, Ottawa.

RECEIVED JUNE 19, 1997. ACCEPTED IN FINAL FORM AUGUST 26, 1997.

Reprint requests to: Pierre Bourque, University of Ottawa, Ottawa Civic Hospital, 1053 Carling Avenue, D715, Neurology Division, Ottawa, Ontario, Canada K1Y 4E9

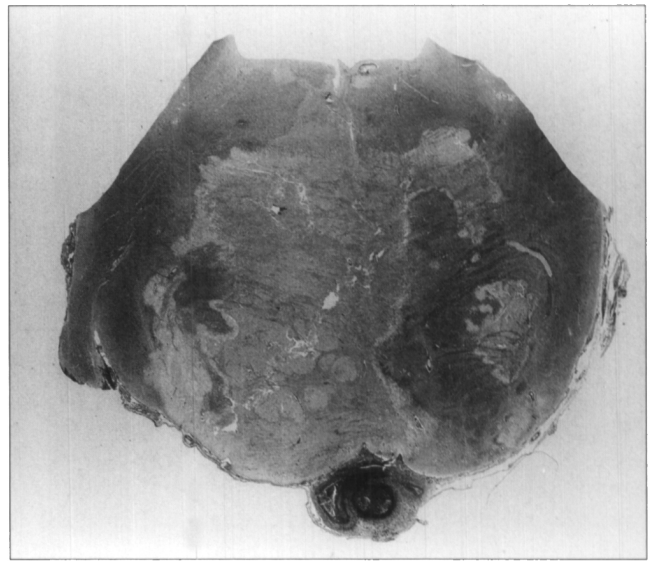
the months preceding her presentation it had been removed, but she continued to take courses of oral antibiotics for recurrent subcutaneous abscesses.

The initial physical examination revealed an obese woman in moderate distress from headache. She was afebrile, although subsequently a low grade fever was noted. There were healed scars over the upper arms, thighs and abdomen. Two ulcerated lesions over the lower abdomen were oozing a yellowish serous discharge. The neurologic examination was normal except for mild nuchal rigidity.

Investigations during her stay showed peripheral white cell counts ranging from 6 to 14 x 10<sup>9</sup>/l, sodium from 132 to 140 mmol/l and glucose from 3.7 to 14 mmol/l. Repeated HIV serologies were negative. ANA, rheumatoid factor, serum angiotensin converting enzyme, liver and renal function tests were normal. Repeated blood cultures for bacteria and fungi were negative. Chest radiographs, abdominal ultrasound and transthoracic echocardiogram were normal. Computed tomography of the brain showed mild hydrocephalus and MRI with gadolinium revealed mild basal meningeal enhancement. Seven lumbar punctures over a period of 6 weeks revealed the following cerebrospinal fluid (CSF) results: white blood cell count 275-500 x 10<sup>6</sup>/l, with an average of 78% mononuclear cells; protein 3.5-6.0 g/l; CSF/serum glucose ratio 36-56%. On the third CSF specimen, a questionable light growth of *Candida albicans* was noted but discounted as a possible contamination, as all other fungal smears and cultures were negative. Latex agglutination for cryptococcal antigen, smear and culture for mycobacteria, assays for syphilis and Lyme, and all cytological examinations were negative. On day 10, a right temporal meningeal and cortical biopsy was done because of increasing headache and confusion. Microscopy revealed a non-specific chronic leptomeningitis. With an auramine rhodamine stain of a meningeal biopsy specimen, eight atypical acid-fast bacilli were noted, raising the possibility of tuberculosis, although subsequent specific mycobacteria stains and long term culture were negative.

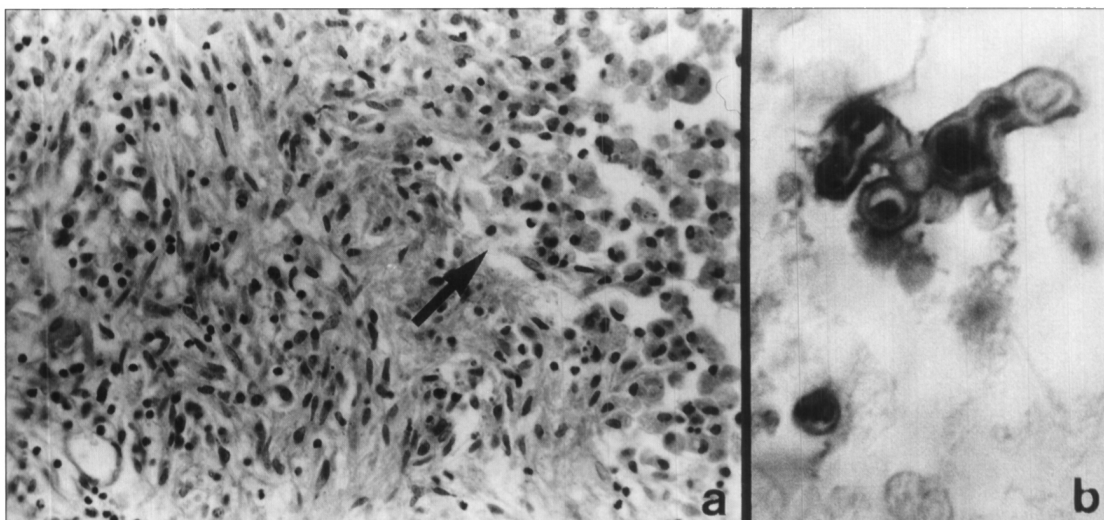
The patient received empirical quadruple antituberculous chemotherapy. She complained of fluctuating, at times severe headache. Episodic confusion seemed to parallel the use of narcotic analgesic medication. On day 51 steroids were added to her treatment, and initially seemed to alleviate symptoms. On day 62 she abruptly became comatose with decerebrate posturing, generalized myoclonus and down-beating nystagmus. A CT scan revealed acute infarction of the ventral midbrain, pons and left occipital lobe. She was started on amphotericin but died seven days later.

Consent was given for autopsy of the brain only. There was an intense chronic basal meningitis with thrombotic occlusion of the basilar artery accompanied by recent large infarction in the pons (Figure 1). The inflammatory infiltrations consisted of lymphocytes, plasma cells,



**Figure 1:** Whole mount of the pons showing thrombosis of basilar artery and massive infarct. Note the thick inflammatory infiltrate in the leptomeninges. (Luxol-fast blue stain combined with periodic acid Schiff reaction.)

macrophages, epithelioid cells, and a few multinucleated giant cells (Figure 2a). Central areas of necrosis were often surrounded by a significant admixture of polymorphs. There was only slight leptomeningeal inflammation over the cerebral convexities. Gram, Ziehl Nielsen and fluorescent TB stains were negative. Periodic acid Schiff reaction and Grocott silver stains for fungi revealed a few septated hyphae and a colony of oval budding yeast-like structures in the necrotic center of several granulomas. These organisms showed positive immunoperoxidase staining using anti-*Candida albicans* polyclonal antibodies (dilution 1:2000, Dako, Santa Barbara, USA) (Figure 2b). The meningeal inflammation focally involved the wall of the basilar artery, extending through the internal elastic lamina to the subendothelium. The basilar artery as well as some of its paramedian and circumferential arteries were occluded by a recent, organizing and partly recanalized thrombus. Additional multifocal recent infarctions were present in the left temporal and occipital lobes, left thalamus and midbrain.



**Figure 2:** a) Low power view of necrotizing granuloma in the basal meninges. The arrow points to a central area of necrosis filled with macrophages. (H&E stain. Magn. 385X). b) Small colony of *Candida albicans* in the necrotic center of meningeal granuloma. (Peroxidase - antiperoxidase method, polyclonal Dako antibodies 1:2000, Magn. approx. 2500x, 1cm = 4 μm).

## DISCUSSION

Although *Cryptococcus neoformans* is still the leading cause of CNS fungal infection,<sup>4</sup> *Candida albicans* has been the most frequently implicated organism in autopsy series as it is often diagnosed just before death or at postmortem.<sup>5</sup> The commonest manifestation of CNS candidiasis is the formation of scattered cerebral microabscesses with acute meningitis in the context of disseminated disease. Isolated chronic candida meningitis is distinctly uncommon, with only 18 cases cited in a recent review.<sup>6</sup> The overall mortality of 53% remains as high as 33% in patients who are correctly diagnosed and treated. As with tuberculous and other fungal meningitides, the CSF reveals a mononuclear pleocytosis (although a neutrophilic predominance can be seen) with elevated protein and low glucose. CSF smears reveal the organism in less than half of cases while cultures are positive in at least 70%, particularly if large volumes are cultured in a hypertonic medium or if a centrifuged sample is filtrated and the filter subsequently cultured. Meningeal biopsy is usually unhelpful as it will reveal leptomeningeal inflammation but only rarely permits the identification of the offending organism. In the present case, the actual number of candida yeasts and hyphae seen at autopsy seemed remarkably small in relation to the intensity of the inflammatory meningeal reaction, in contrast to previous cases where the fungus was much more prevalent.<sup>1-3,7</sup>

Inflammatory thrombosis of large diameter cerebral arteries has been described in the setting of bacterial and tuberculous meningitis. Perry et al. reported a case of *Streptococcus milleri* meningitis with initial ischemic pontine infarction followed by fatal subarachnoid hemorrhage.<sup>8</sup> At autopsy, the basilar artery was filled with an organized thrombus and inflammatory necrosis of its wall had led to the formation of an aneurysm. In candida meningitis, granulomatous vascular inflammation or frank fungal invasion have been mainly described in relation to small or intermediate diameter arteries.<sup>1-3</sup> Edelson documented involvement of major branches of the posterior circulation, including the basilar, although without thrombosis or secondary infarction.<sup>7</sup>

This case strongly underlines the danger of empirical steroid treatment in patients with "idiopathic" chronic lymphocytic meningitis. A report from New Zealand has described a subgroup of previously healthy subjects with uniquely steroid-responsive chronic meningitis.<sup>9</sup> These patients had negative fungal cultures for at least four weeks and had failed to respond

to antituberculous medication. The authors suggested that a trial of steroids could be considered under close observation, with the addition of antifungal therapy if any deterioration occurred. In our case there was no antecedent transient focal neurological deficit, nor was the brainstem stroke heralded by an exacerbation of headache or signs of meningeal irritation. Admittedly, our patient was at risk for fungal infection given her history of diabetes and prolonged use of antibiotics. Further, because of its low diagnostic yield, a negative meningeal biopsy does not exclude fungal infection.

This case highlights the diagnostic challenge and potential devastating consequences of the syndrome of chronic lymphocytic meningitis. With a low prevalence rate of tuberculosis and increasing number of immunocompromised hosts, fungal meningitis is likely to increase in relative importance in developed countries. Tuberculous meningitis is readily suspected and, pending isolation or culture, empirical therapy can be safely administered in equivocal cases. In contrast, empirical use of amphotericin means a long term commitment to a potentially toxic drug, with the additional complications inherent to prolonged intravenous access. The advent of oral antifungal agents such as fluconazole will likely influence treatment algorithms, as shown for cryptococcal meningitis.<sup>10</sup>

## REFERENCES

1. Miale JB. *Candida albicans* infection confused with tuberculosis. Arch Pathol 1943; 35: 427-437.
2. Eschwege J. Generalized moniliasis with localization in the brain. Arch Neurol Psychol 1958; 79: 250.
3. Feigin I, Prose P. Some uncommon forms of cerebral vascular disease. J Mt Sinai Hosp 1957; 24: 838.
4. Treseler CB, Sugar AM. Fungal meningitis. Infect Dis Clin North Am 1990; 4: 789-808.
5. Parker JC Jr, McCloskey JJ, Lee RS. The emergence of candidosis: the dominant postmortem cerebral mycosis. Am J Clin Pathol 1978; 70: 31-36.
6. Voice RA, Bradley SF, Sangeorzan JA, Kauffman CA. Chronic candida meningitis: an uncommon manifestation of candidiasis. Clin Inf Dis 1994; 19: 60-66.
7. Edelson RN, McNatt EN, Porro RS. Candida meningitis with cerebral arteritis. N Y State J Med 1975; 75: 900-904.
8. Perry JR, Bilbao JM, Gray T. Fatal basilar vasculopathy complicating bacterial meningitis. Stroke 1992; 23: 1175-1178.
9. Anderson NE, Willoughby EW. Chronic meningitis without predisposing illness – a review of 83 cases. Q J Med 1987; 63: 283-295.
10. Saag MS, Powderly WG, Cloud GA, et al. Comparison of amphotericin B with fluconazole in the treatment of acute AIDS-associated cryptococcal meningitis. N Engl J Med 1992; 326: 83-89.