


Neuroimaging Highlight

Sports-Induced Upper Cervical Posterior Spinal Artery Syndrome Due to Vertebral Artery Dissection

Di Wu, Qian Sun, Jing Zhao and Lan Zheng 

Department of Neurology, Minhang Hospital, Fudan University, Shanghai, China

Keywords: posterior spinal artery syndrome; vertebral artery dissection

(Received 21 February 2025; date of acceptance 2 March 2025)

A 31-year-old man with no prior medical history presented to the emergency department with sudden-onset right-sided limb numbness and weakness accompanied by severe neck pain after prolonged rope skipping. He denied any history of trauma, neck manipulation or recent infections. He was a nonsmoker, did not consume alcohol and denied drug use. On admission, his blood pressure was 200/110 mmHg. Neurological examination revealed right-sided Horner's syndrome, ipsilateral reduced superficial sensation, C2 anesthesia, muscle weakness (grade 3/5), proprioceptive impairment and hyperpathia affecting the trunk and limbs. The deep tendon reflexes were hypoactive on the right side, and Babinski's sign was negative. The patient did not report urinary retention or constipation.

Acute ischemic stroke was suspected, and a non-contrast CT scan of the head was unremarkable. All hematological examinations were also unremarkable. CT angiography of the head and cervical region revealed diffuse thinning of the right vertebral artery. A brain MRI demonstrated abnormal diffusion-weighted imaging and T2-weighted imaging hyperintensity in the right posterolateral lower medulla oblongata, indicative of spinal cord infarction (SCI) in the posterior spinal artery (PSA) territory. A cervical spine MRI confirmed infarction extending from the right lower medulla oblongata to the upper cervical spinal cord at the C2 level (Figure 1A), supporting the diagnosis of unilateral posterior spinal artery syndrome (PSAS). High-resolution MRI further identified an intramural hematoma in the right vertebral artery at the V3 segment (Figure 1B), consistent with vertebral artery dissection (VAD). Following antiplatelet therapy and rehabilitation, the patient demonstrated significant neurological improvement.

PSAS is a rare form of SCI, with an incidence significantly lower than that of cerebral ischemic stroke.^{1,2} It was first described in 1895 when Williamson identified ischemia in the PSA territory as a cause of myelopathy.³ Clinically, PSAS is characterized by limb paralysis, impairment of superficial and proprioceptive sensation and potential urinary or bowel dysfunction, with MRI findings

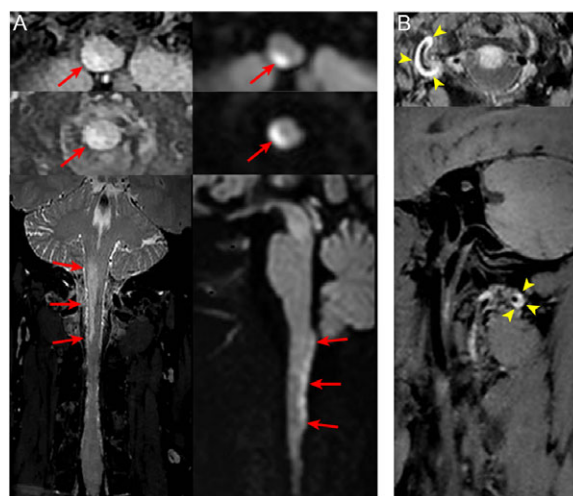


Figure 1. (A) T2-weighted and diffusion-weighted magnetic resonance imaging (MRI) showed long segment hyperintense signal lesions from the right lower medulla oblongata to the upper cervical spinal cord at the C2 level (red arrow). (B) High-resolution MRI showed intramural hematoma in the right vertebral artery at V3 segment, indicative of vertebral artery dissection (VAD) (yellow arrowhead).

typically revealing lesions in the dorsal columns, dorsal horns and posterior spinal cord.⁴

Upper cervical PSAS is particularly uncommon, with only 23 cases reported over the past 40 years, including the present case. The primary etiologies of upper cervical PSAS include VAD, atherosclerosis, iatrogenic causes and trauma.^{4,5} Among the 23 cases, VAD accounted for 13 patients, with a median age of 34.5 years (Supplementary table). Unlike atherosclerosis, which is more common in the elderly, VAD is a leading cause of PSAS in younger individuals.^{2,6} VAD itself is an uncommon etiology of ischemic stroke and can be triggered by high-impact trauma to the head or neck or by extreme neck movements, such as

Corresponding author: Lan Zheng; Email: zhenglan1323@163.com

Cite this article: Wu D, Sun Q, Zhao J, and Zheng L. Sports-Induced Upper Cervical Posterior Spinal Artery Syndrome Due to Vertebral Artery Dissection. *The Canadian Journal of Neurological Sciences*, <https://doi.org/10.1017/cjn.2025.47>

© The Author(s), 2025. Published by Cambridge University Press on behalf of Canadian Neurological Sciences Federation. This is an Open Access article, distributed under the terms of the Creative Commons Attribution licence (<https://creativecommons.org/licenses/by/4.0/>), which permits unrestricted re-use, distribution and reproduction, provided the original article is properly cited.

hyperextension or rotation.⁷⁻⁹ High-intensity sports are a recognized risk factor for VAD, particularly in young adults.¹⁰

This case provides representative neuroimaging findings of a rare condition, contributing to educational purpose. Furthermore, in young patients without conventional risk factors who present with acute ischemic stroke symptoms, particularly when accompanied by severe neck pain, arterial dissection should be considered as a potential cause. For patients diagnosed with PSAS, high-resolution MRI is essential to identify the underlying pathology and guide appropriate management.

Supplementary material. The supplementary material for this article can be found at <https://doi.org/10.1017/cjn.2025.47>.

Author contributions. Di Wu performed a literature review, collate the information of the patient and drafted the manuscript; Qian Sun cared for the patient, collate the neuroimages of the patient and critically reviewed the manuscript; Jing Zhao cared for the patient and critically revised the manuscript; and Lan Zheng conceptualized and supervised the work, cared for the patient and critically revised the manuscript.

Funding statement. This research was funded by the grant number 2022MHPY02 from Minhang Hospital, Fudan University.

Competing interests. The authors do not have any conflicts of interest to disclose.

Ethical statement. This study was approved by the Ethical Review Board of Minhang Hospital of Fudan University.

Statements and declarations. The manuscript has not been published elsewhere and is not under consideration by any other journal. All authors have approved the manuscript.

References

1. Panesar H, Conry A, Finocchi V, Desai C, Bracewell RM. Posterior spinal artery infarct. *Pract Neurol*. 2023;23:160–163. doi: [10.1136/practneurol-2021-003336](https://doi.org/10.1136/practneurol-2021-003336).
2. Jiang Q, Tian D, Jing J. Posterior unilateral spinal cord infarction caused by vertebral artery dissection. *Ann Neurol*. 2023;94:871–872. doi: [10.1002/ana.26767](https://doi.org/10.1002/ana.26767).
3. W. RT. Spinal softening limited to the parts supplied by the posterior arterial system of the cord. *Lancet*. 1895;2:520–521. doi: [10.1016/S0140-6736\(01\)13516-6](https://doi.org/10.1016/S0140-6736(01)13516-6).
4. Chen F, Liu X, Qiu T, et al. Cervical Posterior Spinal Artery Syndrome Caused By Spontaneous Vertebral Artery Dissection: Two Case Reports and Literature Review. *J Stroke Cerebrovasc Dis*. 2020;29:104601. doi: [10.1016/j.jstrokecerebrovasdis.2019.104601](https://doi.org/10.1016/j.jstrokecerebrovasdis.2019.104601).
5. Matsubayashi J, Tsuchiya K, Shimizu S, et al. Posterior spinal artery syndrome showing marked swelling of the spinal cord: a clinico-pathological study. *J Spinal Cord Med*. 2013;36:31–35. doi: [10.1179/2045772312Y.0000000017](https://doi.org/10.1179/2045772312Y.0000000017).
6. Ouyang F, Li J, Zeng H, Wang M, Fan Y. Unilateral upper cervical posterior spinal cord infarction caused by spontaneous bilateral vertebral artery dissection. *Neurology*. 2022;99:473–474. doi: [10.1212/WNL.000000000201062](https://doi.org/10.1212/WNL.000000000201062).
7. Saw AE, McIntosh AS, Kountouris A, Newman P, Gaida JE. Vertebral artery dissection in sport: a systematic review. *Sports Med*. 2019;49:553–564. doi: [10.1007/s40279-019-01066-0](https://doi.org/10.1007/s40279-019-01066-0).
8. Gutowski NJ, Murphy RP, Beale DJ. Unilateral upper cervical posterior spinal artery syndrome following sneezing. *J Neurol Neurosurg Psychiatry*. 1992;55:841–843. doi: [10.1136/jnnp.55.9.841](https://doi.org/10.1136/jnnp.55.9.841).
9. Pryse-Phillips W. Infarction of the medulla and cervical cord after fitness exercises. *Stroke*. 1989;20:292–294. doi: [10.1161/01.str.20.2.292](https://doi.org/10.1161/01.str.20.2.292).
10. Toluie A, Joseph AT, Hrehorovich PA. Vertebral artery dissection in a young adult: a case report. *Cureus*. 2024;16:e58100. doi: [10.7759/cureus.58100](https://doi.org/10.7759/cureus.58100).