



Bilateral ductal stenting in an infant with pulmonary atresia and ventricular septal defect, non-confluent pulmonary arteries, and bilateral arterial duct

Brief Report

Cite this article: Padovani P, Ly M, and Baruteau A-E (2024). Bilateral ductal stenting in an infant with pulmonary atresia and ventricular septal defect, non-confluent pulmonary arteries, and bilateral arterial duct. *Cardiology in the Young*, page 1 of 3. doi: [10.1017/S1047951124000313](https://doi.org/10.1017/S1047951124000313)


Received: 30 June 2023
Revised: 26 December 2023
Accepted: 4 February 2024

Keywords:

tetralogy of Fallot with pulmonary atresia; nonconfluent pulmonary arteries; bilateral arterial duct; ductal stenting

Corresponding author:

Alban-Elouen Baruteau;
Email: albanelouen.baruteau@chu-nantes.fr

Paul Padovani^{1,2}, Mohamedou Ly¹ and Alban-Elouen Baruteau^{1,2,3,4} 

¹Nantes Université, CHU Nantes, Department of Pediatric Cardiology and Pediatric Cardiac Surgery, FHU PRECICARE, Nantes, France; ²Nantes Université, CHU Nantes, INSERM, CIC FEA 1413, Nantes, France; ³Nantes Université, CHU Nantes, CNRS, INSERM, l'institut du thorax, Nantes, France and ⁴Nantes Université, INRAE, UMR 1280, PhAN, Nantes, France

Abstract

Pulmonary atresia with ventricular septal defect, non-confluent pulmonary arteries, and bilateral arterial duct is a rare and complex CHD. Physiologic ductal closure may lead to life-threatening hypoxia. We present a case of successful bilateral ductal stenting as a bridge to further lower-risk surgical repair.

Ductal stenting can be offered in duct-dependent pulmonary circulation, as an alternative to surgical palliation with a modified Blalock–Taussig shunt. Ductal stenting can however be challenging in case of discontinuity of the pulmonary artery branches. Bilateral ductus arteriosus feeding discontinuous pulmonary arteries is scarce. We herein report successful bilateral ductal stenting in an infant with tetralogy of Fallot with pulmonary atresia and discontinuous right and left pulmonary arteries.

Case description

A 2500-gram term newborn was admitted in our department from the delivery room for the management of a prenatally diagnosed tetralogy of Fallot with pulmonary atresia. His peripheral oxygen saturation level was 80% on pulse oximetry in room air. Transthoracic echocardiography showed a normal atrial arrangement and confirmed a tetralogy of Fallot with pulmonary atresia and discontinuous pulmonary artery branches. At day-of-life 1, saturation dropped to 60%. Echocardiogram showed normally supplied right pulmonary artery but a constricted left ductus and functionally closed left pulmonary artery. Prostaglandin (PGE-1, 10 ng/kg/min) infusion was started and allowed restoration of the left pulmonary artery perfusion and subsequent improvement in oxygen saturation. A CT scan was performed to delineate ductal anatomy (Fig 1). After multidisciplinary team discussion, a transcatheter approach was preferred and the baby was transferred to the catheterisation laboratory. The left ventricular angiogram showed that the left pulmonary artery was supplied by a ductus arteriosus arising from the aortic arch, whilst the right pulmonary artery came straight from the brachiocephalic artery (Fig 1). There was no major aorto-pulmonary collateral artery. An elective ductal stenting with a 3.5 × 13 mm bare metal coronary stent was performed on the fifth postnatal day, with a 5-French Judkins Left 3.5 coronary guide catheter advanced through right ventricle into the aortic arch from the right femoral vein (Fig 2). PGE-1 had been stopped 6 hours before ductal stenting to allow the ductus to be well constricted. After ductal stenting, the baby was started on aspirin and clopidogrel. Four days later, oxygen saturation suddenly dropped again, up to 55%. Echocardiogram showed a well-positioned stent on the origin of the left pulmonary artery with an unrestrictive blood flow, but no right pulmonary artery was seen anymore. The patient was sent back to the catheterisation laboratory, where hand contrast injection demonstrated sub-occlusion of the proximal segment of the right pulmonary artery, which was consistent with ductal constriction of a second, right ductus arteriosus supplying the right pulmonary artery. Emergent ductal stenting of the right ductus was performed using a 3.5 × 24 mm bare metal coronary stent with a 5-French Judkins Right 3.0 coronary guide catheter into the brachiocephalic artery from the right femoral artery (Fig 2). This allowed clinical improvement and saturation increase up to 88%. Both stenting were uneventful, and the patient remained on aspirin and clopidogrel till surgical repair with pulmonary artery reimplantation 10 months later.

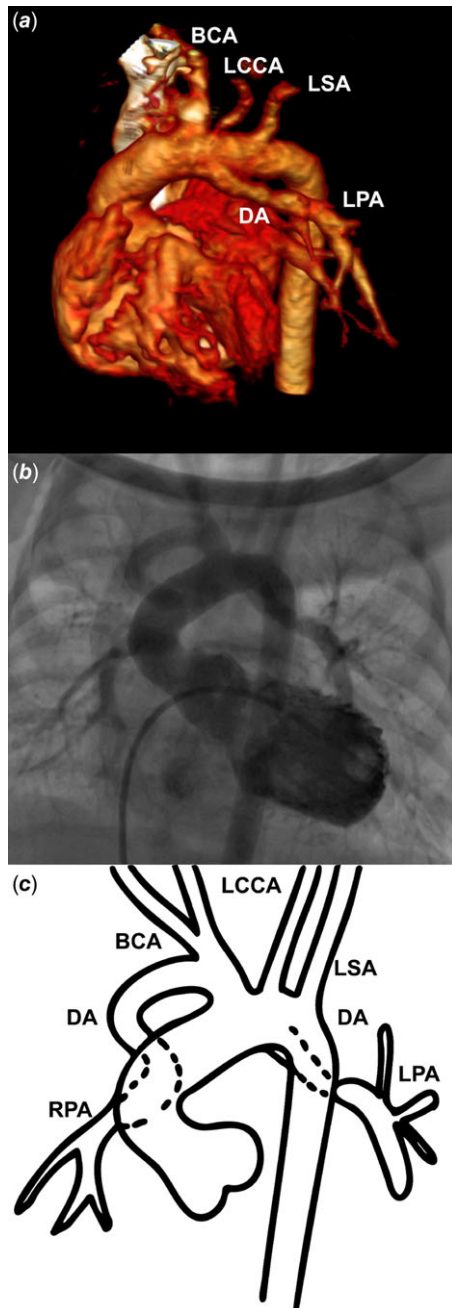


Figure 1. Multimodality imaging of bilateral arterial duct. Three-dimensional volume-rendering CT scan (a), left ventricular angiography (b), and a picture (c) showing bilateral ductus arteriosus feeding discontinuous pulmonary arteries. The left pulmonary artery is supplied by a left ductus arteriosus arising from the aortic arch. The right pulmonary artery is supplied by a right ductus arteriosus coming from the brachiocephalic trunk. RPA = right pulmonary artery; DA = ductus arteriosus; BCA = brachiocephalic artery; LCCA = left common carotid artery; LSA = left subclavian artery; LPA = left pulmonary artery.

Discussion

Bilateral arterial duct is a very rare anomaly, presumably due to maldevelopment of the sixth aortic arch during early embryogenesis. It has been more frequently described in pulmonary atresia, usually with non-confluent pulmonary arteries, with a high association with heterotaxy syndrome.¹ It has been more rarely reported in the setting of other complex CHDs such as hypoplastic

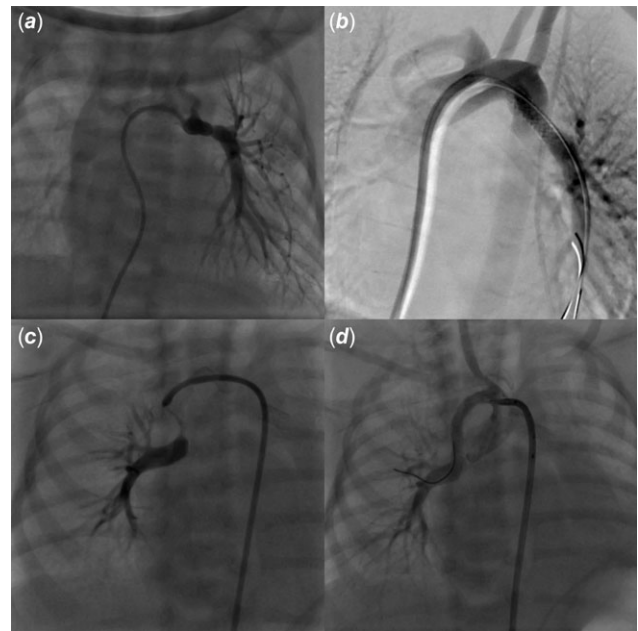


Figure 2. Bilateral arterial duct constriction and stenting. Hand injection via a 4-fr judkins right catheter engaged into the left ductus arteriosus delineating the left pulmonary artery (a). The left ductus was stented using a 3.5 × 13 bare metal coronary stent leading to successful recanalisation of the left pulmonary artery (b). Four days later, hand injection showing constricted right ductus arteriosus and functionally closed right pulmonary artery (c). The right ductus was stented using a 3.5 × 24 bare metal coronary stent leading to successful recanalisation of the right pulmonary artery (d).

left heart syndrome.² In pulmonary atresia with ventricular septal defect, non-confluent pulmonary arteries, and in the absence of major aorto-pulmonary collateral artery, each branch pulmonary artery is supplied independently by its ipsilateral ductus arteriosus, as seen in our case. Isolation of the pulmonary artery may occur early within the first days of life, or later on up to 12 months of age.³ Early neonatal physiologic ductal closure may result in abrupt pulmonary hypoperfusion and life-threatening hypoxia, thereby prompting emergent intervention. Surgical management has been applied successfully, consisting in either bilateral modified Blalock-Taussig shunt or unifocalisation of the non-confluent pulmonary arteries under cardiopulmonary bypass.^{4,5} Both surgical strategies are challenging, especially in low-birth-weight infants, and may result in pulmonary arteries distortion and decreased long-term patency due to excessive tension on surgical anastomoses.⁵ Ductal stenting carries a < 1% procedure-related mortality rate but a 9%–13% complication rate in the current era, with reported major acute (ductal spasm, stent malposition or embolisation, and acute stent thrombosis) and late (pulmonary overflow and neointimal proliferation) complications.⁶ Because of their flexibility and low profile, we used balloon-expandable coronary stents with favourable results and long-term patency of both pulmonary arteries. Ductal stenting in duct-dependent pulmonary circulation has however become widely accepted as a safe and efficient alternative to surgery, carrying a lower risk of postprocedural complications, extracorporeal membrane oxygenation (ECMO) use or mortality, as well as higher postprocedural oxygen saturation and Nakata index as compared to modified Blalock-Taussig shunt;⁷ it has also been shown to be effective in promoting a significant catch-up growth of duct-dependent discontinuous pulmonary arteries.⁸ The benefits-to-

risks ratio for ductal stenting has been shown to be less favourable in infants with a tortuous ductus, a body weight < 2.5 kg, and/or an insufficiently constricted ductus.⁹ High success rates have been achieved in experienced hands, and in a recent report of 38 ductal stenting in low-body-weight infants with duct-dependent pulmonary circulation, Al Nasef et al. showed that ductal stenting is feasible and effective in neonates < 2.5 kg, promoting adequate pulmonary artery growth.¹⁰ Reintervention rates are relatively high in this weight group, though many are planned to allow for optimal pulmonary artery growth before a definitive operation. According to ductal origin, ductal morphology, and ductal length, various techniques and vascular approaches may be considered. In tetralogy of Fallot with pulmonary atresia, the ductal morphology is often complex and ductal stenting is usually performed via an antegrade approach through the femoral vein, or a retrograde route via the femoral artery, or even via a common carotid or axillary artery surgical cut-down.

Conclusion

Although rarely observed, clinicians should be aware of the possibility of bilateral ducts with non-confluent pulmonary arteries, especially in the setting of pulmonary atresia, and that bilateral ductal stenting may be a feasible, safe, and effective first-step palliation towards further lower-risk cardiac surgery.

Acknowledgements. We gratefully acknowledge Dr Luc Morin, GCS HUGO, AVIESAN, and FHU PRECICARE.

Financial support. A.-E.B is supported by the French Government as part of the “Investments of the future” programme managed by the National Research Agency (grant reference ANR-16-IDEX-0007), FHU PRECICARE.

Competing interests. None.

Ethical standards. The authors assert that all procedures contributing to this work comply with the Helsinki Declaration of 1975, as revised in 2008.

References

1. Peirone A, Abdullah MM, Dicke F, Freedom RM, Smallhorn J. Echocardiographic evaluation, management and outcomes of bilateral arterial ducts and complex congenital heart disease: 16 years' experience. *Cardiol Young*. 2002; 12: 272–277.
2. Gray WH, Sorabella RA, Berry CM, Padilla LA, Law MA, Dabal RJ. Hybrid norwood for hypoplastic left heart syndrome with rare aortic arch anatomy. *Wor J Ped Cong Heart Surg*. 2023; 14: 756–758. DOI: [10.1177/21501351231176455](https://doi.org/10.1177/21501351231176455).
3. Waldman JD, Karp RB, Gittenberger-de Groot AC, Agarwala B, Glagov S. Spontaneous acquisition of discontinuous pulmonary arteries. *Ann Thorac Surg*. 1996; 62: 161–168.
4. Nakamura M, Kanno K, Nishioka M. Primary pulmonary artery reconstruction for functional single ventricle with absent central pulmonary artery and bilateral patent ductus arteriosus. *Gen Thorac Cardiovasc Surg*. 2022; 70: 541–546.
5. Stamm C, Friehs I, Zurakowski D, et al. Outcome after reconstruction of discontinuous pulmonary arteries. *J Thorac Cardiovasc Surg*. 2002; 123: 246–257.
6. Valdeomillos E, Jalal Z, Boudjemline Y, Thambo J-B. Transcatheter ductus arteriosus stenting in paediatric cardiology: indications, results and perspectives. *Arch Cardiovasc Dis*. 2020; 113: 129–141.
7. Abdelmassih AF, Menshawey R, Menshawey E, et al. Blalock-taussig shunt versus ductal stent in the palliation of duct dependent pulmonary circulation: a systematic review and metaanalysis. *Curr Probl Cardiol* 2022; 47: 100885.
8. Santoro G, Capozzi G, Giordano M, et al. Fate of duct-dependent, discontinuous pulmonary arteries after arterial duct stenting. *Pediatr Cardiol*. 2017; 38: 1370–1376.
9. Alwi M, Mood MC. Stenting of lesions in patent ductus arteriosus with duct-dependent pulmonary blood flow: focus on case selection, techniques and outcome. *Interv Cardiol Clin*. 2013; 2: 93–113.
10. Nasef MA, Shahbah DA, Batlivala SP, et al. Short- and medium-term outcomes for patent ductus arteriosus stenting in neonates ≤ 2.5 kg with duct-dependent pulmonary circulation. *Catheter Cardiovasc Interv*. 2022; 100: 596–605.