

Letters to the Editor

Use of the flexible oesophagoscope for the removal of an intramural oesophageal foreign body

Dear Sir,

The case report by Mr V. H. Harihar, January 1991,

Vol. 105, pp. 46–47 attracted our attention and prompted us to report our observation using the flexible oesophagoscope for removing intramural oesophageal foreign bodies in the pharynx and upper oesophagus. It allows confirmation of the radiographic site and position

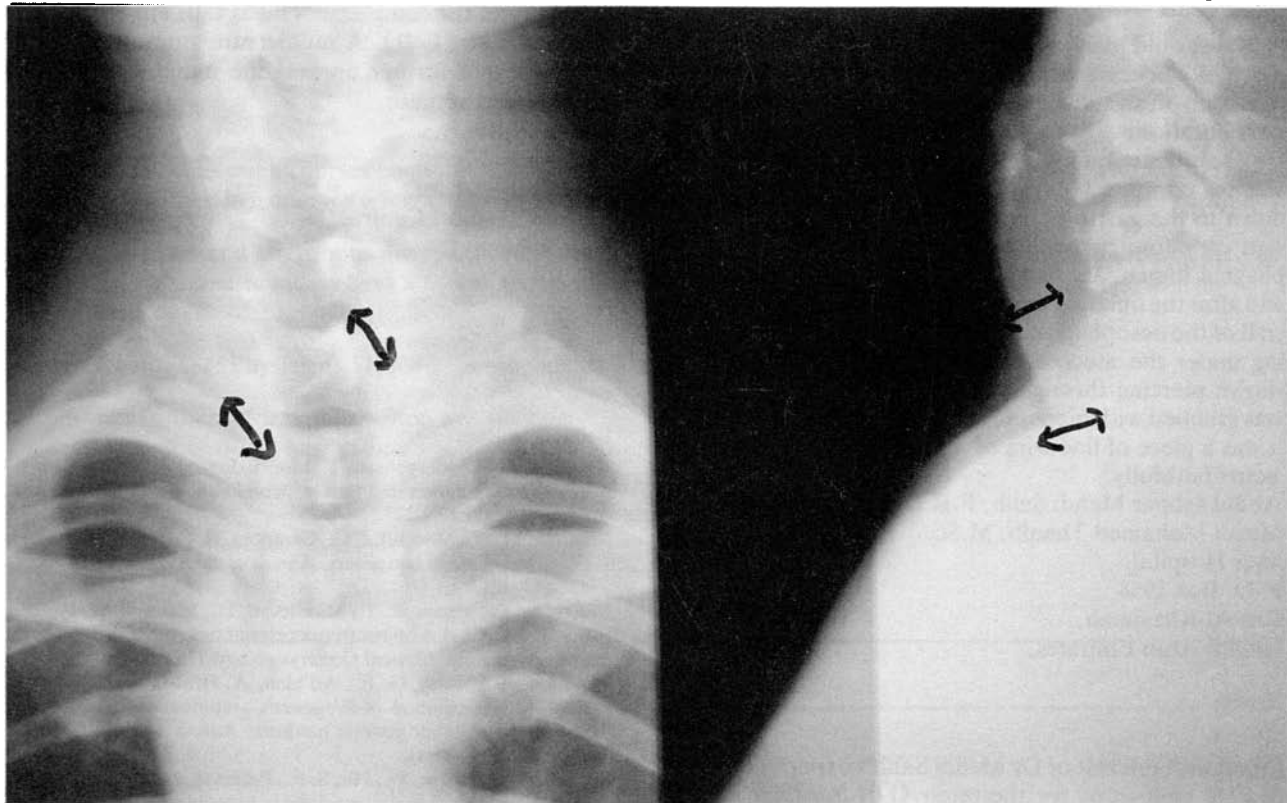


Fig. 1

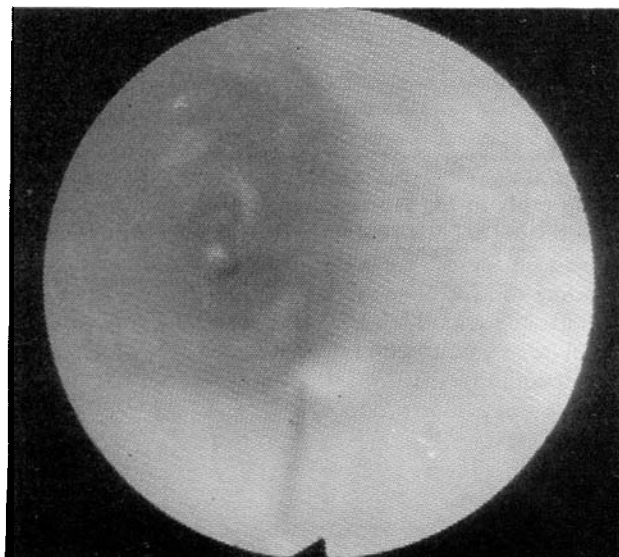


Fig. 2

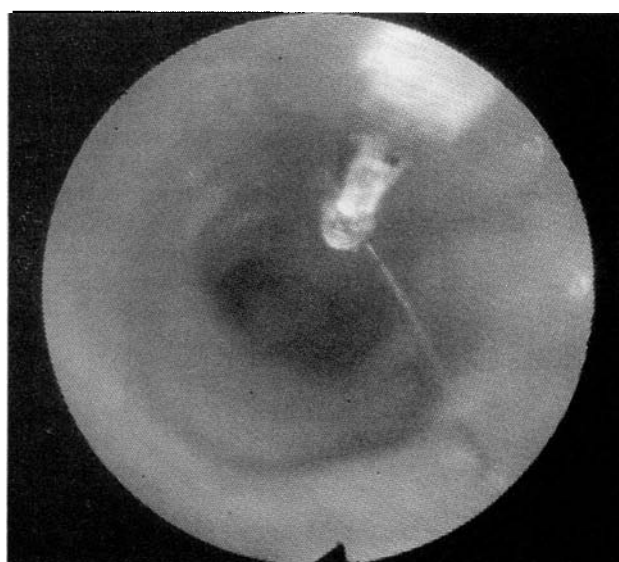

Fig. 3




FIG. 4

of the foreign body (bony or metallic), which has been stuck for some time and become covered by fibrinous membrane which masks its viewing through the rigid oesophagoscope. Because of its small calibre it allows a wide angle of view when the oesophagus is inflated.

Case report

A 30-year-old man presented with a history of eating a piece of chicken from the grill, followed by a pricking sensation on swallowing, at the root of the neck of three days duration.

A soft tissue radiograph of the neck showed a linear shadow opposite C7 (Fig. 1); on rigid oesophagoscopy down to the gastro-oesophageal junction there was no sign of a foreign body or wound in the entire oesophageal lumen. By using the flexible oesophagoscope and after the inflating the lumen causing stretching of the wall of the oesophagus, the foreign body appeared shining under the mucosa at 25 cm with 3 mm of its end shown piercing through the mucosa (Fig. 2). The end was grabbed with biopsy forceps and recovered (Fig. 3); it was a piece of fine wire of 2.5 cm long. (Fig. 4).

Yours faithfully,

Abdul Jabbar Mehdi Salih, F.R.C.S.,

Magdi Mohamed Thaqib, M.Sc.

Saqr Hospital,

P. O. Box 1954,

Ras Al-Khaaimah,

United Arab Emirates.

Reply:

Sir,

I read with interest of Dr Mehdi Salih's experience with flexible endoscopy for the removal of a foreign body, and thank him for sharing this with us.

All the ENT units I have been associated with have not been in favour of doing a flexible fiberoptic oesophagoscopy as over the years, otolaryngologists have felt happier with the rigid 'scope. I personally would be concerned about the possibility of a through-and-through perforation of the oesophagus by the foreign body, which could result in mediastinal emphysema if air was insufflated into the oesophagus while doing an oesophagoscopy.

Since my experience with this is very limited, I do not know how often this complication arises in practice. We look forward to trying this when we get the right circumstances.

V. Harihar, F.R.C.S., D.L.O.,

Lister Hospital,

Coreys Mill Lane,

Stevenage,

Herts. SG1 4AB.

Wegener's granulomatosis: Familial occurrence

Dear Sir,

I note with interest the recent report by Stoney *et al.*

(1991) of Wegener's granulomatosis (WG) in two siblings. They state that the only previous report of familial WG was by Muniain *et al.* (1986), but I would draw their attention to Knudsen *et al.* (1988) who describe two brothers with the condition and a sister who, although asymptomatic, had an elevated anti-neutrophil cytoplasmic antibody (ANCA) titre.

The disease is believed to be immunologically mediated and the above reports suggest a hereditary trait. Accordingly, immunogenetic markers in WG patients have been sought and the results were presented at the last two meetings of the ORS. The HLA antigen complex does not appear to have a major role in the disease, (Murty *et al.*, 1991) but the GLOI phenotype 1-1 and the complement locus C4B are implicated, (Papiha *et al.*, 1991). A multicentre study is presently attempting to further unravel the immunogenetics of this complex disease.

Yours faithfully,

George E. Murty,

ENT Department,

Queens Medical Centre,

Nottingham.

References

- Knudsen, B. B., Joergensen, T., Munch-Jensen, B. (1988) Wegener's granulomatosis in a family. *Scandinavian Journal of Rheumatology*, **17**: 225-227.
- Muniain, M. A., Moreno, J. C., Campora, R. G. (1986) Wegener's granulomatosis in two sisters. *Annals of the Rheumatic Diseases*, **45**: 417-421.
- Murty, G. E., Mains, B. T., Middleton, D., Maxwell, A. P., Savage, D. A. HLA Antigen frequencies of patients with Wegener's granulomatosis. *Clinical Otolaryngology*. (In press).
- Papiha, S. S., Murty, G. E., Ad'hiah, A. H., Mains, B. T., Venning, M. Association of Wegener's granulomatosis with HLA antigens and other genetic markers. *Annals of the Rheumatic Diseases*. (In press).
- Stoney, P. J., Davies, W., Ho, S. F., Paterson, I. C., Griffith, I. P. (1991) Wegener's granulomatosis in two siblings: a family study. *Journal of Laryngology and Otology*, **105**: 123-124.

Reply

Dear Sir,

In reply to Mr Murty's comments on our paper, it is interesting to know that familial occurrence is not quite as rare as it seems. We are glad that he concurs with our finding of lack of association of the HLA system with Wegener's granulomatosis, and await the results of the trial he mentions with interest.

Yours faithfully,

P. J. Stoney,

W. Davies,

S. F. Ho,

I. C. Paterson,

I. P. Griffith,

Singleton Hospital,

Swansea SA2 8LG.