


Letter to the Editor: New Observation

Cough Headache Responsive to Occipital Nerve Blockade

Aqeel Almutairi and Tommy Lik Hang Chan 

Department of Clinical Neurological Sciences, Western University, London, ON, Canada

Keywords: Occipital nerve blocks; occipital neuralgia; primary cough headache; peripheral nerve blocks

A 71-year-old female with atrial fibrillation on apixaban and chronic neck pain was referred to the headache clinic with a 1-year history of new-onset bilateral moderate to severe occipital stabbing headache associated with Valsalva manoeuvres such as coughing and sneezing. It reaches maximal intensity within 1 s and lasts for 2–5 s. Between attacks, she would be pain-free. No other triggers were identifiable. Self-administered as needed Ibuprofen 200–400 mg provided no relief.

The diagnosis of primary cough headache was suspected by a referring neurologist, who suggested a trial of indomethacin. However, the patient declined due to apprehension regarding daily oral medication because of her advanced age, cardiac history, and potential drug–drug interactions with oral anticoagulation.

Her neurological examination was unremarkable except for tenderness on palpation in the nerve distribution supplied by the greater occipital and lesser occipital nerves bilaterally (Fig. 1). MRI with angiogram of the head did not reveal any structural, vascular, or posterior fossa lesion to explain her headache.

Based on the examination and her treatment preference, nerve blocks with local anaesthetics were initiated. A total of 10 ml of bupivacaine 0.5% (5 mg/ml) without steroids was injected into the greater (3 ml each side) and lesser (2 ml each side) occipital nerves (Fig. 1). Pain freedom was achieved after injection, and subsequent coughing or sneezing did not trigger a headache. The response was sustained for 3–4 weeks post-injection, with only mild re-emergence of headache (lower frequency and intensity) 3–4 days before the next set of injections when transitioned to monthly injections.

Cough headaches can be either primary or secondary. Secondary cough headache can be associated with space-occupying or posterior fossa lesions such as subtentorial tumours or Chiari malformation type 1. Primary cough headache can only be diagnosed if a secondary cause has been ruled out. It is a rare headache disorder with a lifetime prevalence of 1% and a mean age of onset above 60 years old.^{1,2} It is precipitated only by cough or Valsalva manoeuvres such as sneezing. The headache is often sudden in onset, lasting between 1 s and 2 hours and localised to the occipital region.³

The pathophysiology of primary cough headache is not well understood. It has been hypothesised that there is an increase in

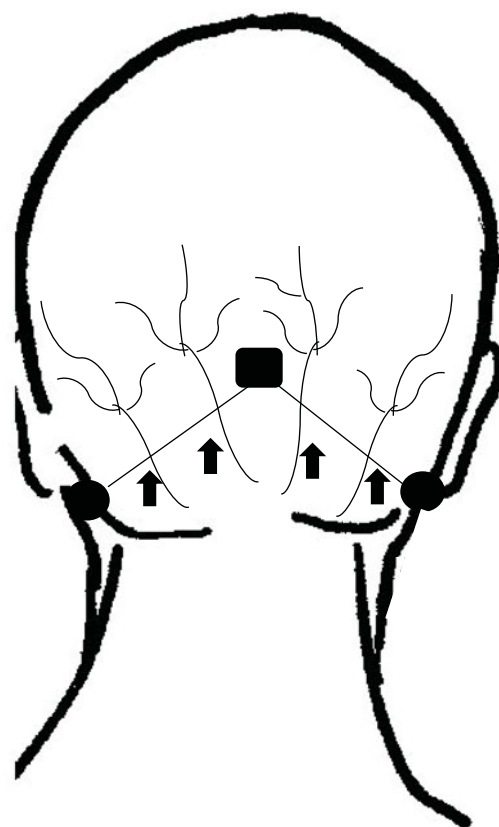


Figure 1: Greater and lesser occipital nerve distribution. Landmarks and injection sites (arrows): greater occipital nerve, 2/3 from mastoid process (circle) to occipital protuberance (square); lesser occipital nerve, 1/3 from mastoid process (circle) to occipital protuberance (square).

intracranial pressure caused by coughing (increase in intrathoracic and intra-abdominal pressure). A more crowded posterior cranial fossa may be seen in patients with primary cough headache, supporting the hypothesis of a relative obstruction of cerebrospinal fluid flow during coughing.⁴ Indomethacin is the preferred drug, and its effect on Valsalva-induced headaches may be due to a

Corresponding author: T. L. H. Chan; Email: tommychan424@gmail.com

Cite this article: Almutairi A and Chan TLH. Cough Headache Responsive to Occipital Nerve Blockade. *The Canadian Journal of Neurological Sciences*, <https://doi.org/10.1017/cjn.2024.17>

© The Author(s), 2024. Published by Cambridge University Press on behalf of Canadian Neurological Sciences Federation. This is an Open Access article, distributed under the terms of the Creative Commons Attribution-NonCommercial-NoDerivatives licence (<http://creativecommons.org/licenses/by-nc-nd/4.0/>), which permits non-commercial re-use, distribution, and reproduction in any medium, provided that no alterations are made and the original article is properly cited. The written permission of Cambridge University Press must be obtained prior to any commercial use and/or adaptation of the article.

reduction in intracranial pressure.^{5,6} Other treatments/methods that lower intracranial pressure have been reported in treating primary cough headache, such as topiramate and large volume cerebrospinal fluid removal.^{7,8} Neuromodulation such as non-invasive vagal nerve stimulation has been reported as well, but the mechanism has not been fully elucidated.⁹

In this case, nerve block to the occipital nerves was suggested based on examination findings, and the response was dramatic. It could be hypothesised that rapid changes in head and neck position during coughing may have triggered transient compression and/or local perineural inflammation of the occipital nerves, which originate from the C2–C3 spinal nerves. The patient has chronic neck pain, which may suggest a predisposing risk factor.

The response to nerve block raised a possible alternative presentation of primary cough headache: it may present similarly to occipital neuralgia as pain is caused by transient compression of occipital nerves during coughing or sneezing, rather than transient high intracranial pressure. This observation suggests that primary cough headaches, especially those with shorter attack duration (lasting for seconds), may be occipital neuralgia-like. It is possible this is a case of cough-induced (associated with neck movement) occipital neuralgia. A limitation of this case is that if the headache was induced by nerve compression, it should also be triggered by similar neck movement rather than only coughing or sneezing; however, the patient did report she has been very careful with her day-to-day neck movement due to chronic neck pain. Another limitation of this case is cervical spine imaging was not performed.

The presence of wearing off of nerve block prior to the next treatment is suggestive of ongoing nerve block benefit; however, the duration of the analgesic effect from nerve block remains unpredictable. The use of nerve block can minimise the risk of systemic side effects associated with conventional oral medications for primary cough headache, such as indomethacin. A clue to predicting the response to nerve block may be elicited on examination based on tenderness on palpation in the respective nerve distribution; hence, local tenderness as a selection criterion should be considered in future trials.

Data availability statement. The material analysed during the current case is available from the author on request.

Acknowledgements. None.

Author contributions. Dr AA and Dr TLHC assessed, examined the patients, and wrote the manuscript.

Funding statement. None.

Competing interests. Dr Aqeel Almutairi and Dr Tommy Lik Hang Chan have no conflicts of interest (financial or non-financial) to disclose relevant or pertain to this study.

Consent. Informed written consent was obtained from the patient.

References

1. Rasmussen BK, Olesen J. Symptomatic and nonsymptomatic headaches in a general population. *Neurology*. 1992;42:1225–31.
2. Cordenier A, De Hertogh W, De Keyser J, Versijpt J. Headache associated with cough: a review. *J Headache Pain*. 2013;14:42.
3. Olesen J. International classification of headache disorders. *Lancet Neurol*. 2018;17:396–7.
4. Chen YY, Lirng JF, Fuh JL, Chang FC, Cheng HC, Wang SJ. Primary cough headache is associated with posterior fossa crowdedness: a morphometric MRI study. *Cephalalgia*. 2004;24:694–9.
5. Godoy DA, Alvarez E, Manzi R, Piñero G, Di Napoli M. The physiologic effects of indomethacin test on CPP and ICP in severe traumatic brain injury (sTBI). *Neurocrit Care*. 2014;20:230–9.
6. Förderreuther S, Straube A. Indomethacin reduces CSF pressure in intracranial hypertension. *Neurology*. 2000;55:1043–5.
7. Medrano V, Mallada J, Sempere AP, Fernández S, Piqueras L. Primary cough headache responsive to topiramate. *Cephalalgia*. 2005;25:627–8.
8. Raskin NH. The cough headache syndrome: treatment. *Neurology*. 1995;45:1784.
9. Moreno-Ajona D, Villar-Martínez MD, Goadsby PJ, Hoffmann J. Primary cough headache treated with non-invasive vagal nerve stimulation. *Neurology*. 2020;95:593–4.