

## HEBERDEN'S NODES: CONCORDANT OSTEOARTHRITIS OF THE FINGERS IN IDENTICAL TWINS

by

*Robert M. Stecher, M. D.*

This is a description of a pair of identical twins who had concordant Heberden's nodes or osteoarthritis of the finger joints. The report will include comments on the disease, a clinical description of the patients and a documentation of this type of twinning. Despite the fact that Heberden's nodes occur very commonly and are dependent upon heredity few, if any, descriptions of the disease in twins seem to have been published because no such instances have previously come to the authors' attention.

Heberden's nodes as originally described (1) consist of "little hard knobs, about the size of a small pea, which are frequently seen upon the fingers, particularly a little below the top, near the joint". Radiographic studies (9) show that these are associated with spur formation arising from the dorsal aspect of the proximal end of the distal phalanx, the ventral aspect of the proximal end of the distal phalanx, the dorsal aspect of the distal end of the middle phalanx and the ventral aspect of the distal end of the middle phalanx in a decreasing order of frequency. The degree of clinical enlargement of the joints is not always in proportion to the degree of bony change and may even be slight as is the case in these twins.

Involvement of the proximal finger joints with osteoarthritis is much more common than was previously supposed. Most textbooks and many competent clinicians believe that arthritis of terminal finger joints is osteoarthritis and arthritis of proximal finger joints is rheumatoid arthritis. In an examination of 100 consecutive photographs and radiographs it was found that proximal joints are involved about one-third to one-fourth as often as the distal joints. A diagram showing the frequency of involvement of all the finger joints has been published (7).

Convincing evidence indicates that Heberden's nodes is largely determined by heredity. Examination of 9,000 hospital patients (3), a random selection of the population so far as arthritis of the fingers is concerned, showed that idiopathic Heberden's nodes could be distinguished from traumatic Heberden's nodes, that the incidence of idiopathic Heberden's nodes is about ten times as frequent in women as in men and the median age of onset in women is about 50 years. Three instances of familial involvement could not have been expected to occur on a basis of chance more often

than once in 190 families, 4,500,000 families and 10,000,000 families (4). Had these combinations been due to chance one observer would probably have had to examine all the families of the world of all times to find such families. It was further found that the disease was found in the mother of patients twice as often and in the sisters three times as often as it was found in a control series and as it was expected in



Fig. 1. Mrs. H. and Mrs. L., identical twins. The difference in height is due to the difference in the heels of their shoes.

the general population. The study of pedigrees with correction for small family size and incomplete penetrance for lack of age indicate that Heberden's nodes is inherited as a single chromosome character sex influenced to be dominant in women and recessive in men. Gene frequency analysis shows that homozygous affected occur in 2.7 per cent of the population, heterozygotes in 27 per cent and homozygous normals in 70 per cent (10). There seems to be an undiscovered relation to the menopause since one-half of the patients noted enlargements of their fingers within three years of the last men-




Fig. 2. Lateral view of Mrs. H. and Mrs. L.

strual period (8). There is no positive correlation between Heberden's nodes and hypertension, obesity or osteoarthritis of other joints (6). An intact nerve supply of the finger is necessary for their development (11).

#### Case history

Mrs. H. came April 23, 1953 complaining of arthritis of the hands of 5 years duration. She thought the symptoms arose after removal of a cast of the left arm applied after a fall. The patient's husband believed the symptoms began before the fall but increased at that time. Her fingers had gotten quite large at that time and have subsequently become smaller. As time went on the symptoms progressed. One year before she had abandoned golf because it hurt her fingers to hold the club. She has been bothered with pain in the neck and shoulders. Otherwise she was surprisingly well and vigorous.

Mrs. L., Mrs. H's twin sister, kindly came in for examination at my request May 26th because she was thought to have the same condition of her hands. Having a naturally happy disposition she had always been accustomed to belittle minor physical ailments and had not complained of her hands. She was indefinite about the onset but believed her fingers had started to enlarge



about 15 years before. This would have been 5 years after her last menstrual period. She had had trouble with her left knee for 20 years since an injury at that time. She also was surprisingly well and active.

The family history was not remarkable. The father had died at the age 72 of tuberculosis. He had no arthritis. The mother had died at the age 82 of carcinoma of the lung. She was reported as not having Heberden's nodes, arthritis of the fingers or any joint disease. These identical twins born 68 years before had been the only children.

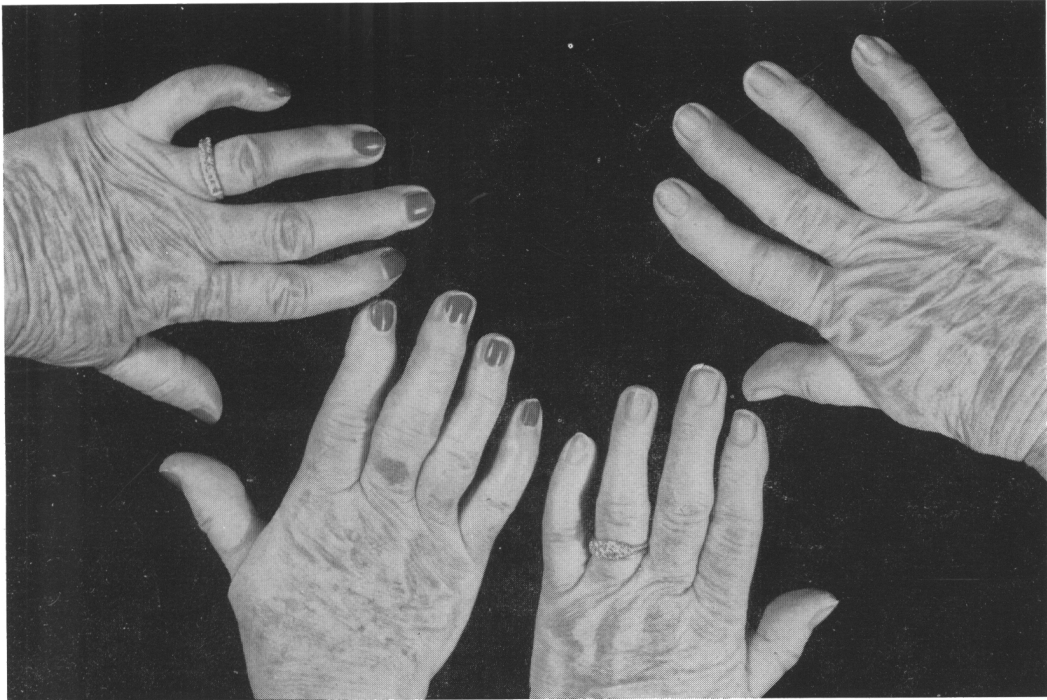

Fig. 3. Photographs of the hands of Mrs. H. on the left and Mrs. L. on the right. Enlargement and deformities are seen in most of the terminal and the proximal finger joints. The metacarpophalangeal joints and the wrist joints are normal.

Mrs. H. had been married 48 years before. Her husband was living and well. This couple had two daughters aged 42 and 40, both of whom are living and well and are married.

Mrs. L. had been married 46 years before. Her husband is living and well. She had three children, a son 43 years old and daughters 38 and 33 years old all of whom are living and well and married.

The physical examinations were so nearly alike that they can be given together.

---

Photographs of these women taken in anterior and left lateral views show that they are remarkably alike. The apparent difference in height is due to the difference of the height of the heels of their shoes. The arrangement of the hair, the foreheads, the eyebrows, the eyes, the noses, the mouths, the chins and the shoulders are similar. Both women are 5 feet, 2 inches tall, have grey hair, blue eyes, straight noses and large mouths. Mrs. H. weighs 142 pounds, Mrs. L. 128 pounds. Mrs. H. wears a full upper and partial lower denture. Mrs. L. wears full upper and lower dentures. Both hearts are of normal size, pulse rates were 80 beats per minute, the rhythms were regular, the sounds of good quality and no murmurs were heard. Mrs. H. had a blood pressure of 120 over 70 m.m. of mercury. Mrs. L. had 142 over 85 m.m. of mercury, both on one examination. Abdominal palpation was negative. The shoulders, elbows, wrists and metacarpophalangeal joints and the hips, knees, ankles and feet were normal in appearance and function.

Photograph of the four hands are shown in Fig. 3. Enlargement and deformities of the terminal joints are well shown in the fifth, third and second finger of both hands of Mrs. H. and of the third and second finger on the left and the second, third and fifth finger of the right of Mrs. L. Most of the proximal joints show enlargement, deformities or flexion on both hands.

The bone deformities are best shown in radiographs of the fingers taken individually in the lateral view by Dr. Harry Hauser. The fingers of the right hand of both sisters are seen in Fig. 4. The views of Mrs. H. show large masses of bone extending dorsally and ventrally from both the proximal ends of the distal phalanges and the distal ends of the proximal phalanges. They are especially large in the thumb, the second, third and fifth fingers. The picture of the fourth finger is not a true lateral view which may in part make the spurs appear less large. Similar but much smaller spurs are seen in the fingers of Mrs. L. Abnormalities are seen in all of the proximal interphalangeal joints except that of the thumb. They are most marked in the third and fourth fingers but are definitely seen in the second and fifth fingers. The proximal joints of Mrs. L. are similarly but much less seriously affected.

Similar radiographs of the lateral views of the fingers of the left hands of both sisters are seen in Fig. 5. The distal joints of the thumbs, the second and the fourth finger of Mrs. H. are less seriously affected than are the same fingers on the right hand. However, these joints on Mrs. L.'s hands seem to be more seriously affected than they are in the sister. The proximal joints of both left hands are less severely affected than those of the right hands and the proximal joints of both of Mrs. L.'s hands are less severely affected than are those of Mrs. H.'s.

The laboratory results in both sisters were surprisingly alike. Giving the results for Mrs. H. first, they were red blood cell counts of 5,120,000 and 5,110,000, hemoglobins of 13.4 and 13.2 gms. per 100 cc., white blood cell counts 6,700 and 7,900, hematocrit of 41 and 40 per cent, erythrocyte sedimentation rate, corrected, of 13 and 10 mm. per hour by the Wintrobe method, serum uric acids of 5.4 and 5.1 mg. per 100 cc. which is within normal limits and creatinine of 1.2 and 1.1 mg. per 100 cc. Extensive blood type examination made by Dr. Roger W. Marsters of University Hospitals, Cleveland,

Ohio, showed both bloods to be negative for type A, positive for type B, Rh positive, CD homozygous, M-positive, N-negative, S-negative, P-negative, K-negative and F-positive.




Fig. 4. Lateral radiograph of the right fingers of Mrs H. above and Mrs. L. below. I. coving large spurs on the terminal joints of the thumb, forefinger, middle finger and little finger, above, and smaller spur on the terminal joints, below. The proximal joints show spurs, joint mice and other deformities.

Concordance of eye color, hair over the middle phalanges of the fingers, ability to taste phenylthiocarbamide and the above series of blood groups establish that these are identical or single egg twins to a very high degree of probability.

#### Discussion

Heberden's nodes are thought to be a particular form of osteoarthritis affecting the finger joints. A survey of patients with this condition revealed that osteoarthritis of



other joints was not found significantly more often than it was found in a control series of women of the same age distribution (5). It is expected that osteoarthritis will occur in patients with Heberden's nodes as it does in other elderly women. Kellgren et al consider Heberden's nodes as a manifestation of generalized osteoarthritis. This view




Fig. 5. Lateral radiograph of the left fingers of Mrs. H., above, and Mrs. L., below. L. showing large spurs on the middle finger, above, and all the fingers, below. The proximal joints show spurs, joint mice and other deformities.

no doubt arises from the fact that they studied generalized osteoarthritis and found some patients with Heberden's nodes. The author started with Heberden's nodes and found many patients without osteoarthritis of other joints as is the case in these twins.

The clinical appearance of the fingers is not entirely typical of Heberden's nodes because the terminal joints of the fingers show little enlargement, no flexion deformity and no lateral deviation of the terminal phalanges. The lateral radiographs dispell any doubts as to the diagnosis.

The radiographs show evidence of mirror imaging of the disease. It is seen that the right thumb of Mrs. H. and the left thumb of Mrs. L. are more seriously affected than the other thumbs. The right forefingers of Mrs. H. and the left forefinger of Mrs. L. also have more advanced disease than the others. The middle fingers of Mrs. H. are both more enlarged than are those of Mrs. L. The fourth and fifth fingers of both hands of both twins seem to be about equally affected.

These patients have been described in the hope that other similar instances of Heberden's nodes in twins will be recognized and placed on record.

### Summary

Heberden's nodes or osteoarthritis of the finger joints are described in two identical twins. The appearance of the hands and the bone changes in individual joints as shown by radiographs are remarkably alike. That the twins are identical is indicated by agreement of eye color, hair on the fingers, tasting of phenylthiocarbamide and of 8 blood groups. Evidence of a tendency to mirror imaging in the distribution of the disease among the fingers is seen.

Osteoarthritis of the fingers occurs in these cases in the apparent absence of manifestations of osteoarthritis in other joints. Heberden's nodes is an hereditary disease but this seems to be the first description published of its occurrence in twins.

### References

1. HEBERDEN, W.: Commentaries on the History and Cure of Diseases. Second edition, 518 pp. London: T. Payne. 1803.
2. KELLGREN, J. H. and MOORE, R.: Generalized Osteoarthritis and Heberden's Nodes; *British Medical Journal*, Vol. I, p. 181, 1952.
3. STECHER, R. M.: Heberden's Nodes; The Incidence of Hypertrophic Arthritis of the Fingers. *New England Journal of Medicine* 222: 300, 1940.
4. STECHER R. M.: Heberden's Nodes; Heredity in Hypertrophic Arthritis of the Finger Joints. *American Journal of Medical Sciences*, 201: 301-809, 1941.
5. STECHER, R. M.: Heberden's Nodes; Their Relation to Other Degenerative Joint Diseases. *Archives of Physical Medicine*, 27: 409-413, 1946.
6. STECHER, R. M.: Heberden's Nodes, 4; The Association of Hypertension and Obesity to Degenerative Joint Disease of the Fingers. *Journal of Laboratory and Clinical Medicine*, 31: 687-693, 1946.
7. STECHER, R. M.: Nodulos de Heberden. *Revista Espanola de Reumatismo*, 3: 310-332, 1949.
8. STECHER, R. M., BEARD, E. E. and HERSH, A. H.: Heberden's Nodes; The Relationship of the Menopause to Degenerative Joint Disease of the Fingers. *Journal of Laboratory and Clinical Medicine*, 34: 1193-1202, 1949.
9. STECHER, R. M. and HAUSER, HARRY: Heberden's Nodes, VII; The Roentgenological and Clinical Appearance of Degenerative Joint Disease of the Fingers. *American Journal of Roentgenology and Radium Therapy*. 59: 326-337, 1948.
10. STECHER, R. M. and HERSH, A. H.: Heberden's Nodes; The Mechanism of Inheritance in Hypertrophic Arthritis of the Fingers. *Journal of Clinical Investigation*. 23: 699-704, 1944.
11. STECHER, R. M. and KARNOSH, L. J.: Heberden's Nodes, VI; The Effect of Nerve Injury Upon the Formation of Degenerative Joint Disease of the Fingers. *American Journal of Medical Sciences*. 213: 181-191, 1947.



### SOMMARIO

Vengono descritti i nodi di Heberden (osteoartrite delle articolazioni delle dita) di due gemelle identiche. L'apparenza delle mani e le modificazioni ossee delle singole articolazioni, come rivelato dalle singole radiografie, sono notevolmente simili. Che le

gemelle siano identiche viene indicato dalla concordanza del colore degli occhi, dei peli delle dita, della sensibilità gustativa alla feniltiocarbamide e da otto gruppi sanguigni. Si nota una tendenza alla specularità nella distribuzione della malattia nelle dita.

L'osteoartrite delle dita si verifica in questi casi nell'apparente assenza di manifestazioni di osteoartrite in altre articolazioni. I nodi di Heberden sono una malattia ereditaria, ma questa risulta essere la prima descrizione pubblicata del suo verificarsi nei gemelli.

### SOMMAIRE

On trouvera ici la description des noeuds de Heberden (ostéoarthrite des articulations des doigts) de deux jumelles identiques. Il résulte des relatives radiographies une remarquable similitude dans l'apparence des mains et dans les modifications

osseuses des différentes articulations. Le fait que les jumelles soient identiques est prouvé par la concordance de la couleur des yeux, des poils des doigts, de la sensibilité du goût à la phénylthiocarbamide et par les huit groupes sanguins. La distribution de la maladie dans les doigts dénote une tendance très nette

à la spécularité. L'ostéoarthrite des doigts se vérifie dans ce cas sans qu'il apparaisse de manifestations d'ostéoarthrite dans les autres articulations. Les noeuds de Heberden sont une maladie héréditaire mais c'est la première fois, semble-t-il, que l'on en publie une description dans le cas de deux jumeaux.

### ZUSAMMENFASSUNG

Eine Beschreibung Heberdenscher Knoten oder Osteoarthritis der Fingergelenke in einem identischen Zwillingspaare wird hier dargeboten.

Der Anblick der Haende und die Veraenderungen in den Knochen der einzelnen Gelenke, die in den Roentgenogrammen ge-

zeigt werden, sind bemerkenswert aehnlich.

Die Identitaet der Zwillinge ist durch Uebereinstimmung der Augenfarbe, Haare auf den Fingern, Phenylthiocarbamideversuch und 8 Blutgruppen bestaetigt.

Die Verbreitung des Leidens scheint eine Neigung zu Spiegelbild-Formen zu haben. In den

genannten Faellen erscheint die Osteoarthritis in den Fingern ohne andere Gelenke zu ergreifen.

Die Heberdenschen Knoten sind zweifellos ein hereditaeres Leiden; jedoch scheint dieses die erste Veroeffentlichung einer Beschreibung der Krankheit in einem Zwillingspaare zu sein.