

The Journal of Laryngology and Otology

(Founded in 1887 by MORELL MACKENZIE and NORRIS WOLFENDEN)

October 1955

THE PRINCIPLES OF PLASTIC SURGERY OF THE SOUND-CONDUCTING APPARATUS

By FRITZ ZÖLLNER (Freiburg, Germany)

BECAUSE of the varying factors inherent in diseases of the sound-conducting apparatus, the results given by rehabilitation surgery in this sense organ must be controlled with special caution so that the value of different methods may be judged as early as possible. My own material is not very voluminous, but from the very beginning I sought to investigate before the operation, the special conditions in each case, to record them by a sketch, to measure and interpret them as to their acoustic state. Thus certain conclusions can be drawn even from a small number of cases; but definite judgment will only be possible after a few years, and only then will it be known whether the original disease was completely cured by the operation, and whether the plastic replacements—especially implanted tissue—will remain intact in the ear. I am sorry it is not so long since the very new variations of this surgical technique were first applied. Yet the cases treated four years ago show that by implanting some of the patient's own skin, hearing did not deteriorate but, on the contrary, improved during the first year and then remained constant. Only in cases of recurrence of inflammation which destroyed the new structures may the gain in hearing be wholly or partially lost. In such cases, however, the plastic operation can be repeated after the inflammation has been eliminated.

It is not easy to lay down a definite scheme for judging the improvement in hearing. In general a surgeon tends to evaluate the quality of his technique by an overall-statistic of all his cases showing by how much he could improve hearing on the whole. Now, such statistics may make a good survey, but it will not always be possible to draw definite conclusions for the individual case as can be done with the results of fenestration. This

Fritz Zöllner

is due to the plastic operation being, in most cases, combined with a curative operation. Two factors act together, therefore, upon the result: healing the basic disease, and altering the sound-conducting apparatus according to a fixed plan. They may act in the same sense, but also in opposite senses. Only when it can be established, in the individual case, how much of the sound-conducting apparatus continues to function after the treatment of the ear condition can it be judged whether the best possible result is obtained by the operation.

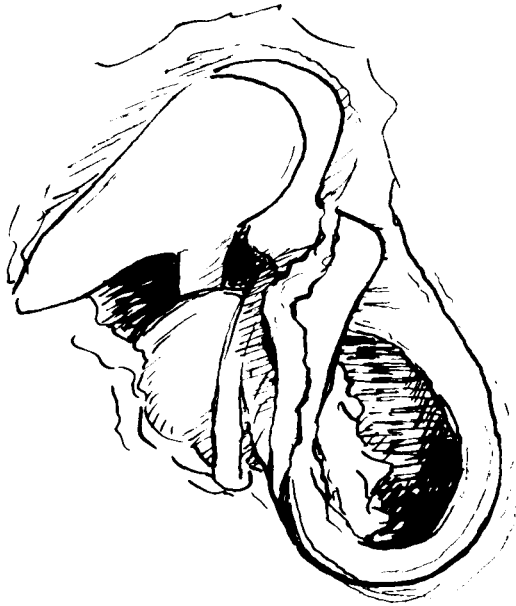


FIG. 1a.

Thus, for example, a simple attico-antrostomy mostly improves hearing if it was bad before, because the obstacle to conduction was removed by eliminating active disease. Actually the state of the sound-conducting apparatus did deteriorate a little; for the original favourite conditions of the closed air-filled attic can no longer be restored. In other cases comparatively good hearing becomes automatically worse after a healing operation because pathologic processes may influence, by chance, the capacity for hearing in a favourable sense. This very often occurs with cholesteatoma. Some of these patients hear, so to speak, by their cholesteatoma. Fig. 1(a) shows the condition at operation with 1(b) the audiograph before and after the operation on a patient who suffered from a secondary cholesteatoma. This had penetrated through the upper posterior quadrant of the tympanic membrane destroying the articulation between the stapes and incus. The small cholesteatoma formed a connection between the damaged auditory ossicles. If it was removed there must

Plastic Surgery of Sound-Conducting Apparatus

follow a loss of hearing, the chain being interrupted. If the interrupted chain is restored, or as in this case, had to be removed because of the cholesteatoma in the niche of the stapes, and replaced by a graft the starting point of the rehabilitation is not 30 db. but 60 db. Mere consideration of the relative value for threshold before and after the operation does not really indicate the value of these manipulations. We find the similar situation in cases of complete destruction of the sound-conducting apparatus by cholesteatoma or radical operations when deformities acting

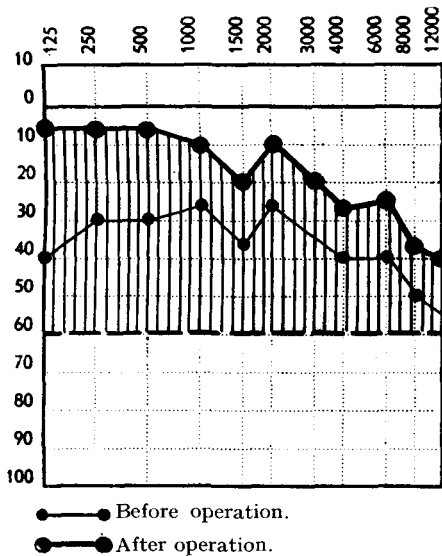


FIG. 1b.

like a prosthesis damp down one of the secondary membranes and, thus, cause relatively good hearing but only for a short time. In this case also, the threshold for the hearing after the plastic operation is actually worse than the one obtained before the operation. It therefore seems correct to divide the cases into groups according to the kind of new-formed sound-conducting apparatus, and then, to find out whether the optimum of hearing possible with this arrangement was obtained. The experiences we have been making up to now with sound-conducting plastics enable us to set up such standards.

I call the patients, where there is a total loss of the tympanic membrane and where both windows are bare, "Fensterhörer", that is patients who hear through the membrane of the oval and round windows only. In this group hearing is only possible because of the small difference between the impedance of the two windows. In such cases the threshold lies 50-60 db. above normal. In most cases hearing can be improved by fitting a prosthesis. A total plastic operation is made as described by Moritz Wullstein

Fritz Zöllner

and Zöllner, the aim of which is primarily to shut off one of the windows.
 What can be the optimum level of hearing obtained by isolated reception

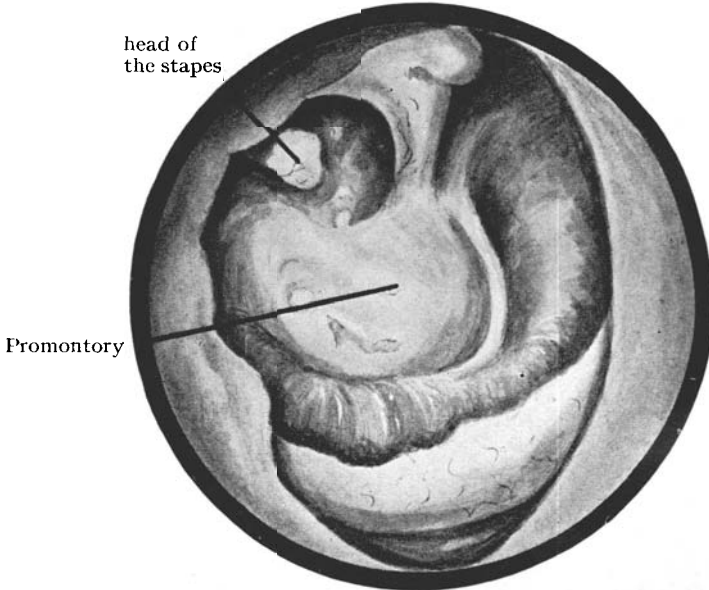


FIG. 2a.

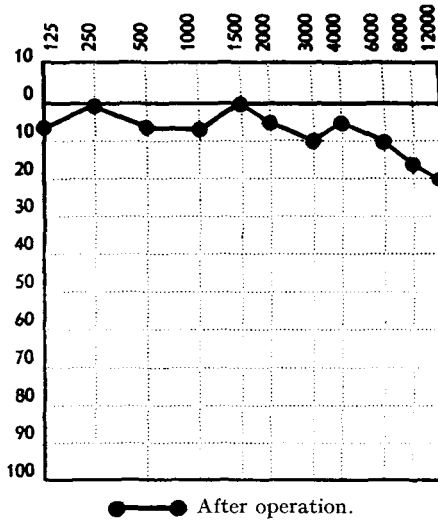


FIG. 2b.

of sound through the oval window? From experiences made with the fenestration technique—and it is known that the principle of sound-conduction is the same—we are inclined to agree with Carhart that the optimal hearing lies at 24 db. However, by experience we can say that

Plastic Surgery of Sound-Conducting Apparatus

it is better after plastic surgery for in some cases it lies above the 24 db. line. We partially explain this by the columella effect aimed at from the very beginning both by Zöllner and by Wullstein, that is: vibration of the new membrane, and transmission of the vibration into the oval window.

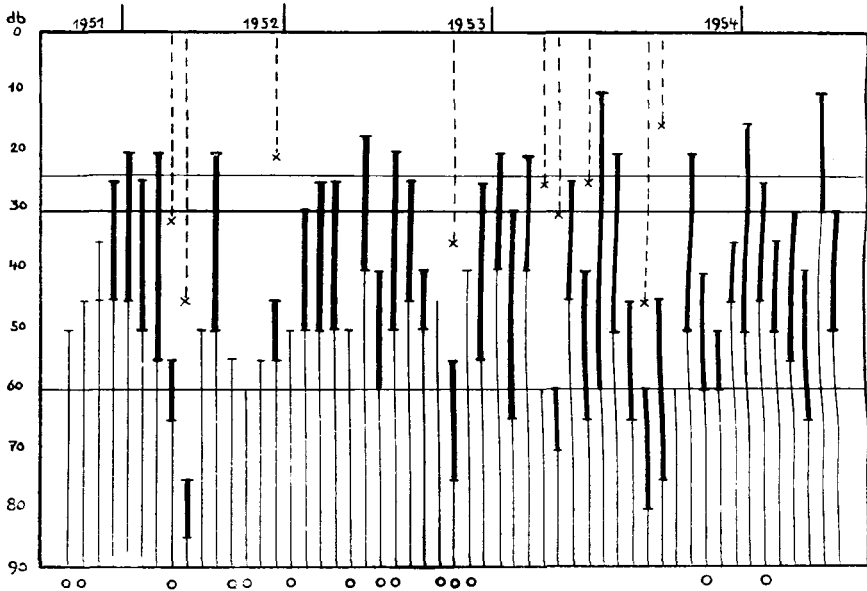
Now, is such an effect of the membrane really necessary to produce a threshold of 24 db.? Though I do not deny the favourable effect of such membrane action, and always try to obtain it, it seems to me that even without the so-called membrane effect, a greater gain in hearing is obtained by acoustic separation of the two windows than by the fenestration operation for otosclerosis. Fig. 2 shows the otoscopic state and audiograph of a man whose stapes was completely isolated by a traumatic rupture of the tympanic membrane with destruction of the joint with the incus by a small secondary cholesteatoma: the remainder of the drum membrane covered the lower part of the tympanum only, just as is now attempted artificially by a total plastic operation of the tympanic membrane. Such spontaneous plastic results are sometimes found after inflammatory lesions and radical operations. Observation of these facts and the good hearing resulting induced me to create similar conditions artificially, by means of plastic measures. My first observations with the stapes in contact with the tympanic membrane made me think of an effect like a columella; but further observations like this one show that even without this columella effect there can be incredibly good hearing, the whispered voice being heard at a distance of about 7 feet. Probably the entrance of the sound in the natural way, through the oval window, is more effective, than the one through the "fenestra novovalis". Therefore, we can form a group in which it is immaterial whether there is a stapes or not; the substitution of the sound conducting apparatus by a graft suitably placed should lead to the 24 db. level of hearing. The cases in Table I are selected from this point of view. There are 53 cases of total plastic operations available, some of which have been treated for more than 3 years, the shortest period being several months after operation so that the success appears more or less established. The thick lines mark the gain in hearing due to operation. In cases where hearing before the operation was lower than 60 db., the inner ear is affected also. The loss of the bone conduction is marked by interrupted lines. The db. values indicate the average hearing for the speech frequencies. In 40 cases (78 per cent.) the gain of hearing obtained was at least 10 db. and up to the maximum of 50 db. If, as afore said, the starting point were at the 60 db. limit, the average gain of hearing would probably be higher. In 24 cases (47 per cent.) the 25 db. limit was reached or exceeded. Among the 12 optimal cases there are several where the crura of the stapes were missing and therefore where there was no columella effect. The circles mark these cases where the flap was partially or completely destroyed by post-operative suppuration. This fact explains the majority of the failures; yet,

Fritz Zöllner

in spite of considerable perforation some patients had a certain gain of hearing because the residue of the flap acted as a prosthesis. There are more circles indicating more failures in the earlier cases. This might suggest that with the passage of time there are more recurrences of infection, which destroy the good results of the plastic operation. Actually there were only a few such cases as in several of the early cases the flap was damaged shortly after the operation because the technique was imperfect.

On the other hand, there were a few failures where adhesions prevented the air from reaching the round window.

TABLE I.
RESULTS OF TOTAL PLASTIC REPAIR OF LARGE PERFORATIONS.



There were some cases which, though considerably improved, did not reach the 25 db. line and in which there was no perceptible deafness. It must be assumed in these cases that the impedance of the middle ear had increased. This may be due to cicatrization before the operation or to scarring following a plastic operation. It is usually possible to test these cases during the operation, by fitting prostheses and by using sound probes. As several causes of reduced vibration can be removed during the operation, a favourable result can only be obtained by testing the function of the two windows at intervals during the operation. We made many such tests, and can say that in most of the cases the windows can be sufficiently mobilized, and a bad result is mostly due to scarring and contraction of the flap. Recognition of this fact is of the utmost importance

Plastic Surgery of Sound-Conducting Apparatus

for the further improvement of the technique. On the whole I believe we can be encouraged by the results so far obtained.

I should like to make some remarks about the technique of plastic operations. The technique of the operation is facilitated by recognition that the normal reaction of the membrane is an essential for good results. The greatest difficulty lies in bridging over an air-filled cavity by a graft. At the beginning most of the failures arose from partial or total necrosis of implanted tissue. The smaller the bridge part of the flap the better it will heal. At first we used pedicle grafts and later relatively large and thick free grafts. We are now using many rather smaller ones. Big thick flaps some-

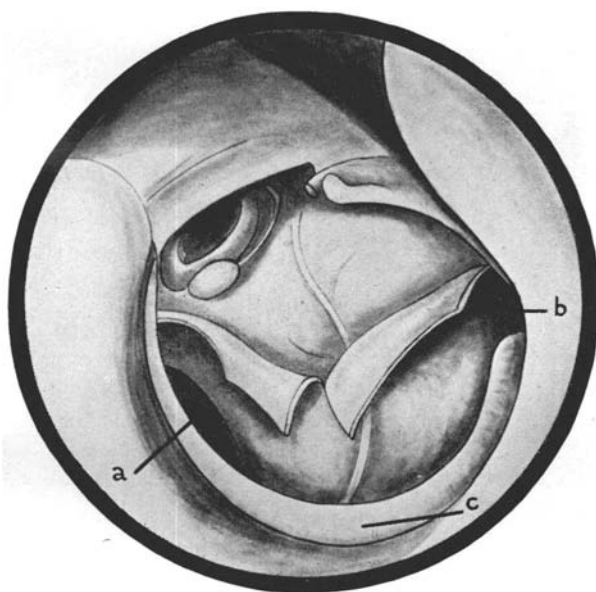


FIG. 3.

The prepared bed for the skin graft.

(a) round window.

(b) opening of the eustachian tube.

(c) remains of the tympanic membrane.

times cause chronic irritation or inflammation, probably because the ear cannot cope with the mass of tissue implanted. In my experience quick and good healing depends upon this plastic bed being formed cautiously, and the open groove made narrow (Fig. 3). The size and form of the flap must be chosen individually according to what is still left of the tympanic membrane, and whether the stapes still exists, or the niche is empty (Fig. 4). If this latter is the case, the delicate epithelialized niche is left uncovered, and the graft fastened only to the promontory of the tympanic cavity. If the crura of the stapes are missing, and if the epithelium of the niche must be removed, the free edge of the plastic flap is

Fritz Zöllner

fixed into the niche. Only in cases where there is still a stapes, the graft must be big enough to be laid over and on the mass of the petrous bone. In this case also, it is best to freshen a part of the promontory, to provide a bed for the flap and thereby assure its nourishment. The chances of healing are much higher if the annulus fibrosus of the tympanic membrane remains. In such cases we cautiously remove the epithelium from its outer surface so that the vessels are not damaged, and lay on it a small overlap of the flap. If there is no annulus, the skin of the external auditory meatus must be freshened and if necessary the shape of the graft adjusted by excising a small wedge shaped portion from its periphery. X
^

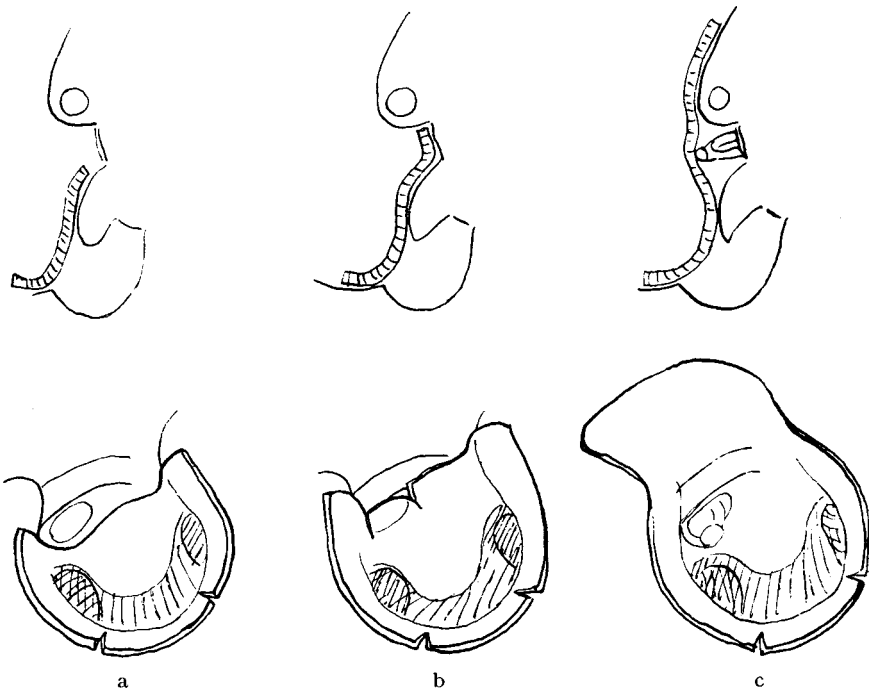


FIG. 4.

Great difficulties may arise when the inferior part of the tympanum and the eustachian isthmus are totally or partially filled by adhesions. I tried to implant conjunctiva and, at first did not close the tympanum by a graft, so that I could observe what became of the implant. I found that the latter is slowly pushed aside by sclerotic tissue. I am, therefore, very careful with experiments concerning implantations of all kinds of mucous membrane and amnion and try wherever possible to obtain epithelization from the remains of the local epithelium.

If there is little epithelium left or if it is oedematous or polypoid, we first clean up the ear, and do not complete the plastic operation until the

Plastic Surgery of Sound-Conducting Apparatus

tympanum is healed. If adequate epithelium remains we try to finish the plastic manipulation at once, and Wullstein suggests, insert gelatine foam into the cavity, which must be preserved. In general the results were not bad, but, as is shown by statistics, it is by no means certain that the air spaces will be kept open by means of such foam. Recently I have therefore tried a method which I hope will give good results even in cases of adhesions of the isthmus. It consists of a packing which can be removed through the eustachian tube. A typical case was a female patient whose deformed hypo-tympanum we had already tried to open, but without success. A small portion of the tympanic membrane remained in the lower part of the tympanum, was adherent to its inner wall and was not affected by inflation. A curved incision was made in this remnant stretching from the mouth of the eustachian tube to the round window. The hypo-tympanum was filled with gelatinous and cystic tissue. By excising the cysts we made rather a wide cavity partially lined with epithelium. Working from the tympanum we explored the ostium of the tube, after similar cystic tissue had been removed. Some very fine solid threads were passed through the eye of a thin flexible probe. The probe, together with the silk threads following, was passed through the eustachian tube into the nasopharynx and then, under visual control by the nasopharyngoscope, was drawn out through the nose leaving the silk threads in the tube and in the tympanic cavity. To prevent the packing from slipping out of the tube too soon, a knot of the finest catgut was tied on the thread, and loosely fixed in the isthmus of the tube by gently pulling the thread down the tube. The hypo-tympanum was loosely packed with the rest of the threads, and finally the gap in the tympanic membrane was closed by a narrow thin flap (Fig. 5). From our experiences during the short time we have been using this method we can but say that this kind of packing is well tolerated, that the thread is not extruded too soon as happened with my first experiments which were made without the knot of catgut, and I could remove it without difficulty after 8 to 10 days had passed. The comparatively solid packing of the hypo-tympanum, by silk thread gives the transplanted tissue a much surer and evener bed than is possible with the too soft gelatine foam. The healing processes of the transplanted tissue were not interrupted in the four cases we have observed up to now, and the improvement in hearing was as good as was hoped. It is not always easy, of course, to pass the probe and thread through the tube. Though the cases treated in this manner were not numerous, I found out that every time the hypo-tympanum showed adhesions the tube was also abnormal. Probing should be done very cautiously so as not to make a false passage. The emergence of the probe should always be visually controlled through the nasopharyngoscope. This instrument is indispensable for finding and grasping the probe in the pharynx. If sounding is not possible from the ear to the nose the opposite way is sometimes successful.

Fritz Zöllner

This technique is not very easy but we are glad that we have found a way to succeed even in cases of adhesions of the tube which could not be treated before. The group of patients upon whom the total plastic operation is performed represent the greatest amount of change in the sound-conducting apparatus except for those cases with the further complication of bone closure of one of the windows. Simple or central perforations of the tympanic membrane present the least problem. They are easily closed and normal hearing regained, if the requirements, that the disease be completely controlled and the continuity of the ossicular chain behind the tympanic membrane be demonstrated by means of the

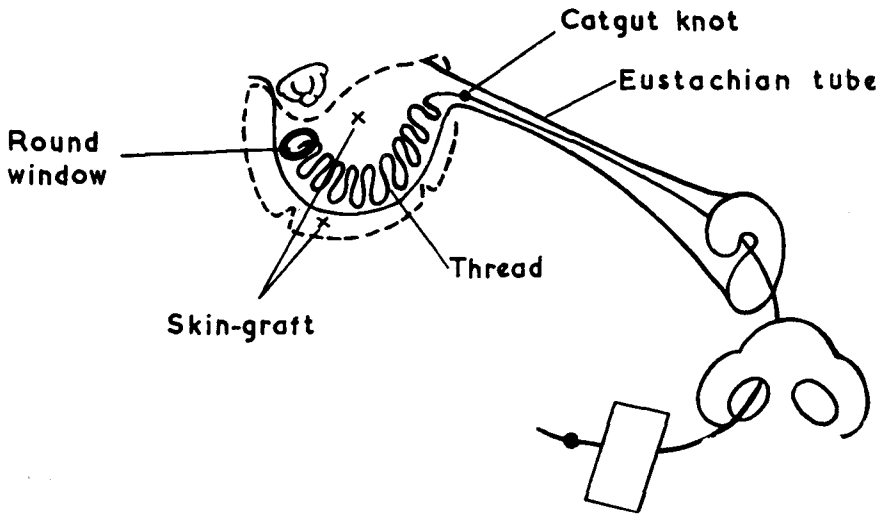


FIG. 5.

The arrangement of the thread packed into the hypo-tympanum and brought out through the eustachian tube and the nose.

acoustic probe, are fulfilled. The after history of 22 patients operated on during the last 2 years makes it clear that this aim is not always fully reached though it should be possible to approximate it. In all these cases primary healing occurred with a good gain of hearing, even in those who were suffering from big central perforations—as shown in Fig. 6—and whose promontory of the tympanic cavity had to be freshened to form a good bed for the flap. Table I shows that seven patients suffered from a second perforation following reinfection, and the improvement in hearing was totally or partially lost. The cases of central perforation with mucopurulent discharge are very often associated with chronic inflammation of the nose and pharynx, and heal up less easily than the cases with cholesteatoma. For this reason we now only operate on those patients whose ears had been dry for some time, and whose nose and nasopharynx

Plastic Surgery of Sound-Conducting Apparatus


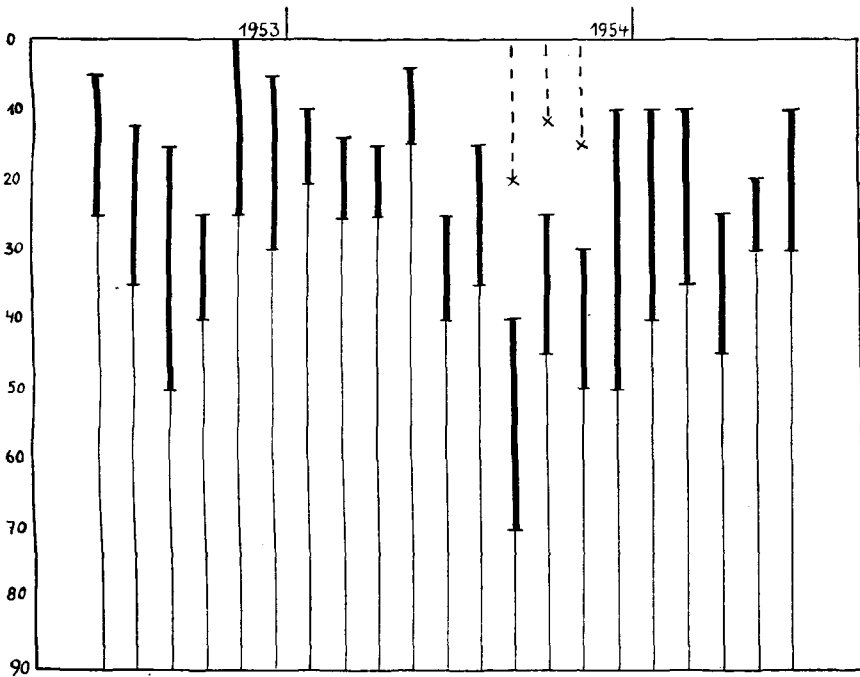


FIG. 6.

TABLE II.
ENDAURAL PLASTIC REPAIR OF CENTRAL PERFORATIONS.



Fritz Zöllner

have been treated as required. Between the two extremes—the repair of a total loss of tympanic membrane and ossicles and the patching of a comparatively small central perforation—there are cases where a considerable part of the drumhead and of the ossicular chain can be used in the reconstruction. We have become more and more conservative and attempt to leave as much as possible of the original structure consistent with eliminating the likelihood of recurrence of the original disease. This practice is influenced by the two following considerations.

1st. The observation of recurrences shows that the original tissues are more resistant to inflammation than the implanted graft.

2nd. The membrane effect, corresponding to the original idea of the columella action is easier to achieve if there remains a reasonable framework of the ossicular chain and a useful part of the membrana tensa.

It will scarcely be possible to restore a normally vibrating chain of auditory ossicles if it is already defective; yet very often an existing or restored tympanic membrane can be brought into contact with the stapes through a comparatively stiff chain so that transmission similar to that of columella is produced. In such cases a hearing level between normal and 25 decibels loss can be expected. Actually the results in this group are better than those of the total reconstruction. The same observation is made by Wullstein. Naturally quite normal hearing cannot be expected as even attico-antrotomy does damage the sound-conducting apparatus. No matter whether the exposed auditory ossicles are covered by a plastic flap or—as is mostly done—the attic be left open to prevent recurrence: it is no longer possible to restore a closed resonating cavity in which the ossicles can freely vibrate. If the malleus and incus are swinging around their normal axis, the head of the malleus and the body of the incus will intercept the vibrations of the air in opposite phase. This surface area is smaller than the surface of the tympanic membrane; comparatively little energy is lost. In fact, hearing is but little reduced in general if the operation is successful. In this group of patients stiffening, or displacement of parts of the chain of ossicles add to the loss of hearing. It is difficult to lay down a definite technique, each case having to be treated according to its own merits, and we are continuously trying to find methods of achieving these ends.

In the majority of cases the incus is destroyed. Fig. 7 shows a case where the stapes and incus were missing completely: there was only the malleus adherent to the anterior wall of the tympanum. As it was supporting the remaining anterior half of the tympanic membrane, we left it in position. Freshening the edges we connected a graft directly with the empty oval window so that a comparatively large membrane was in communication with the latter. Fig. 8a shows a case in which portion of the long process of the incus was missing. There was a complete stapes, but it was fixed in the oval window by scar tissue formation. The stapes

Plastic Surgery of Sound-Conducting Apparatus

was remobilized. To bring it into contact with the malleus again we dislocated the body of the incus, and thus established a new connection between the neck of the malleus and the stapes. The perforation in the tympanic membrane was closed with a graft. Fig. 8*b* shows the gain in hearing. This manoeuvre was repeated in several cases. It seemed to me of greatest importance that the incus should remain with its normal connections. Otherwise it would behave just like a bone chip, and would become fixed to the surrounding structure. Fig. 9 shows caries of the articular head of the stapes which was healed up. The auditory ossicles were covered with delicate mucous membrane. The incus and stapes were only attached by a thin strand of connective tissue. Testing with an

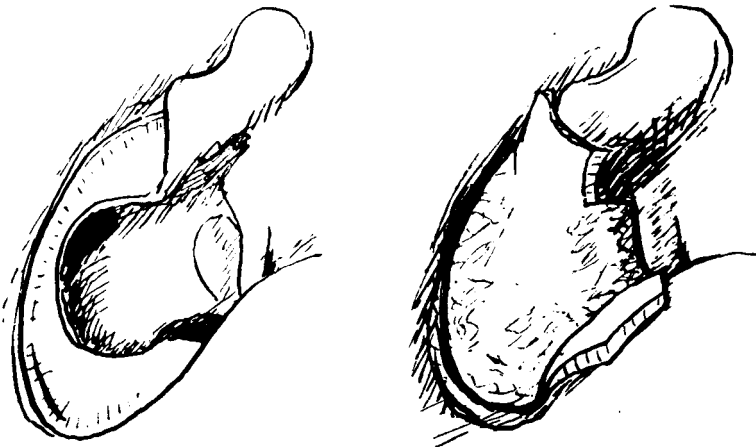


FIG. 7.

acoustic probe which was placed upon the umbo of the tympanic membrane proved that the sound conduction was very bad. The reflex of the stapedius was positive; the stapes was distinctly seen moving in the niche of the window, but the long process of the incus did not move. In this case the posterior quadrant of the tympanic membrane was remobilized and brought into direct contact with the stapes.

If the crura of the stapes are missing it is rather difficult to establish a communication similar to the columella. Maybe it would be useful to introduce a small artificial rod into the empty niche of the window as described by Wullstein. In this type of case he reported good hearing results. As for me, I do not like implanting artificial material into the ear, my own experience with rhinoplasty having shown that wherever such material is implanted into movable parts, it is slowly pushed off by atrophy caused by pressure. However, the conditions in the ear may be more favourable to this artificial implant and it will be interesting to watch the ultimate progress of this type of plastic manipulation as time passes. Free

Fritz Zöllner

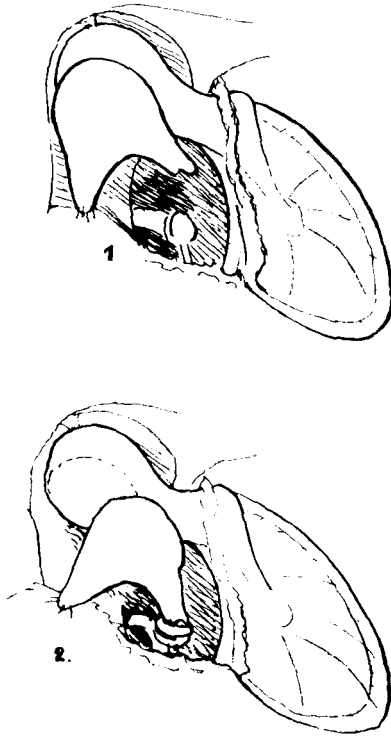


FIG. 8a.

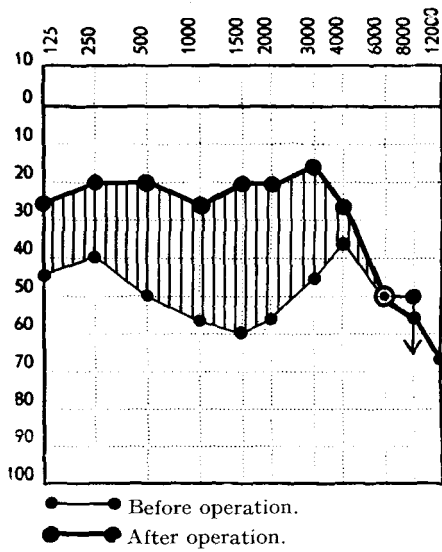


FIG. 8b.

Plastic Surgery of Sound-Conducting Apparatus

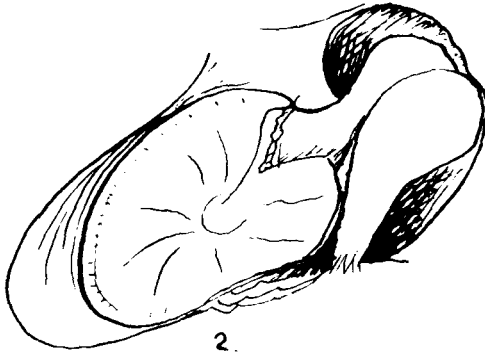
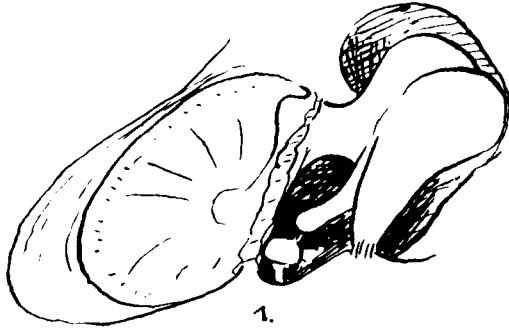

FIG. 9a.

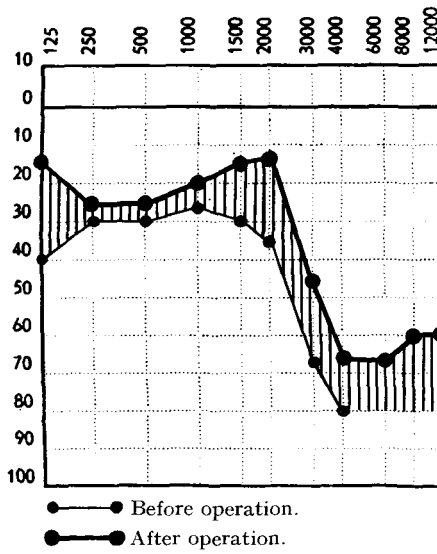


FIG. 9b.

Fritz Zöllner

implantation of bone is not advisable; for implanted bony tissue is invariably transformed and adhesions and fixation are to be expected. Therefore we prefer to a direct connection between the tympanic membrane and the niche of oval window just as we do with a complete replacement of the drumhead. We therefore either freshen the tympanic membrane or, if the upper posterior quadrant is missing, implant a small plastic flap to connect the tympanic membrane with the niche of the window.

I am not yet able to give statistics about this group of cases, as they are not yet all followed up and the estimate of success is difficult owing to the variation of the operation. Altogether 120 attic-antrotomies were done in 3 years, mostly with different forms of plastic operations. In each case, even in a simple attic opening the binocular operating microscope was used for exact investigation. This careful method of observation together with the ability to re-establish the function in various defects of the conductive apparatus by plastic measures has radically improved our treatment of chronic suppurative diseases of the ear.