

# Bicarbonate therapy for unstable propafenone-induced wide complex tachycardia

Jeff Brubacher, MD

## ABSTRACT

A previously healthy 73-year-old woman presented to hospital with acute atrial fibrillation. After intravenous procainamide failed to restore sinus rhythm, she was treated with 300 mg of oral propafenone and discharged with a prescription for propafenone and propranolol. Six hours later she took 150 mg of propafenone as prescribed. Within 1 hour she became dyspneic and collapsed. On arrival in hospital she was unconscious, with a wide complex tachycardia and no obtainable blood pressure. After defibrillation and lidocaine, she converted to a wide complex sinus rhythm, but remained profoundly hypotensive despite intravenous epinephrine and dopamine. Hypertonic sodium bicarbonate ( $\text{HCO}_3$ ) was administered and, shortly thereafter, her blood pressure increased, her QRS duration normalized and her clinical status improved dramatically. In this case of severe refractory propafenone-related cardiac toxicity, intravenous  $\text{HCO}_3$  led to a profound clinical improvement. Emergency physicians should be familiar with the syndrome of sodium-channel blocker poisoning and recognize the potentially important role of bicarbonate in its treatment.

**Key words:** propafenone; sodium channel blockers; anti-arrhythmia agents; adverse effects; atrial fibrillation

## RÉSUMÉ

Une femme âgée de 73 ans auparavant en bonne santé s'est rendue à l'hôpital pour une fibrillation auriculaire aiguë. La procainamide intraveineuse n'ayant pas réussi à rétablir le rythme sinusal, la patiente reçut 300 mg de propafénone per os et fut renvoyée chez elle avec une ordonnance pour de la propafénone et du propranolol. Six heures plus tard, elle prit 150 mg de propafénone tel que prescrit. Dans l'heure qui suivit, elle devint dyspnéique et s'effondra. À son arrivée à l'hôpital, elle était inconsciente, en tachycardie à complexe large et il était impossible de prendre sa tension artérielle. Après la défibrillation et l'administration de lidocaïne, la tachycardie se changea en rythme sinusal à complexe large. Par contre, la patiente demeura profondément hypotendue malgré l'administration intraveineuse d'épinéphrine et de dopamine. On lui administra du bicarbonate de sodium hypertonique ( $\text{HCO}_3$ ) et, peu de temps après, sa tension artérielle augmenta, la durée du complexe QRS redevint normale et son statut clinique s'améliora énormément. Dans ce cas de toxicité cardiaque réfractaire grave liée à la propafénone, l' $\text{HCO}_3$  intraveineux conduisit à une amélioration clinique remarquable. Les médecins d'urgence devraient se familiariser avec le syndrome de l'empoisonnement par un bloqueur des canaux sodiques et reconnaître le rôle potentiellement important du bicarbonate dans le cadre de son traitement.

Vancouver General Hospital, Vancouver, BC, and Division of Emergency Medicine, Department of Surgery, University of British Columbia, Vancouver, BC, and British Columbia Drug and Poison Information, Vancouver, BC

Received: Feb. 26, 2004; final submission: June 23, 2004; accepted: June 27, 2004

*This article has been peer reviewed.*

*Can J Emerg Med* 2004;6(5):349-56

## Introduction

Atrial fibrillation (AF) is a common cardiac rhythm disturbance that is associated with increased risks of cerebral vascular accident and death. There are an estimated 2 to 3 new cases of AF per year for every 1000 persons between the ages of 55 and 64, and the incidence of new cases increases with age to about 35/yr for every 1000 persons between the ages of 85 and 94.<sup>1</sup> Compared with patients in sinus rhythm, men with AF have a relative risk of death of about 1.5 and women have a relative risk of 1.9.<sup>2</sup>

Many patients with AF seek care in the emergency department (ED), where management may include rate control, chemical or electrical cardioversion and anticoagulation. Beta-blockers or calcium-channel blockers, administered intravenously (IV), are effective for rapid rate control. Digoxin is often used for long-term rate control, but its delayed onset of action makes it unsuitable for ED use.<sup>3,4</sup> ED cardioversion is generally reserved for unstable patients and those with AF of less than 48–72 hours duration. Thromboembolic risk increases in patients who have been in AF for a longer period of time; consequently these patients are typically treated with anticoagulants for 3 weeks prior to cardioversion.<sup>5</sup> Some investigators have documented the appearance of left atrial thrombus in patients with AF of less than 72 hours duration, hence recommend universal anticoagulation or left atrial imaging prior to cardioversion.<sup>6–8</sup>

Cardioversion may be achieved electrically or chemically. Electrical cardioversion is preferred by many clinicians but requires procedural sedation. Agents available for chemical cardioversion include Vaughan Williams Class Ia sodium-channel blockers such as procainamide and quinidine, Class Ic sodium-channel blockers such as propafenone and flecainide, and Class III agents such as amiodarone and sotalol. Recent research shows that, in patients at risk of recurrent AF, long-term antidysrhythmic therapy to maintain sinus rhythm does not improve outcome or reduce stroke risk; in fact it may increase death and cardiovascular morbidity.<sup>9,10</sup> These findings do not necessarily apply to patients with first onset AF, so most clinicians will attempt to restore sinus rhythm in patients with new-onset AF and those who cannot tolerate the symptoms associated with recurrent AF.<sup>5,11</sup>

Propafenone is a Vaughan Williams Class Ic antidysrhythmic agent that is frequently used in the management of new onset AF. Two reviews of published trials of oral propafenone for the conversion of AF concluded that a single 600-mg oral dose of propafenone is highly effective and safe for the conversion of AF to sinus rhythm. Re-

ported adverse effects were transient dysrhythmia, reversible QRS-complex widening, transient hypotension and mild noncardiac side effects. The transient dysrhythmias occurred chiefly at the time of conversion and included atrial flutter, bradycardia, pauses and junctional rhythm. No life-threatening proarrhythmic adverse effects were reported in either review.<sup>12,13</sup> We report a case of refractory life-threatening cardiac toxicity that responded to hypertonic sodium bicarbonate (HCO<sub>3</sub>) following the use of 450 mg of propafenone in a previously healthy woman with new onset AF.

## Case report

A previously healthy 73-year-old woman presented to our institution, an urban tertiary care referral centre, at 0930h with palpitations and slight dyspnea of 11 hours duration. She denied chest pain or light-headedness, and had no history of prior palpitations, hypertension, diabetes, angina or myocardial infarction. Her only medication was aspirin, 80 mg daily.

On examination, she was alert, oriented and in no distress, with good skin colour and an oxygen saturation of 96%. Her pulse was irregularly irregular at 120 beats/min, her blood pressure was 118/80 mm Hg, her respiratory rate was 18 breaths/min, and she was afebrile. Her lungs were clear to auscultation, and she had no murmurs or extra heart sounds.

An electrocardiogram taken at 1000h showed AF (Fig. 1), and her electrolytes were as follows: sodium 142 mmol/L, potassium 4.3 mmol/L, chloride 109 mmol/L, bicarbonate 22 mmol/L, calcium 2.35 mmol/L, phosphate 1.28 mmol/L, and magnesium 0.76 mmol/L. Troponin and CK-MB assays were within normal limits. Complete blood count, renal function and thyroid stimulating hormone level were normal.

Her heart rate was controlled with IV diltiazem (5 mg) and IV propranolol (4 mg in divided doses). She then received 1000 mg of IV procainamide over 1 hour but remained in AF. A further 200 mg of IV procainamide was given over 20 minutes, without effect. At 1207h, after the second procainamide infusion, she remained in AF with a pulse of 100 beats/min and a QRS width of 80 milliseconds (Msec). Ninety minutes after the infusion, her blood pressure was stable at 130/90 mm Hg. The cardiology service was consulted, and at 1524h she was given 300 mg of oral propafenone. Within half an hour she developed warmth and flushing but had no objective findings. She was observed for 3 more hours and discharged at 1830h with a prescription for propafenone and propranolol. At the

time of discharge, her pulse was 90 beats/min and her blood pressure was 125/82 mm Hg.

At 2100h (9 hours after the second procainamide infusion) she took 150 mg of propafenone as prescribed. Within 1 hour she became dyspneic and vomited. The paramedics were called and found her to be in AF with runs of wide complex tachycardia.

On arrival in hospital at 2254h she was unconscious and in sustained ventricular tachycardia (Fig. 2) with palpable femoral pulses but no obtainable blood pressure. After defibrillation and lidocaine, she converted to sinus rhythm with a QRS width of 158 Msec (Fig. 3). She was intubated and ventilated. For the next 20 minutes she remained in wide complex sinus rhythm with palpable femoral pulses but no obtainable BP despite 3.6 mg of epinephrine and a dopamine infusion at 25 µg/kg/min.

A pill count confirmed that 1 tablet of propafenone and no propranolol tablets had been taken. Because she had taken propafenone, a known sodium-channel blocker, we elected to administer HCO<sub>3</sub> by IV. Immediately after 100 mEq HCO<sub>3</sub> her BP rose to 72/40 mm Hg and her QRS width narrowed to 136 Msec. After another 100 mEq of HCO<sub>3</sub> her BP rose to 94/40 mm Hg and the QRS narrowed further to 104 Msec (Fig. 4).

An arterial blood gas analysis performed shortly after cardioversion and before bicarbonate administration

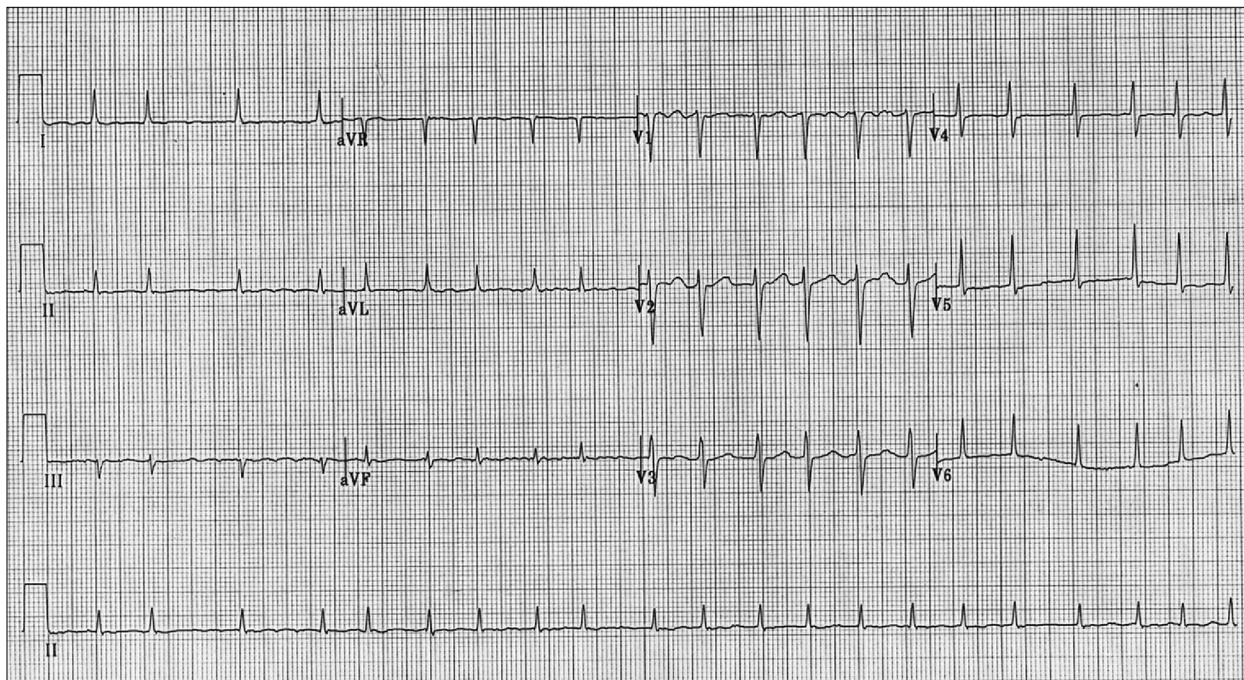
showed a pH of 7.29, Pco<sub>2</sub> of 20 mm Hg and Po<sub>2</sub> of 122 mm Hg. Subsequent testing revealed that troponin, CK-MB, potassium, magnesium and calcium levels remained normal. Blood drawn immediately after the resuscitation (12 hours after the procainamide infusion was completed) was assayed for procainamide and *N*-acetyl procainamide (NAPA). Using a fluorescence polarization immunoassay process (Abbott Diagnostics AxSYM, Abbott Laboratories, Abbott Park, Ill.), procainamide and NAPA levels were undetectable. The patient was admitted to the cardiac care unit and had an uneventful recovery without further dysrhythmias.

## Discussion

Propafenone is a Vaughan Williams Class Ic antiarrhythmic agent. These agents act by slowing sodium influx into myocytes through voltage gated sodium channels, and are referred to as sodium-channel blockers. They differ in their affinity and duration of binding to the sodium channel, in their effects on potassium and calcium channels, and in other effects such as anticholinergic properties.

### *Sodium-channel blocker toxicity*

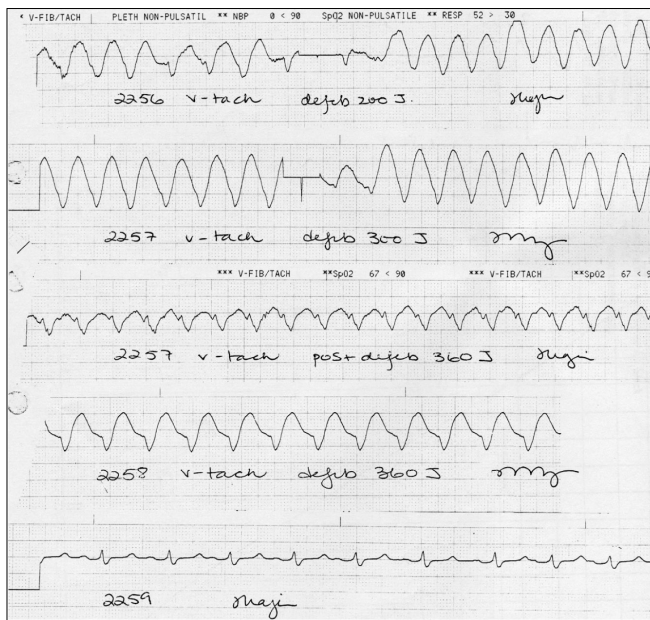
Vaughan Williams Class I antidysrhythmic agents are subdivided into Ia, Ib and Ic classes, depending on how they



**Fig. 1.** Results of ECG performed at 1000h, during patient's first visit to the ED. She had presented at 0930h with new onset atrial fibrillation (AF) (120 beats/min). She remained in AF even after a total of 1.2 g of procainamide had been administered. The procainamide infusion was finished at 1207h. She was given 300 mg propafenone orally at 1524h and discharged at 1830h with a prescription for propafenone and propranolol.



interact with sodium and other channels. Class Ib agents bind weakly and briefly (<1 sec) to sodium channels and do not widen the QRS interval nor prolong depolarization.

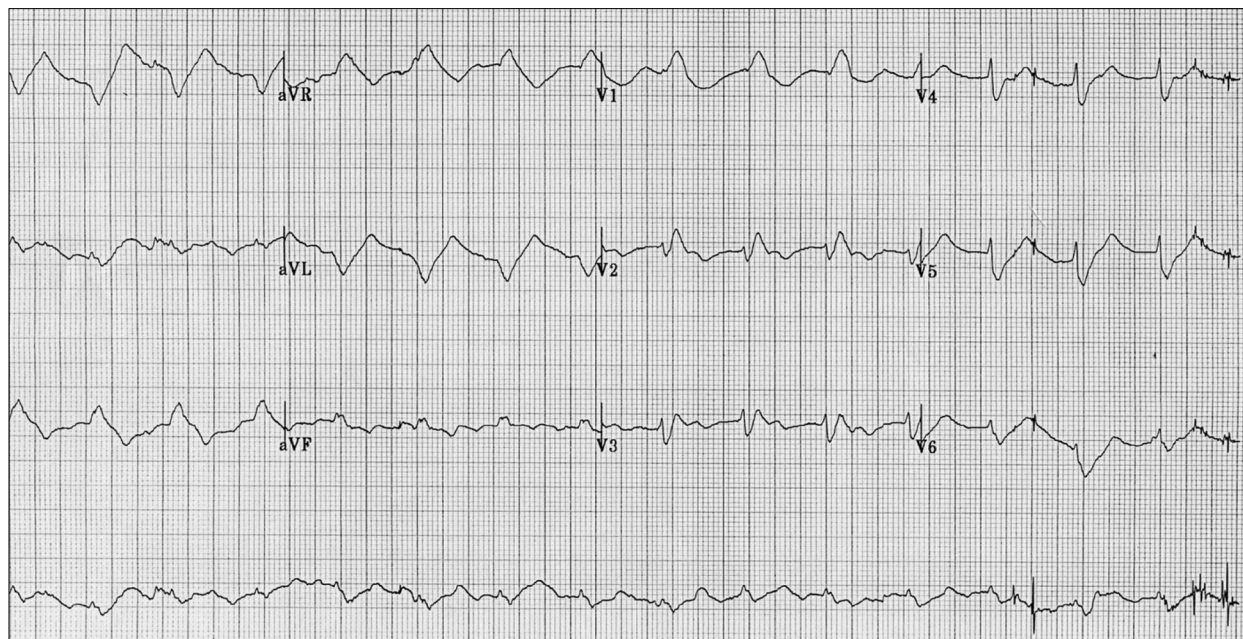


**Fig. 2.** Results of 2nd ECG, taken at 2255h. After her first discharge, at 1830h, the patient took a further 150 mg of propafenone at 2100h at home and subsequently developed nausea, vomiting, malaise and shortness of breath. Paramedics found AF with runs of ventricular tachycardia. She was unconscious, with sustained ventricular tachycardia on arrival in ED at 2254h.

Class 1a agents are more potent sodium-channel blockers and more likely to cause QRS widening. These agents and their metabolites also inhibit potassium channels, resulting in a prolonged QT interval. Class Ic agents are the most potent sodium-channel blockers but do not affect potassium channels; therefore these agents cause QRS prolongation without QT prolongation.<sup>14</sup> In addition to the Class I antiarrhythmic agents, numerous other drugs, including tricyclic antidepressants, amantadine, carbamazepine, antihistamines (e.g., diphenhydramine), beta-blockers (propranolol, acebutolol and oxprenolol), cocaine and propoxyphene, have sodium-channel blocking properties. Many other drugs can cause sodium-channel blockade when taken in overdose.<sup>15</sup>

Tricyclic antidepressants remain the most common cause of sodium-channel blocker poisoning. Because tricyclics also have anticholinergic and adrenergic effects, tricyclic overdoses almost always cause tachydysrhythmias. In contrast, Koppel and colleagues<sup>16</sup> reported that Class Ic agents were far more likely to cause bradydysrhythmias, with about two-thirds of propafenone-poisoned patients experiencing bradycardia. Other authors have also reported that sodium-channel blockers devoid of anticholinergic or adrenergic effects (e.g., propafenone) tend to cause bradycardia and conduction blocks.<sup>15</sup>

Sodium-channel blocker overdoses cause hypotension, prolonged QRS duration, ventricular dysrhythmias, depressed mental status and seizures. These agents are asso-



**Fig. 3.** Results of 3rd ECG, taken at 2300h, before administration of bicarbonate. After standard ACLS the patient converted to a sinus rhythm with a wide QRS complex (158 Msec) but no palpable pulses. She remained profoundly hypotensive for the next 20 minutes despite fluids and pressor support.

ciated with a much higher death rate than most other poisonings,<sup>15,17</sup> and the Class Ic antidysrhythmics are particularly toxic. Koppel and colleagues published a series of 120 cases of poisoning with Class Ic agents, including 34 patients with propafenone toxicity.<sup>16</sup> The mortality rate in this series was 22.5%, a striking contrast to the 1% mortality rate associated with overdoses in general. In this series the earliest symptoms were nausea and vomiting. Cardiac conduction abnormalities included atrioventricular (AV) block, bradycardia, electromechanical dissociation and asystole.

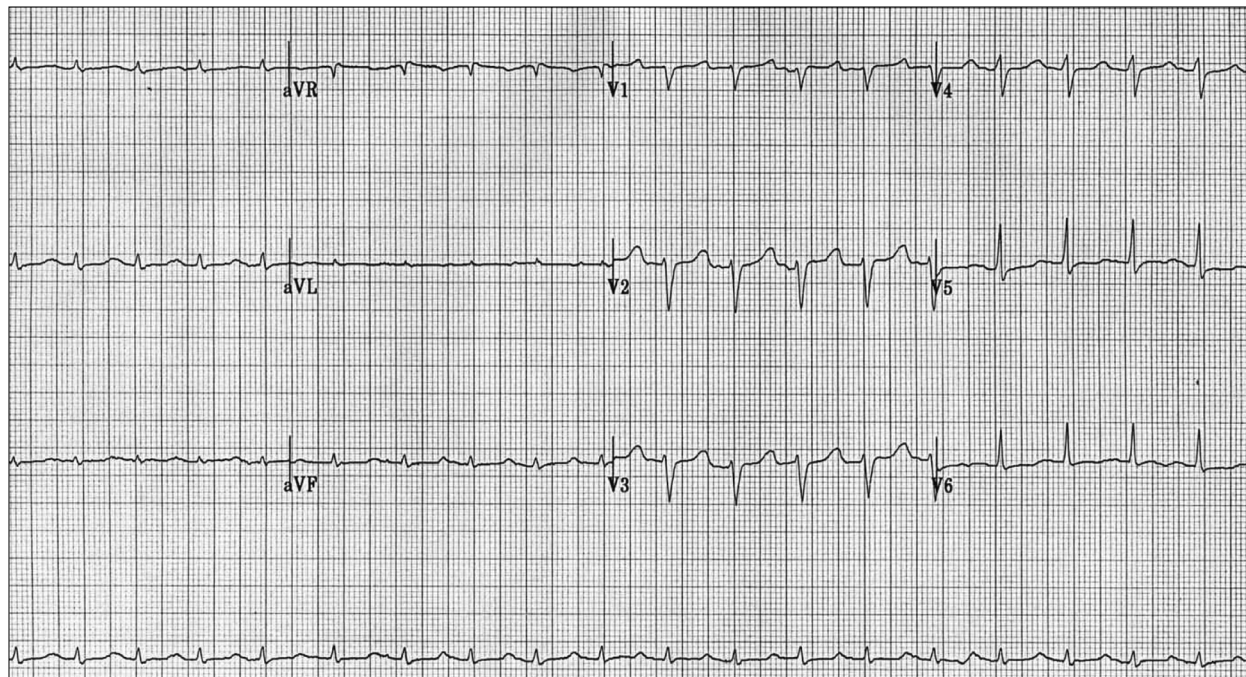
Patients who suffer cardiac arrest after sodium-channel blocker poisoning seldom respond to resuscitative measures, and in Koppel and colleagues's series, only 2 of 29 patients were resuscitated from cardiac arrest following Class Ic poisoning. In this series, bicarbonate was given to all patients in cardiac arrest and to 8 patients with severe bradycardia, but its effects on QRS prolongation and other parameters were not documented. Previous reports of acute propafenone overdose also describe hypotension, QRS prolongation, cardiovascular collapse and, in most cases, seizures. These symptoms occur both in children<sup>18–20</sup> and in adults.<sup>21–28</sup>

#### *Propafenone's therapeutic toxicity*

In therapeutic doses, propafenone may cause non-cardiac and cardiac toxicity. Non-cardiac adverse effects include

cholestatic hepatitis,<sup>29–34</sup> reactive airway disease,<sup>35,36</sup> agranulocytosis,<sup>37</sup> hemolysis,<sup>38</sup> drug fever<sup>39</sup> and ataxia.<sup>40</sup> Cardiac adverse effects include hypotension, malignant ventricular dysrhythmias and sudden death.<sup>41–48</sup> Buss and coworkers<sup>42</sup> reported a series of 5 patients who developed malignant ventricular dysrhythmias shortly after being started on propafenone. All 5 had underlying cardiac disease (coronary artery disease, cardiomyopathy, or ventricular septal defect) and developed sustained ventricular dysrhythmias 1 to 3 days after the initiation of propafenone. Two of the patients died, but the others responded to defibrillation.

Nathan and colleagues reported the case of a 63-year-old man with severe coronary artery disease who was started on propafenone in a monitored setting for treatment of recurrent ventricular dysrhythmias. After taking only 2 doses (300 mg), his QRS widened from 120 to 140 Msec and he developed frequent runs of ventricular ectopy, followed by refractory ventricular tachycardia and death. Camous and cohorts reported 2 patients who developed widened QRS (400 Msec in both cases) and severe hypotension after propafenone therapy.<sup>43</sup> Scanu and coworkers reported the case of a 5-year-old girl who developed malignant ventricular tachycardia during propafenone treatment for junctional tachycardia. The child had no structural heart disease.<sup>48</sup>



**Fig. 4.** Results of 4th ECG, taken at 2345h, after administration of bicarbonate. With administration of 100 mEq of sodium bicarbonate the patient's pressure increased to 72/40 mm HG and her QRS narrowed to 136 Msec. Following another 100 mEq of sodium bicarbonate her pressure was 94/40 mm HG and her QRS narrowed further, to 104 Msec. She went on to a full recovery.



### **Management of sodium-channel blocker toxicity**

Emergency physicians should learn to recognize and manage patients with sodium-channel blocker toxicity. Importantly, they should be aware that following standard ACLS guidelines may be hazardous, particularly if patients are given another Class Ia antidysrhythmic agent such as procainamide to treat ventricular ectopy. Isolated reports suggest that amiodarone or lidocaine may be beneficial in patients with ventricular dysrhythmias induced by sodium-channel blockers.<sup>16,49</sup> Amiodarone is a potent potassium-channel blocker with weak sodium and calcium channel blocking properties.<sup>50</sup> As such, it is unlikely to exacerbate sodium-channel blocker toxicity. There is a single reported case of flecainide (Class Ic) overdose resulting in treatment resistant ventricular fibrillation that responded to amiodarone.<sup>51</sup> In another case, flecainide-induced ventricular tachycardia responded to a lidocaine infusion, recurred when the infusion was stopped, and was terminated by more lidocaine.<sup>49</sup> Although lidocaine is also a sodium-channel blocker, it is postulated that its fast-on/fast-off binding kinetics allow it to compete for the sodium channel and reverse the toxicity of other more potent sodium-channel blockers such as the Class Ic agents. In an animal experiment lidocaine was as effective as  $\text{HCO}_3^-$  in reversing the QRS prolongation due to cocaine toxicity. Conversely, quinidine, a Class Ia agent, augmented cocaine-induced QRS prolongation in this model.<sup>52</sup>

### **Sodium bicarbonate**

$\text{HCO}_3^-$  is considered by most toxicologists to be the treatment of choice for cardiac toxicity in the setting of sodium-channel blocker poisoning. In Europe, hypertonic sodium lactate is used in place of bicarbonate. Both agents overcome sodium-channel blockade by mass effect and by increasing serum pH, which inhibits binding of at least some sodium-channel blockers to sodium channels.<sup>15</sup> There is evidence that serum alkalinization is beneficial in reversing toxicity from tricyclic antidepressants, cocaine, quinidine, flecainide, procainamide, mexiletine and bupivacaine.<sup>15,53–58</sup> In addition, there is animal evidence and human case reports showing a benefit of bicarbonate in flecainide poisoning.<sup>53,54,56,58,59</sup> It is reasonable to suspect that  $\text{HCO}_3^-$  would benefit patients with propafenone toxicity, but the literature in this setting is limited.

Many reports<sup>16,18,19,23,24</sup> of acute propafenone poisoning mention the use of  $\text{HCO}_3^-$  or hypertonic sodium lactate,<sup>20,27</sup> usually combined with other therapeutic modalities such as pressors, endotracheal intubation, cardiac

pacings and cardiac massage. However, a review of French- and English-language reports of acute propafenone mono-overdose revealed none documenting resolution of hypotension or normalization of QRS duration immediately after the administration of  $\text{HCO}_3^-$  or sodium lactate.<sup>15,16,18–28,60</sup>

Hypertonic sodium lactate or  $\text{HCO}_3^-$  has also been used to treat cardiac adverse effects developing in patients using propafenone therapeutically.<sup>43,48</sup> One report demonstrated that malignant ventricular dysrhythmias in a child using propafenone could be terminated with hypertonic sodium lactate.<sup>48</sup> Another report described 2 patients with propafenone-related cardiac toxicity who responded to a combination of hypertonic sodium lactate and the pressor isoprenaline.<sup>43</sup> Neither report documented blood pressure or QRS duration immediately before and after the infusion of  $\text{HCO}_3^-$  or sodium lactate.

### **Summary**

Our patient's clinical course was typical of sodium-channel blocker toxicity, and the timing of the ventricular dysrhythmias suggests that propafenone was the causative agent, although procainamide may have played a minor role. Procainamide is a potent Class Ia sodium-channel blocker that would aggravate propafenone toxicity, but it has a half-life of only 3–4 hours.<sup>61</sup> Our patient's dysrhythmias developed 9 hours (2 to 3 half-lives) after the end of the procainamide infusion, and neither procainamide nor its metabolite NAPA were detectable in the patient's serum immediately after successful resuscitation.

Of note, the patient had also taken therapeutic amounts of propranolol, a beta-blocker with sodium-channel blocking effects. Propranolol may have contributed to the toxicity seen, but its contribution was likely minor, since propranolol's sodium-channel blocking effects are weak compared to propafenone and the other Ic agents.<sup>50</sup> In addition, our patient's last propranolol dose was 8 hours prior to the onset of severe cardiac toxicity, and she had been observed on an ED monitor for 3 hours after propranolol dosing (i.e., at the time propranolol levels would have peaked). During this time she was stable with a pulse of 90 beats/min and no evident QRS prolongation.

After supportive measures failed,  $\text{HCO}_3^-$  administration led to a dramatic increase in blood pressure, rapid narrowing of her QRS complex, and impressive clinical improvement. These are typical responses for patients with sodium-channel blocker poisoning who receive bicarbonate, but they have not been well documented in the setting of propafenone toxicity.

## Conclusion

We report a case of severe cardiac toxicity with response to bicarbonate following 450 mg of propafenone. Emergency physicians should be familiar with the syndrome of sodium-channel blocker poisoning and recognize the potentially important role of bicarbonate in its treatment.

**Competing interests:** None declared.

## References

- Benjamin EJ, Wolf PA, D'Agostino RB, Silbershatz H, Kannel WB, Levy D. Impact of atrial fibrillation on the risk of death: the framingham heart study. *Circulation* 1998;98(10):946-52.
- Falk R H. Atrial fibrillation. *N Engl J Med* 2001;344(14):1067-78.
- Schreck DM, Rivera AR, Tricarico VJ. Emergency management of atrial fibrillation and flutter: intravenous diltiazem versus intravenous digoxin. *Ann Emerg Med* 1997;29(1):135-40.
- Segal JB, McNamara RL, Miller MR, Kim N, Goodman SN, Powe NR, et al. The evidence regarding the drugs used for ventricular rate control. *J Fam Pract* 2000;49(1):47-59.
- Crozier I, Melton I, Pearson S. Management of atrial fibrillation in the emergency department. *Intern Med J* 2003;33(4):182-5.
- Stoddard MF. Risk of thromboembolism in new onset or transient atrial fibrillation. *Progr Cardiovasc Dis* 1996;39(1):69-80.
- Stoddard MF, Dawkins PR, Prince CR, Ammash NM. Left atrial appendage thrombus is not uncommon in patients with acute atrial fibrillation and a recent embolic event: a transesophageal echocardiographic study. *J Am Coll Cardiol* 1995;25(2):452-9.
- Stoddard MF, Singh P, Dawn B, Longaker RA. Left atrial thrombus predicts transient ischemic attack in patients with atrial fibrillation. *Am Heart J* 2003;145(4):676-82.
- Van Gelder IC, Hagens VE, Bosker HA, Kingma JH, Kamp O, Kingma T, et al. A comparison of rate control and rhythm control in patients with recurrent persistent atrial fibrillation. *N Engl J Med* 2002;347(23):1834-40.
- Wyse DG, Waldo AL, DiMarco JP, Domanski MJ, Rosenberg Y, Schron EB, et al. A comparison of rate control and rhythm control in patients with atrial fibrillation. *N Engl J Med* 2002;347(23):1825-33.
- Falk RH. Management of atrial fibrillation — radical reform or modest modification? *N Engl J Med* 2002;347(23):1883-4.
- Hughes C, Sunderji R, Gin K. Oral propafenone for rapid conversion of recent onset atrial fibrillation — A review. *Can J Cardiol* 1997;13(9):839-42.
- Khan IA. Single oral loading dose of propafenone for pharmacological cardioversion of recent-onset atrial fibrillation. *J Am Coll Cardiol* 2001;37(2):542-7.
- Kowey PR, Marinchak RA, Rials SJ, Bharucha DB. Classification and pharmacology of antiarrhythmic drugs. *Am Heart J* 2000;140(1):12-20.
- Kolecki PF, Curry SC. Poisoning by sodium channel blocking agents. *Crit Care Clin* 1997;13(4):829-48.
- Koppel C, Oberdisse U, Heinemeyer G. Clinical course and outcome in class IC antiarrhythmic overdose. *J Toxicol Clin Toxicol* 1990;28(4):433-44.
- Henry JA, Cassidy SL. Membrane stabilising activity: a major cause of fatal poisoning. *Lancet* 1986;1:1414-7.
- McHugh TP, Perina DG. Propafenone ingestion. *Ann Emerg Med* 1987;16(4):437-40.
- Molia AC, Tholon JP, Lamiabile DL, Trenque TC. Unintentional pediatric overdose of propafenone. *Ann Pharmacotherapy* 2003;37(7-8):1147-8.
- Sadeg N, Richecoeur J, Dumontet M. [Propafenone poisoning]. *Therapie* 2003;58(4):381-3; discussion 387.
- Maxeiner H, Klug E. Lethal suicidal intoxication with propafenone, after a history of self-inflicted injuries. *Forensic Sci Int* 1997;89(1-2):27-32.
- Eray O, Fowler J. Severe propafenone poisoning responded to temporary internal pacemaker. *Vet Hum Toxicol* 2000;42(5):289.
- Fonck K, Haenebalcke C, Hemeryck A, Belpaire F, Jordaens L, Calle P, et al. ECG changes and plasma concentrations of propafenone and its metabolites in a case of severe poisoning. *J Toxicol Clin Toxicol* 1998;36(3):247-51.
- Kerns W 2nd, English B, Ford M. Propafenone overdose. *Ann Emerg Med* 1994;24(1):98-103.
- Rambourg-Schepens MO, Grossenbacher F, Buffet M, Lamiabile D. Recurrent convulsions and cardiac conduction disturbances after propafenone overdose. *Vet Hum Toxicol* 1999;41(3):153-4.
- Friocourt P, Martin C, Lozac'h L. [Self-poisoning with propafenone. Apropos of a case]. [French]. *Annales de Cardiologie et d'Angeiologie* 1988;37(3):133-6.
- Olm M, Jimenez MJ, Munne P. [Efficacy of intravenous methoxamine in propafenone poisoning]. *Presse Med* 1989;18(22):1124.
- Palette C, Maroun N, Gaulier JM, Priolet B, Lachatre G, Bedos JP, et al. [Fatal poisoning with propafenone: a case report documented with blood concentration levels]. *Therapie* 2003;58(4):384-6; discussion 387.
- Cocozzella D, Curciarello J, Corallini O, Olivera A, Alburquerque MM, Fraquelli E, et al. Propafenone hepatotoxicity: report of two new cases. *Dig Dis Sci* 2003;48(2):354-7.
- Gandolfi A, Rota E, Zanghieri G, Tolomelli S, Bagnulo A, Mengoli M. [Acute cholestatic hepatitis caused by propafenone. Report of a case and review of the literature]. *Recenti Prog Med* 2001;92(3):197-9.

31. Grieco A, Forgione A, Giorgi A, Miele L, Gasbarrini G. Propafenone-related cholestatic hepatitis in an elderly patient. *Ital Heart J* 2002;3(7):431-4.
32. Mondardini A, Pasquino P, Bernardi P, Aluffi E, Tartaglino B, Mazzucco G, et al. Propafenone-induced liver injury: report of a case and review of the literature. *Gastroenterology* 1993;104(5):1524-6.
33. Schuppel R, Probst M. Acute cholestatic hepatitis and the sudden rise of the pacing threshold 5 weeks after vvi-pacemaker implantation. *J Intern Med* 1994;236(3):353-6.
34. Spinler SA, Elder CA, Kindwall KE. Propafenone-induced liver injury. *Ann Pharmacotherapy* 1992;26(7-8):926-8.
35. Hill MR, Gotz VP, Harman E, McLeod I, Hendeles L. Evaluation of the asthmogenicity of propafenone, a new antiarrhythmic drug. Comparison of spirometry with methacholine challenge. *Chest* 1986;90(5):698-702.
36. Olm M, Munne P, Jimenez MJ. Severe reactive airways disease induced by propafenone. *Chest* 1989;95(6):1366-7.
37. Miwa LJ, Jolson HM. Propafenone associated agranulocytosis. *Pacing Clin Electrophysiol* 1992;15(4 Pt 1):387-90.
38. Zeng ZQ, Zhu L. [Hemolytic reaction resulting from propafenone administration.] *Zhonghua Nei Ke Za Zhi* 1991;30(4):217-8.
39. O'Rourke DJ, Palac RT, Holzberger PT, Gerling BR, Greenberg ML. Propafenone-induced drug fever in the absence of agranulocytosis. *Clin Cardiol* 1997;20(7):662-4.
40. Odeh M, Seligmann H, Oliven A. Propafenone-induced ataxia: report of three cases. *Am J Med Sci* 2000;320(2):151-3.
41. Nathan AW, Bexton RS, Hellestrand KJ, Camm AJ. Fatal ventricular tachycardia in association with propafenone, a new class IC antiarrhythmic agent. *Postgrad Med J* 1984;60:155-6.
42. Buss J, Neuss H, Bilgin Y, Schlepper M. Malignant ventricular tachyarrhythmias in association with propafenone treatment. *Eur Heart J* 1985;6:424-8.
43. Camous JP, Ichai C, Meyer P, Gibelin P, Baudouy M, Varenne A, et al. [Treatment of poisoning caused by new anti-arrhythmia agents (cibenzoline, flecainide and propafenone)]. *Presse Med* 1987;16(41):2076.
44. De Jaegere P, Huyghens L, Dewilde P. Sustained ventricular tachycardia occurring during propafenone therapy. *Acta Cardiol* 1987;42(3):207-12.
45. Millar RN, Lawrenson JB, Milne DA. Normal left ventricular function does not protect against propafenone-induced incessant ventricular tachycardia. *S Afr Med J* 1993;83(4):256-9.
46. Moroe K, Annoura M, Matsuo K, Yamanouchi Y, Kumagai K, Arakawa K. Proarrhythmic effects of classic drugs. *Clin Ther* 1993;15(3):559-66.
47. Rosengarten M, Brooks R. Torsade de pointes ventricular tachycardia in a hypothyroid patient treated with propafenone. *Ca J Cardiol* 1987;3(5):234-9.
48. Scanu P, Grollier G, Guilleman D, Iselin M, Bustany P, Hurpe JM, et al. Malignant ventricular tachycardia during propafenone treatment in a child with junctional automatic tachycardia: effectiveness of intravenous molar sodium lactate. *Pacing Clin Electrophysiol* 1991;14(5 Pt 1):783-6.
49. Bauman JL, Gallastegui J, Tanenbaum SR, Hariman RJ. Flecainide-induced sustained ventricular tachycardia successfully treated with lidocaine. *Chest* 1987;92(3):573-5.
50. Lau W, Newman D, Dorian P. Can antiarrhythmic agents be selected based on mechanism of action? *Drugs* 2000;60(6):1315-28.
51. Siegers A, Board PN. Amiodarone used in successful resuscitation after near-fatal flecainide overdose. *Resuscitation* 2002;53(1):105-8.
52. Winecoff AP, Hariman RJ, Grawe JJ, Wang Y, Bauman JL. Reversal of the electrocardiographic effects of cocaine by lidocaine. Part 1. Comparison with sodium bicarbonate and quinidine. *Pharmacotherapy* 1994;14(6):698-703.
53. Bou-Abboud E, Nattel S. Relative role of alkalosis and sodium ions in reversal of class I antiarrhythmic drug-induced sodium channel blockade by sodium bicarbonate. *Circulation* 1996;94(8):1954-61.
54. Goldman MJ, Mowry JB, Kirk MA. Sodium bicarbonate to correct widened QRS in a case of flecainide overdose. *J Emerg Med* 1997;15(2):183-6.
55. Kerns W 2nd, Garvey L, Owens J. Cocaine-induced wide complex dysrhythmia. *J Emerg Med* 1997;15(3):321-9.
56. Keyler DE, Pentel PR. Hypertonic sodium bicarbonate partially reverses QRS prolongation due to flecainide in rats. *Life Sci* 1989;45(17):1575-80.
57. Parker RB, Perry GY, Horan LG, Flowers NC. Comparative effects of sodium bicarbonate and sodium chloride on reversing cocaine-induced changes in the electrocardiogram. *J Cardiovasc Pharmacol* 1999;34(6):864-9.
58. Salerno DM, Murakami MM, Johnston RB, Keyler DE, Pentel PR. Reversal of flecainide-induced ventricular arrhythmia by hypertonic sodium bicarbonate in dogs. *Am J Emerg Med* 1995;13(3):285-93.
59. Lovecchio F, Berlin R, Brubacher JR, Sholar JB. Hypertonic sodium bicarbonate in an acute flecainide overdose. *Am J Emerg Med* 1998;16(5):534-7.
60. Lanquetot H, Furet Y, Kerouredan V, Poitrineau O, Hubiche M, Autret E. [Fatal poisoning caused by the combination propafenone-amitriptyline; apropos of a case.] *Agressologie* 1988;29(1):39-42.
61. Roden DM. Antiarrhythmic drugs. In: Goodman and Gilman's *The pharmacologic basis of therapeutics*. 9th ed. New York: McGraw-Hill; 1996. 839-74.

Correspondence to: Jbrubacher@shaw.ca