

Autistic continuum of disorders: Is the term justifiable?

Sir - In recent years the term *autistic continuum* of disorders has become popular when discussing that group of disorders which include autism and certain autistic-like conditions. Whilst individual symptoms of autism may have been shown to exist upon continua, it does not follow that the autistic group of developmental disorders (as distinct from the symptoms) fall upon a continuum of disorders, and indeed there is little evidence for such nomenclature.

There has been much discussion about the suitability of nomenclature for those disorders currently termed '*Pervasive Developmental Disorders*'.^{1,3} At a recent international conference on Autism in Leeds, many of the speakers and delegates used the term 'autistic continuum of disorders'. It is a term readily found in the psychiatric literature,^{4,8} and the National Autistic Society literature.⁹ Training programmes in the field of child mental health have reflected this trend. Is it a justifiable or useful term?

A continuum refers to a continuous structure where any point holds information which has meaning with respect to what is above and below it on the continuum. For autistic-like developmental disorders the term 'a continuum of disorders' has been justified by reason of a continuum of autistic symptomatology.

Many researchers have grouped autistic symptomatology into broad areas. For example, Wing¹⁰ refers to a triad of difficulties. She indicates that any child may exist at any point on a continuum for each of these three areas. A continuum for communication begins with no communication at one end, traverses communication of ones own needs and repetitive one sided communication and reaches literal formal long-winded communication. Similar continua exist for social impairment and imagination. These continua are unidimensional, have good face validity and sit comfortably with our understanding of the term continuum. However, a major problem arises when we look at the whole picture by adding dimensions. In a paper exploring the boundaries of autistic-like diagnoses Bishop¹¹ adds the social interaction dimension to the communication dimension (See Figure 1). This picture can not be called a continuum, and with the addition of further dimensions any semblance of a continuum disappears.

At the level of an individual, it may be helpful to plot a child's place on a symptom dimension but that place may not necessarily parallel his or her place on any other dimension.¹² For example, abnormal early language development may not correlate with autistic social development.¹¹ This lack of correlation in individuals is borne out of the well known fact that there is considerable individual variation in different impairments.⁶ The notion of an autistic continuum of disorders appears to disregard this and may encourage some to make assumptions about a child's capacities in one area based on another area.

A study which factor analysed the 57 items of the Autism Behaviour Checklist found no evidence for the existence of a single common autism factor in a group of autistic children.¹³ Some genetic studies have suggested that a range of related abnormalities exist in the first degree relatives of autistic individuals.¹⁴ However, this should be interpreted with caution. It is not proof of a single aetiology. Significant subgroups of individuals within the study cohorts may be contributing strongly to results. There may be multifactorial causality. Furthermore, as Szatmari⁷ points out, medical conditions may have similar genetic aetiologies but this does not necessarily mean that they have the same presentation, clinical course or response to treatment.

It is always tempting in clinical practice to seek unifying causality or aetiology for diverse presentations of certain disorders. For example, mucopolysaccharide storage disorders (where children's dysmorphism and clinical pictures are very similar) might appear to be on a continuum of severity, but in fact Hurler's syndrome is

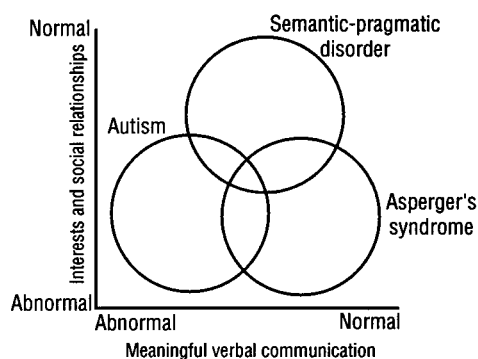


Figure 1: A two-dimensional model of autistic disorders (Bishop 1989). Reproduced by permission of College of Speech and Language Therapists

discrete from the milder Hunter's syndrome, has a different genetic transmission, has less corneal involvement and is caused by a different enzyme abnormality. Just as diagnoses such as Rett's Syndrome have now separated out from the body of autism related disorders, further diagnoses with clear aetiology, course and prognosis may do so in the future.

Any particular term set for a group of disorders should have specified criteria which can be demonstrated and which can be verified by empirical data. Whilst there may be evidence to suggest that symptoms may be on continua, there is no empirical evidence to support a continuum of disorders. Indeed, in Wing's Camberwell epidemiological study the supposed autistic continuum of disorders had identifiable subgroups along its extent. Similarly, other workers appear to be able to pick out easily identifiable subgroups.⁷

The term continuum may be helpful for a symptom of autism, but it is not justifiable, and is confusing, to use it for the disorder of autism itself. A simple alternative would be to change the term *pervasive developmental disorders* to the more straightforward *autism related developmental disorders*. This would reflect the relationship between autism and the other developmental disorders whilst leaving room for further developments in the field.

J Barry D Wright, MBBS, MRCPG, MRCPsych, DCH, MMedSci,
Senior Registrar,
Addenbrookes Hospital,
Hills Road,
Cambridge CB2,
England.

References

1. Volkmar FR, Cohen DJ. Is autism a pervasive developmental disorder? Debate and argument: how useful is the "PDD" label? *J Child Psychol Psychiat* 1991, 32(7): 1167-1168.
2. Happe F, Frith U. Debate and argument: is autism a pervasive developmental disorder? *J Child Psychol Psychiat* 1991; 32(7): 1169-1170.
3. Gillberg C. Debate and argument: the utility of the term pervasive developmental disorder. *J Child Psychol Psychiat* 1991, 32(7): 1171-1172.
4. Wing L The continuum of autistic characteristics. In E. Schopler & G. B. Mesibov (Eds.) *Diagnosis and Assessment in Autism*. New York; Plenum, 1988a.
5. Wing L. The diagnosis of autism. In C. Gillberg (Ed.) *Diagnosis and Treatment of Autism*. New York, Plenum Press, 1989.
6. Frith U. A new look at language and communication in autism. *Br J Dis Comm* 1989, 24: 123 - 150.
7. Szatmari P, Bartolucci G, Bremner R. Asperger's syndrome and autism: comparison of early history and outcome. *Dev Med Child Neurol* 1989;31:709-20.
8. Aarons M, Gittens T. *The Autistic Continuum. An Assessment and Intervention*. Windsor; Nfer-Nelson, 1992.
9. Wing L. The autistic continuum. *Proceedings of Aspects of Autism: Biological Research*. Gaskell, 1988b.
10. Wing L. *Autistic Continuum Disorders: An Aid to Diagnosis*. Norwich; Crowes, 1993.
11. Bishop DVM. Autism, Asperger's syndrome and semantic-pragmatic disorder: Where are the boundaries? *Br J Dis Comm* 1989, 24: 107-121.
12. Cox AD. Is Asperger's syndrome a useful diagnosis? *Arch Dis Childhood* 1991, 66: 259-262.
13. Wadden NPK, Bryson SE, Rodger RS. A closer look at the Autism Behaviour Checklist: discriminant validity and factor structure *J Autism Develop Dis* 1991,

Mania and mobile phones

Sir - The modes of presentation of mental illness are clearly influenced by contemporary social circumstances; best illustrated by the decline in prevalence of religious delusions over the last century.¹ New technologies have been reported to alter phenomenological content,² and this current report shows an area of behaviour increasingly problematic in hypomania due to technological change. Admission to hospital for the mentally ill is seen in large part as protective for the sufferer against their actions. The following cases illustrate a behaviour pattern occurring in hypomania, where admission to hospital is not necessarily protective.

A 48 year old, separated photographer, with a past history of manic depressive psychosis, was admitted compulsorily following concern expressed by his friends since he had hired a helicopter to take his daughter to Euro Disney. He had spent over £16,000 in the two days prior to his admission. His mental state revealed a gentleman with flamboyant dress, over familiarity, pressure of speech and numerous grandiose and expansive delusions. During his stay on the ward he persisted with ideas of being a major international businessman, and to this end insisted on using a mobile phone whilst detained. He was able to communicate with various financial offices during his stay, much to the annoyance of those receiving the calls, and made various contractual arrangements. He absconded from the ward 24 days after his admission. His mental state was largely unchanged.

A 34 year old with a past history of manic depressive psychosis was admitted voluntarily following increasing agitation, insomnia, and the expression of bizarre paranoid ideas. His girlfriend reported him using his mobile phone with increasing regularity.

Mental state on admission was consistent with hypomania. During his stay on the ward he continued to use his mobile phone until the battery expired. At the suggestion of ward staff his girlfriend did not bring in the recharger. He made an uneventful recovery and has returned to work taking lithium prophylaxis.

A 30 year old, single, computer operator was admitted compulsorily in an agitated, grandiose state having recently been treated for a depressive episode with fluoxetine 20mgs a day. He believed himself to be of immense importance and to be essential for the safe running of a major bank's computer system who would lose £182,000 a second during his admission. He was concerned that the bank would not be able to contact him and so had purchased mobile phones and radio-pagers to ensure contact could be made. He insisted on using such devices during his stay making repeated calls to his family in New Zealand. He refused to allow staff to care for the equipment who therefore allowed the batteries to run down to prevent further use. He made an uneventful recovery. Afterwards he was faced with bills for £4,500 for the equipment and calls.

The ill-judged behaviour of hypomanic patients with regard to financial arrangements is well known. Admission to hospital normally prevents further ill-conceived arrangements being made. The widespread use of mobile phones is a relatively new phenomenon and is becoming increasingly common in London. In all three cases they had clearly been a problem preceding the admissions and in cases A and C remained problematic during the patient's stay. Neither patient was prepared to voluntarily hand over their devices and the least confrontational method of reducing their use, and the consequences thereof, was to allow the batteries to expire. Restricting patients freedom is never undertaken likely; a detained patient may be allowed their keys providing the unit is secure, but it is impossible to make a unit 'secure' with respect to mobile phone usage. Considerable thought was given before limiting access to communication, but the teams eventually considered it

necessary to limit use. Whilst the Code Of Practice³ states that patients should not be deprived of "aids necessary for their daily living", limitation of the irresponsible use of mobile phones appeared to be the only sensible way to prevent serious consequences for these patients from their mental illness.

Andrew Smith, MBBS, DCH, MRCPsych
Registrar in Psychiatry,

*South Kensington & Chelsea Mental Health Centre,
1 Nightingale Place,
London, SW10 9NG,
England.*

References

1. Klaf & Hamilton. Schizophrenia: a hundred years ago and today. *J Ment Sci* 1961; 107: 819-27.
2. Spence SA: Nintendo hallucinations: a new phenomenological entity. *Ir J Psych Med* 1993; 10(2): 98-9.
3. Code Of Practice: Mental Health Act 1983. HMSO.

Bilateral foot-drop and electroconvulsive therapy

Sir - We report a case of bilateral foot-drop due to common peroneal nerve palsies which became obvious immediately at the end of a course of electroconvulsive therapy and discuss the possible aetiologies. To our knowledge this is the first such report.

Z, a 67 year old male was admitted to hospital with psychotic depression following a failed trial of lofepramine. He believed that he had blocked, odoriferous bowels and bladder, and was worried lest he might have cancer and AIDs which people could catch from a toilet seat he had used. He gave up food and drink in an attempt to relieve the blockage and spent days digging for a 'broken pipe' in a rain-flooded field despite assurance that one did not exist. The illness appears to have started a few months before admission. Z had received uneventful ECT for psychotic depression when he was aged 29 years and remained well until the index episode. When well, he was of a quiet, anxious disposition. He retired from his warehouse job nine years previously. He never drank alcohol and had not smoked in years.

On admission, Z was agitated, mumbling, pessimistic, depressed, wringing his hands and afraid lest the examiner would catch his disease. He was "finished" and believed we would "put him down". He was fully orientated, had no suicidal thoughts, and denied auditory hallucinations. He was treated with thioridazine 100mgs QID and trazodone 50mgs BID and 100 mgs nocte (later 150 mgs nocte). Physical examination revealed widespread expiratory rhonchi, an intact nervous system, and a normal prostate and ECG. He consented to ECT but was not hopeful about the outcome.

He received seven uneventful bilateral treatments (3/ week; average clinical fit duration = 11.8 secs, range 10-15 secs; average stimulus = 282mC, range =250-325mC) leading to restoration of a completely normal mental state. He remained fully orientated throughout. Thioridazine had been reduced to 25mgs nocte by the time of the seventh treatment.

At the end of the course of ECT, Z was noted to be walking by raising both heels off the ground. All of his reflexes were brisk and equal on both sides. His plantars were down-going, but he had weakness of dorsiflexion of both feet, this being more marked on the left side. B12, folate, FBC, TPHA, VDRL, SMAC, acid phosphatase, chest-Xray, blood glucose and EEG were normal. He had mild degenerative changes in his lumbar spine. Physiotherapy and walking were prescribed and he was discharged on trazodone only.

One week later he was readmitted with a return of his original psychotic symptoms, together with the delusional belief that his penis was diseased. His gait was unchanged. There was no priapism. Trazodone was stopped, although no report of foot-drop could be found to incriminate it. This time he was treated with thioridazine 50mgs QID and trifluoperazine 5mgs QID. Because of