

Complications during shechita and halal slaughter without stunning in cattle

NG Gregory^{*†}, M von Wenzlawowicz[‡], K von Holleben[‡], HR Fielding[†], TJ Gibson[†],
L Mirabito[§] and R Kolesar[#]

[†] Royal Veterinary College, Hawkshead Lane, Hatfield AL9 7TA, UK

[‡] BSI, Postbox 1469, 21487 Schwarzenbek, Germany

[§] Institut de l'Elevage, 149 rue de Bercy, 74595, France

[#] WSPA, 222-236 Gray's Inn Road, London WCI 8HB, UK

* Contact for correspondence and requests for reprints: ngregory@rvc.ac.uk

Abstract

This paper summarises the findings from five studies in eight countries on over 1,500 cattle slaughtered commercially by the halal or shechita methods without stunning. It reports the number of cuts applied to the neck, the cutting methods and the frequency of complications during the bleeding period. Complications during the bleeding period that occurred in some cattle included: (i) delay in the time to collapse, which was interpreted as late loss of consciousness; (ii) premature arrest of bleeding from the carotid arteries due to false aneurysm formation; and (iii) blood entering the respiratory tract during bleeding. These features are important as they determine or reflect the duration of consciousness following the cut and the potential for protracted suffering from wound nociception or blood irritating the respiratory tract. When cattle were not restrained following the halal cut, they took on average 20 s to collapse. Fourteen percent stood up again after an initial collapse, and 1.5% took more than 4 min before their final collapse. Eight percent took 60 s or longer to collapse, and those animals were more likely to have false aneurysms in the severed ends of the carotid arteries. False aneurysms, which were at least 3 cm in diameter, formed in the severed cardiac ends of the carotid arteries in 10% of cattle slaughtered by halal or shechita. Some false aneurysms formed in the severed ends of the carotid arteries within 7 s of the halal cut, and in 10% of the cattle bloodflow came to a halt in one of the arteries within 10 s. On average, the false aneurysms developed within 21 s. Nineteen percent of cattle slaughtered by shechita and 58% of cattle slaughtered by halal had blood lining the mucosa of the trachea. All animals had blood lining the glottis. In both situations there could be a sense of respiratory tract irritation from the blood. It is proposed that severing the carotids at the position in the neck which corresponds to C1 will reduce the frequency of false aneurysm formation and subsequent arrested bloodflow from the severed arteries, and it will deafferent the respiratory tract reducing the transmission of potentially unpleasant sensory signals associated with blood contaminating the upper and lower parts of the tract. Most cattle subjected to halal and shechita have the neck cut at a position which corresponds to C2 to C4, and changing to a cut at C1 could partly reduce the potential for suffering during slaughter without stunning.

Keywords: animal welfare, bleeding, cattle, halal, shechita, slaughter

Introduction

The potential forms of suffering during slaughter without stunning are:

- pain and/or distress caused by the restraining method;
- pain caused by the cutting method; and
- pain and/or distress following the cut.

There is disagreement about whether these forms of suffering occur in every animal, and this may depend on how the slaughtering is performed. This paper is principally concerned with improving the ways in which the cut is performed in cattle, with a view to reducing the frequency

of suffering before unconsciousness sets in. It is an overview based on previously published and unpublished information gathered by the authors.

Cutting method

The level of pain when cuts are applied to the neck is likely to be influenced by:

- the sharpness of the knife;
- the way the opening cut is made in the skin; and
- the number of cuts made in the neck.

Knife length and sharpness vary in halal. Usually the knife is sharp but on one notable occasion in Bangladesh

observed by one of the authors it was found that the knife was very blunt. When blunt knives are used, more pressure has to be applied and there can be more cuts to the neck. Applying a larger number of cuts to the neck increases the risk of stimulating free nerve endings in the skin and at the cut edge of the skin, and this can provoke pain. Another feature which can influence the number of cuts that are used is the dimensions of the neck. This is a particular problem in halal-slaughtered water buffalo that have a short neck and wide horns. In poor areas, where purpose-built restraining systems are not used, cattle and water buffalo are cast using ropes attached to the feet. The animals are secured on their sides, the neck is twisted to present the ventral aspect uppermost and then the cut is made. In some water buffalo it is impossible to twist the neck such that the ventral aspect is uppermost, and so they are cut through the side of the neck whilst in lateral recumbency. The tip of a blade is inserted into the skin and then, after the animal settles, the blade is repositioned in the wound and ventrally directed cuts are made through the neck. Up to 19 cuts have been used to sever the soft tissues in the neck when using this method (Gregory *et al* 2008).

In Indonesia, three methods are used when making the opening halal cuts in the skin. In both Java and Sumatra, one of the more common methods is to use reciprocating cuts across the neck and extending to the underlying soft tissues including the carotid arteries. In Java, an alternative method is to use the tip of the knife to pierce the skin in the side of the neck and then draw the blade as a single sweep through the skin and soft tissues which include the carotid arteries. The third method, which was only seen in Sumatra, uses the knife as a cleaver to make an opening cut in the skin with a single chopping action (Gregory *et al* 2012). This was followed by reciprocating lateral cuts to sever the soft tissues including the carotid arteries. A fourth halal method was seen in France. It involved a very short forward movement of a blade to open the skin, followed by a longer reverse stroke through the soft tissues including the skin. This required a very sharp long knife to complete the cut in a single reverse stroke. It also needed a good understanding on the part of the slaughterman as to whether or not an additional (third) forward movement of the blade was required because insufficient depth was achieved by the main reverse stroke. The likelihood of pain may vary according to which of these four methods is used and according to the way in which they are performed.

The number of cuts recorded during one study of shechita and halal were 3.2 (\pm 0.1) and 5.2 (\pm 0.2), respectively, where one cut represents a movement in one direction before a change in direction or withdrawal of the knife (Gregory *et al* 2008). The legal interpretation of a single cut can be different from this. For example, one legal requirement is that slaughter without stunning has to be “by severance, by rapid, uninterrupted movements of a knife” (WASK 1995). One interpretation of this requirement is that a series of cuts involving many changes in direction of the blade could be a single cut if the changes in direction were

uninterrupted. However, the primary aim should be to minimise stimulation of free nerve endings in the cut edges of the skin, and repeated rubbing of the blade against the cut edges of the skin would be inappropriate from the physiological perspective.

Pain and distress following the cuts

The potential duration of suffering during slaughter without stunning depends on the time it takes for the animal to irreversibly lose consciousness following the cut. There have been many scientific papers which have examined the electroencephalogram (EEG) during this interval, and there has been controversy about the length of this interval (Bager *et al* 1988). Some authorities have found that the EEG shows sufficient changes within 10 s of the cut to conclude that the animals lose consciousness within this period, whereas other reports suggest that a proportion of animals take much longer (Blackmore *et al* 1983; Gregory & Wotton 1984; Daly *et al* 1988). One of the likely reasons for this discrepancy is that insufficient numbers of animals have been used in EEG studies to pick up the relatively low but important percentage that experience sustained consciousness during the bleeding period.

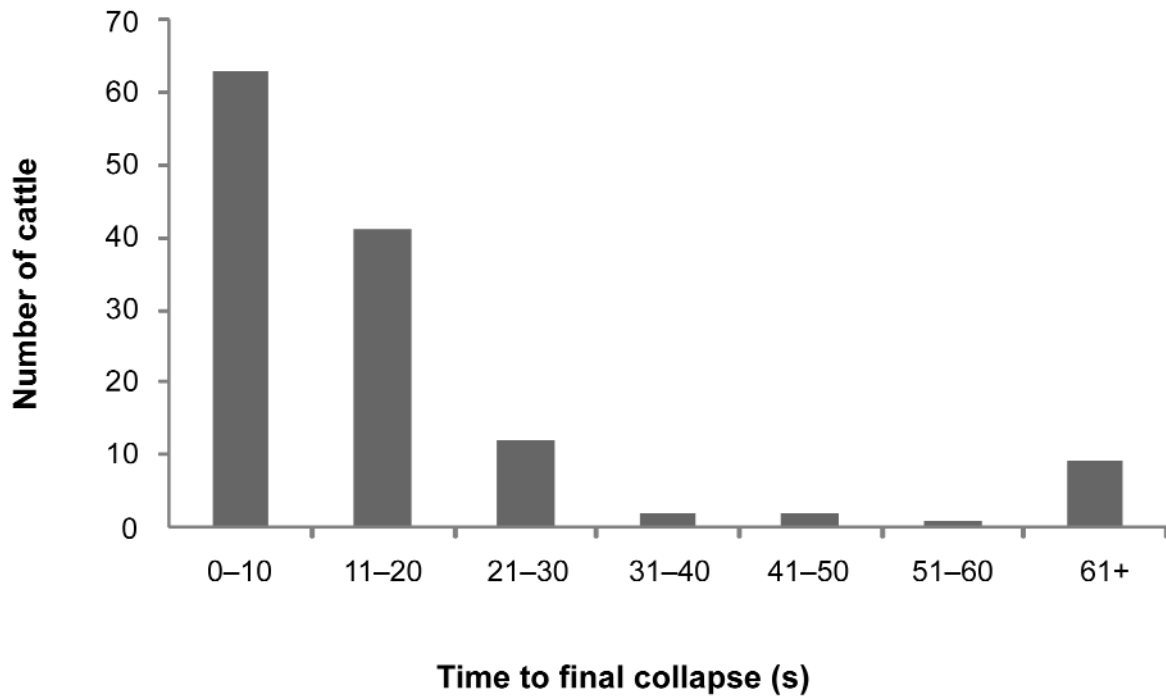
Proportion of cattle which develop a problem

More recently, in a study involving 174 cattle, slaughtered in the upright position by a skilled halal slaughterman, it was found that 8% took longer than 60 s to physically collapse from the standing position following the cuts to the neck (Figure 1; Gregory *et al* 2010). Physical collapse was taken as a sign of the beginning of the loss of consciousness, and this interpretation is sometimes used for the induction of anaesthesia and for the induction of stunning with gases.

The most likely reason why some animals took a long time to lose consciousness is as follows. When the carotid arteries are cut in cattle, some arteries develop false aneurysms at the cardiac severed ends (Gregory *et al* 2008). The aneurysms can arrest blood loss from the arteries and this can lead to delayed loss of consciousness (Gregory *et al* 2010). During the intervening period, nociceptive neuronal signals are relayed to the brain where they are likely to be experienced as pain (Gibson *et al* 2009). When bleeding is arrested by a false aneurysm, blood can continue to flow to the brain via the vertebro-basilar plexus which is particularly well developed in cattle and this could contribute to extending the duration of consciousness (Baldwin 1960; Anil *et al* 1995). However, the likelihood of this combination of events happening will depend on how soon after the cut the severed ends of the arteries become occluded by the false aneurysm, and in what proportion of the animals.

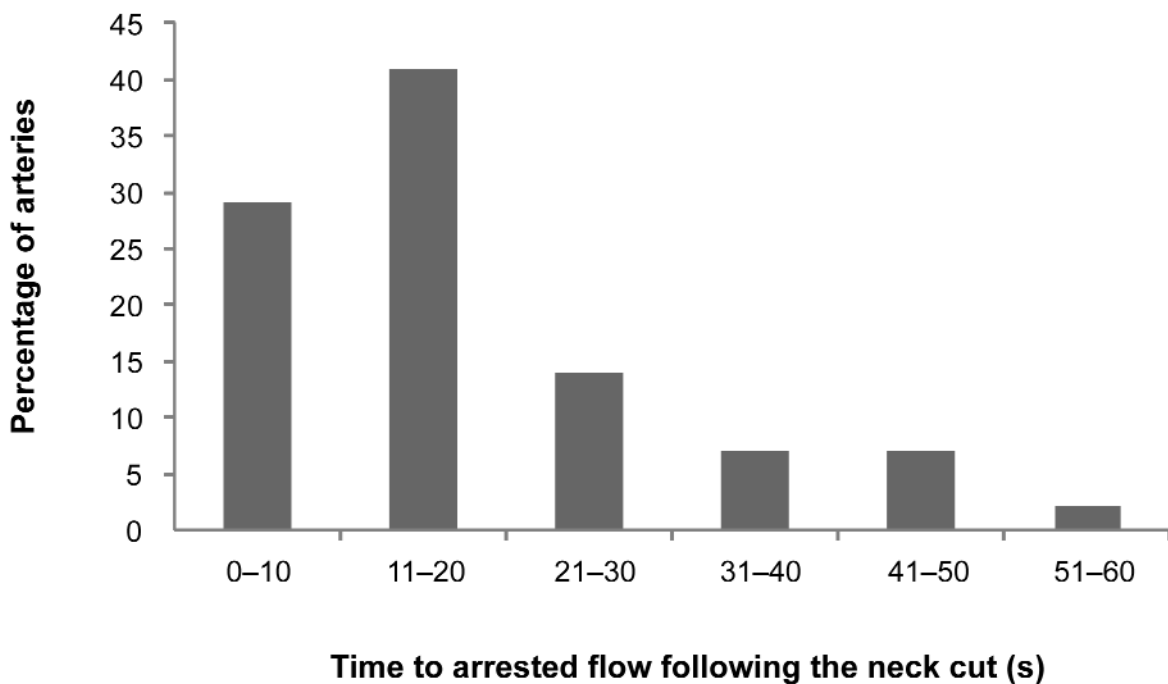
The link between false aneurysm formation and early arrest of bloodflow from the severed carotid arteries was examined in 126 cattle at 12 halal slaughter premises in East Asia plus one halal abattoir in France. It was found that 44 arteries showed early arrest of bloodflow (within 60 s of the halal cut) and that 95% of those arteries had an artery-plus-aneurysm size score of at least 2 (corresponding to an outer diameter of at least 2 cm). Of the 208 arteries with no

Figure 1



Frequency distribution of 174 cattle according to time to collapse following halal slaughter without stunning (after Gregory *et al* 2010).

Figure 2



Time to arrested bloodflow in 44 arteries which experienced early arrested flow (within 60 s) in 36 cattle (after Gregory *et al* 2012).

early arrest of blood flow, 90% had an artery score size of < 2 which is the size for normal arteries with no false aneurysms ($P < 0.0001$). In most arteries, when early arrested bloodflow occurred it developed shortly after the cut was made (Figure 2). For example, in 10% of the animals there was arrested flow from a carotid artery at or within 10 s of making the cut. Over half the animals that developed early arrest of bloodflow showed this effect within 12 s of the cut, and 72% of the cattle showed this effect within 20 s.

Taking these results together, it appears that 10% or more cattle developed a false aneurysm at the severed end of a carotid artery causing arrested bloodflow from that artery. In addition, about 10% of cattle showed a 60 s delay in loss of consciousness after the cut (Gregory *et al* 2010). The following sections consider how bloodflow is arrested, whether we should be concerned about this, and if so, how it can be managed.

Causes of arrested bloodflow

Current thinking is that false aneurysms are the main cause of arrested bloodflow and that they form as a result of retraction of the arteries when they are severed. The arteries are stretched when the chin is extended to achieve tight neck skin which enables effective cutting of the skin. When the arteries are cut, they retract within the surrounding connective tissue sheath which is less elastic than the arteries. This can lead to engorgement of the connective tissue sheath which swells with blood, and in some cases the swelling occludes the severed ends (Gregory *et al* 2006). Typically, the swelling extends for about 1 cm beyond the severed end of the artery, sealing its orifice. This effect has been reproduced in carotid arteries which had their ends partially clamped, and the implication is that either raised pressure from a narrow jet, or directing the flow of blood into the sheath wall increases the risk of false aneurysm formation. These effects, and those that might be produced by other mechanisms, were discussed by Gregory (2009).

Most of the attention so far has been on the behaviour of the cardiac severed ends of the carotid arteries. During bleeding, there can be a small retrograde stream of blood from the cephalic severed ends of the carotids in some animals. If these ends become swollen and occluded, the time to physical collapse can also be increased. For example, cattle which took longer than 60 s to collapse had a higher proportion of cephalic end swelling than those that collapsed more promptly after the halal cut (Gregory *et al* 2010). When the cephalic severed ends are occluded, this could add to the diversion of blood to the vertebro-basilar plexus, especially if a cardiac severed end is also occluded.

Reasons for concern

The reasons for being concerned about arrested bloodflow and a delay in the time to loss of consciousness in some animals are as follows. Firstly, there would be a greater risk of distress following the cut, because of the longer period to loss of consciousness. In one study it was found that 14% of cattle had episodes of collapse followed by standing, and an

impression was that there was distress in some cases (Gregory *et al* 2010). An alternative suggestion has been that cattle might experience euphoria whilst bleeding out (Regenstein, personal communication 2010), but the reasoning supporting this suggestion seems less plausible in view of the struggling that occurred in some animals. Secondly is the greater risk of pain. During slaughter without stunning, pain could arise in one of two ways. (i) whilst making the cut in the neck and especially the skin. It is recognised that repetitive cutting actions are more likely to provoke pain, and in the UK repetitive cutting has been an important feature in legal evidence on inappropriate slaughter practice. Performing the cut as a single sweep in one direction is not common, and where it is performed it sometimes involves piercing the skin with the tip of the blade and drawing the knife across the neck whilst held in an under-hand grasp. (ii) Subsequent exposure of the cut surfaces to mechanical stimuli. Theoretically, free nerve endings exposed at the wound would be susceptible to allodynia from contact with the restraining pen structures supporting the head and neck, impacts from blood, and the cut surfaces rubbing together if the head is released from its restraint too early. Gibson *et al* (2009) showed that nociceptive signals can reach the cerebral cortex of the brain just after the cut and during the bleeding procedure, but the origin of the stimuli that gave rise to those signals was not identified. And, finally, through irritation of the respiratory tract during bleeding. If blood impacts the glottis it could give rise to upper respiratory tract irritation. Normally, this type of stimulus causes abrupt coughing, but when the vagus nerves are severed coughing does not occur. It has been observed that blood usually impacts with the glottis during bleeding in cattle held in both the upright and inverted positions. During both shechita and halal slaughter, blood commonly enters the trachea, and this could cause irritation of the lower respiratory tract if it reaches the carina at the bifurcation of the trachea (Gregory *et al* 2009).

Potential solution to the problem

A number of measures have been proposed for managing the problems created by early arrested flow from the arteries. They include pre-cut stunning, post-cut stunning in all animals, post-cut stunning in those animals that show arrested flow from at least one artery, and cutting any aneurysms that develop during bleeding. There is one other alternative. It has been found at three halal slaughter premises, where the cattle were either cast and cut or inverted in a rotating pen and cut, that the position of the cut across the length of the neck can have a substantial influence on the likelihood of early arrest of bloodflow through false aneurysm formation (Gregory *et al* 2012). Normally, the carotid arteries in the neck are severed at the position of C2 to C4. When carotid arteries were severed at C1 there was a low risk (0.01) of false aneurysm formation and premature arrested bloodflow. Whereas, when cut at the C2 to C4 position, the frequency of false aneurysm formation and arrested bloodflow was higher (0.35; Table 1; $P < 0.001$). Although this finding was not based on a

Table 1 Effect of cutting position in the neck on arrested bloodflow in halal slaughtered cattle (after Gregory *et al* 2012).

	Position of the cut in the neck		
	C1	Caudal to C1	P-value
All cattle	66	60	
Number of cuts to the neck (\pm SEM) (range)	3.4 (\pm 0.2) (1 to 10)	3.8 (\pm 0.4) (1 to 18)	
% carotid arteries in which bloodflow stopped before 60 s	1	35	$P < 0.001$
% cattle in which bloodflow stopped in one or more arteries before 60 s	3	60	$P < 0.001$
% cattle in which bloodflow stopped from both carotid arteries before 60 s	0	13	$P < 0.01$
<i>Arteries which were completely cut and developed arrested flow within 60 s</i>			
Number of arteries	2	42	
Time to arrested bloodflow (s) (\pm SEM)	19	20.8 (\pm 2.2)	
Mean aneurysm score at arrested flow (\pm SEM)	2.0	2.7 (\pm 0.1)	

controlled trial where cattle were slaughtered at the same abattoir by the same slaughterman, the clarity of the difference between the two neck positions introduces an important opportunity for avoiding false aneurysms in future.

Performing the cut at the section of the neck that corresponds to C1 also reduces the likelihood of irritation associated with blood contaminating the respiratory tract. This is because it is likely that both the laryngeal nerves which convey sensory signals from the upper respiratory tract and the vagus nerves which convey some of the signals from the lungs and lower trachea will be severed when the neck is cut in this position (Gregory *et al* 2009). An additional feature that is worth noting is that some cattle emit an entirely different noise whilst breathing when the cut is made at C1 in comparison with C2 to C4. This can be disturbing for some onlookers and it applies to animals in which the cut is made rostral to the glottis.

Conclusion

It is estimated that 10% or more cattle develop complications during the bleeding period during normal halal and shechita slaughter. They take longer to lose consciousness and die because false aneurysms develop in the arteries and the flow of blood from the severed ends stops. Blood continues to flow to the brain through a collateral route. Preliminary findings indicate that the risk of false aneurysms is reduced by cutting near to the angle of the jaw. Present evidence suggests that this also reduces the risk of early arrest of bloodflow. It should be noted that, while the method of cutting outlined here (severing the arteries at C1) reduced the frequency of arrested bloodflow from the arteries and so it should reduce the period of consciousness following the cut, it is argued by many authorities that animals cut without prior effective stunning could experience pain and distress during any conscious period and in this respect a cut at the C1 position should not be viewed as resolving all potential pain and distress.

References

- Anil MH, McKinstry JL, Gregory NG, Wotton SB and Symonds H** 1995 Welfare of calves – 2. Increase in vertebral artery flow following exsanguination by neck sticking and evaluation of chest sticking as an alternative slaughter method. *Meat Science* 41: 113-123. [http://dx.doi.org/10.1016/0309-1740\(94\)00076-J](http://dx.doi.org/10.1016/0309-1740(94)00076-J)
- Bager F, Devine CE and Gilbert KV** 1988 Jugular blood flow in calves after head-only electrical stunning and throat-cutting. *Meat Science* 22: 237-243. [http://dx.doi.org/10.1016/0309-1740\(88\)90051-4](http://dx.doi.org/10.1016/0309-1740(88)90051-4)
- Baldwin BA** 1960 *The correlation between the vascular supply of the brain and cerebral function in ruminants*. PhD Thesis, Royal Veterinary College, University of London, UK
- Blackmore DK, Newhook JC and Grandin T** 1983 Time to onset of insensibility in four to six-week old calves during slaughter. *Meat Science* 9: 145-149. [http://dx.doi.org/10.1016/0309-1740\(83\)90024-4](http://dx.doi.org/10.1016/0309-1740(83)90024-4)
- Daly CC, Kallweit E and Ellendorf F** 1988 Cortical function in cattle during slaughter: conventional captive bolt stunning followed by exsanguination compared with shechita slaughter. *Veterinary Record* 122: 325-329. <http://dx.doi.org/10.1136/vr.122.14.325>
- Gibson TJ, Johnson CB, Murrell JC, Hulls CM, Mitchinson SL, Stafford KJ, Johnstone AC and Mellor DJ** 2009 Electroencephalographic responses of halothane-anaesthetised calves to slaughter by ventral-neck incision without prior stunning. *New Zealand Veterinary Journal* 57: 77-83. <http://dx.doi.org/10.1080/00480169.2009.36882>
- Gregory NG** 2009 Pseudoaneurysm formation in severed arteries. In: Laurent A and Morel E (eds) *Aneurysms: Types, Risks, Formation and Treatment* pp 233-241. Nova Biomedical Books: New York, USA
- Gregory NG and Wotton SB** 1984 Time to loss of brain responsiveness following exsanguination in calves. *Research in Veterinary Science* 37: 141-143

Gregory NG, Shaw FD, Whitford JC and Patterson-Kane JC 2006 Prevalence of ballooning of the severed carotid arteries at slaughter in cattle, calves and sheep. *Meat Science* 74: 655-657. <http://dx.doi.org/10.1016/j.meatsci.2006.05.021>

Gregory NG, von Wenzlawowicz M, Alam RM, Anil HM, Yeşildere T and Silva-Fletcher A 2008 False aneurysms in carotid arteries of cattle and water buffalo during shechita and halal slaughter. *Meat Science* 79: 285-288

Gregory NG, von Wenzlawowicz M and von Holleben K 2009 Blood in the respiratory tract during slaughter without stunning in cattle. *Meat Science* 82: 13-16. <http://dx.doi.org/10.1016/j.meatsci.2008.11.021>

Gregory NG, Fielding HR, von Wenzlawowicz M and von Holleben K 2010 Time to collapse following slaughter without stunning in cattle. *Meat Science* 85: 66-69. <http://dx.doi.org/10.1016/j.meatsci.2009.12.005>

Gregory NG, Schuster P, Mirabito L, Kolesar R and McManus T 2012 Arrested blood flow during false aneurysm formation in the carotid arteries of cattle slaughtered with and without stunning. *Meat Science* 90: 368-372

WASK 1995 *The Welfare of Animals (Slaughter or Killing) Regulations. Statutory Instrument 1995 No. 731 Schedule 12.* <http://www.legislation.gov.uk/uksi/1995/731/contents/made>