

Meconium Peritonitis in Both Fetuses With Early Twin-to-Twin Transfusion Syndrome

Louis Marcellin,¹ Andrea Quintana,² Mohamed Essaoui,³ Olivia Anselem,¹ Sylvie Beaudoin,⁴ Mayas El Ayoubi,¹ Laurence Boujenah,¹ Houria Salhi,⁵ and Vassili Tsatsaris^{1,6}

¹Department of Obstetrics and Gynecology, Cochin Hospital, Paris Descartes University, Paris, France

²University of Texas Southwestern Medical School, Dallas, TX, USA

³Department of Obstetrics and Gynecology, Necker Hospital, Paris Descartes University, Paris, France

⁴Department of Pediatric Surgery, Necker Hospital, Paris Descartes University, Paris, France

⁵Department of Pathology, Cochin Hospital, Paris Descartes University, Paris, France

⁶PremUP Foundation, Paris, France

Twin-to-twin transfusion syndrome (TTTS) is due to unbalanced inter-twin bloodflow through placental vascular anastomoses. We present a TTTS case treated with fetoscopic laser photocoagulation (FLP) that was complicated by perinatal meconium peritonitis in both twins. Ten weeks following laser treatment, the two fetuses showed intra-abdominal hyperechogenicity and ascites. After birth, the two newborns were surgically managed for peritonitis. We discuss the pathogenesis of this double insult. The present case highlights the role of end-circulation bowel thrombi as the potential cause of subsequent intestinal perforation.

■ **Keywords:** Twin-to-Twin Transfusion Syndrome, Meconium Peritonitis, fetoscopic laser photocoagulation

Twin-to-twin transfusion syndrome (TTTS) may be responsible for complications in fetal organs such as the brain, liver, limbs, and intestinal tract, irrespective of the treatment employed (Morikawa et al., 2008). They have been traditionally attributed to thrombosis secondary to hyperviscosity, and virtually always in the recipient. The best described vascular accidents involve limb defects and limb necrosis (Lopriore et al., 2008). To date, the pathophysiology of these complications is still unclear but may be related to severe hemodynamic alterations that can occur spontaneously or secondary to interventions such as amniodrainage or laser therapy. We report a case of neonatal meconium peritonitis in both donor and recipient newborns who had undergone antenatal laser surgery for TTTS, diagnosed during the second trimester of gestation. Cases of TTTS treated by selective fetoscopic laser photocoagulation (FLP) in which only the recipient twin was affected with intestinal complications are described in literature. The originality of this case stems from the fact that both twins, not merely the recipient twin, had congenital bowel perforations.

Case

A 41-year-old Caucasian woman was referred to our center for an early TTTS. Her past medical history was re-

markable for Rendu–Osler–Weber syndrome and a prior pregnancy that ended in preterm labor at 28 weeks gestation.

Early ultrasound of the current pregnancy revealed a monochorionic diamniotic twin pregnancy. An ultrasound examination at 17 weeks gestation showed signs of early stage 2 TTTS by Quintero staging (Quintero, 2003): oligohydramnios without a detectable bladder in the donor twin and polyhydramnios in the recipient twin. Endoscopic laser surgery with selective FLP was performed at 18 weeks gestation. Karyotyping was normal (46 XY). Ultrasound examinations between 20 and 23 weeks gestation showed no further signs of TTTS. Ultrasound examinations at 25, 26, and 27 weeks gestation showed bowel hyperechogenicity and abdominal ascites in both twins that appeared in the latter two examinations (Figure 1). Fetal growth, amniotic fluid indices, and fetal Doppler examinations were within the normal ranges. Workups for maternal infections and

RECEIVED 3 June 2011; ACCEPTED 7 October 2011.

ADDRESS FOR CORRESPONDENCE: Dr L. Marcellin, Department of Obstetrics and Gynecology, Cochin Hospital, Paris Descartes University, Maternité Port Royal, 123, Bd de Port Royal, 75014 Paris, France. E-mail: louismarcellin@hotmail.com

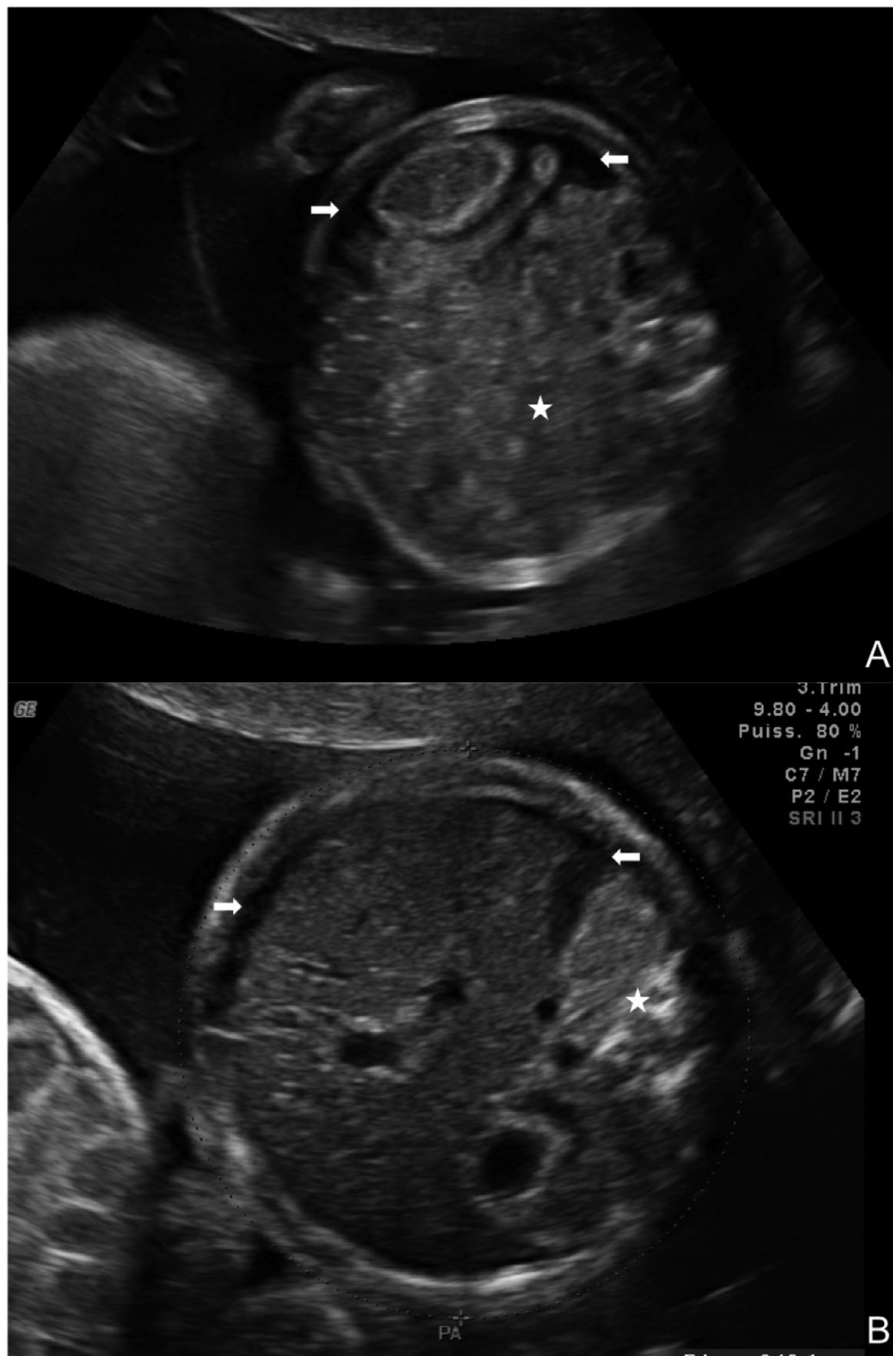
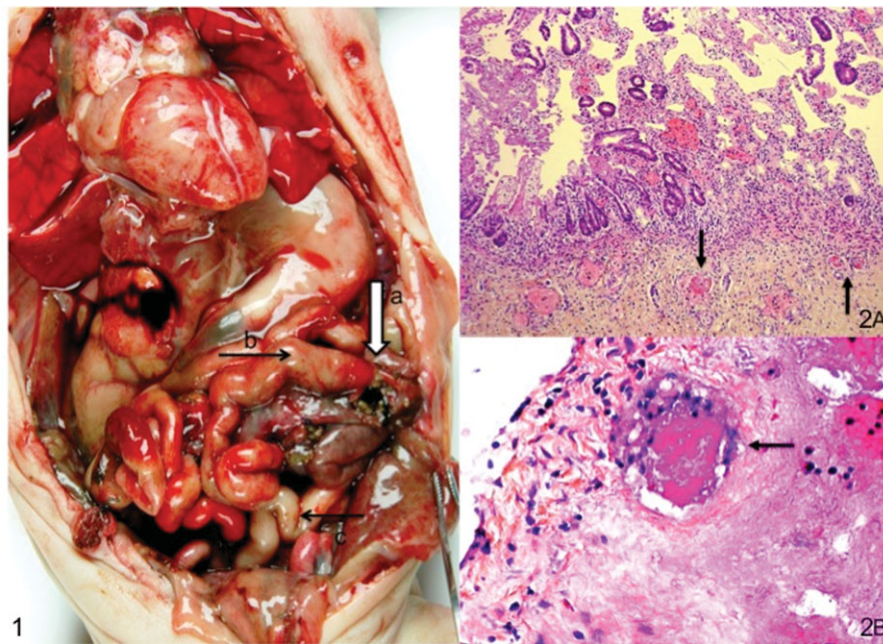


FIGURE 1
Sonographic ascites (arrows) and digestive hyperechogenicity (stars) of donor twin (A) and recipient twin (B).

cystic fibrosis were negative. At 25 weeks gestation, the patient was hospitalized for spontaneous preterm labor and corticosteroids therapy for fetal lung maturation was administered. A cesarean section was performed at 27^{6/7} weeks gestation for heart rate decelerations in the donor twin.

The donor's weight was 1,025 grams, and the recipient's weight was 925 grams. The infants, both male, received ap-

propriate resuscitative care. At birth, the hemoglobin levels of the donor and the recipient twin were 11.1 g/dL and 13.1 g/dL, respectively. Ascites was diagnosed clinically in both newborns. Peritoneal puncture of the donor, 15 minutes after delivery, yielded 55 mL of a green, meconium-like fluid. Meconium peritonitis secondary to a perforation of the transverse colon was surgically managed with stoma

**FIGURE 2**

(Colour online) (2-1) Macroscopic view of digestive tract of recipient twin: necrotic patches throughout the jejunum (a), dilated ileum (b), and small caliber colon (c); (2-2A and 2-2B) histological examination of jejunum of recipient twin: microemboli or microthrombi in the submucosal capillaries (arrows).

without bowel resection. He left neonatal intensive care at 70 days of life weighing 2,650 grams; neonatal evolution was, in the end, favorable.

The recipient twin had less significant ascites. Surgical management, delayed until 24 hours of life, revealed copious meconial fluid and a distended jejunum upstream of a jejunal perforation, with adhesions severe enough to form a large right lower quadrant conglomeration with necrotic zones. Management consisted of a 29-cm bowel resection and double stoma. Perioperative histologic examination of the resected segment revealed fibrosis of the wall with edematous vessels, amassed pigmented macrophages, and several sub-mucosal capillaries with microthrombi and microemboli. He died of multi-organ failure 24 hours after surgery. On post-mortem examination, there was no bowel atresia. Microscopic examination showed necrotic patches scattered throughout the jejunum, with microemboli or microthrombi in the submucosal capillaries (Figure 2-1). Histological examination of the non-resected jejunum revealed old microthrombi (Figures 2-2A and 2-2B) not found in other organs.

Discussion

This report is the first example of neonatal meconium peritonitis in both monozygotic twins who had undergone antenatal laser surgery for TTTS. TTTS disrupts fetal peripheral perfusion, leading to organ lesions. These severe hemodynamic alterations can occur spontaneously or sec-

ondary to interventions irrespective of the treatment employed such as amniocentesis or laser therapy (Morikawa et al., 2008).

Meconium peritonitis is caused by an in utero fetal bowel perforation and leads to the extrusion of meconium into the peritoneal cavity. Necrosis of the digestive tract could be due to a mechanical accident (Terzibachian et al., 1995) or to a vascular embolus lodging in the intestinal vasculature. In utero exposure to infectious diseases such as parvovirus B19, measles, VZV, or CMV can result in meconium peritonitis; the pathophysiology seems to involve various forms of vasculitis (Staud & Corman, 1996; Zerbini et al., 1998). In some cases, no etiology for necrosis of the digestive tract can be found.

Ultrasonographic diagnosis of antenatal meconium peritonitis is possible at 20 weeks gestation when fetal intestinal peristalsis is established. Ascites and abdominal calcifications are the main signs (Chan et al., 2005) and are found, respectively, in 100% and 92.9–94% of cases (Shyu et al., 2003). Other reported signs are polyhydramnios, pseudocysts, dilated bowel, or fetal anasarca (Shyu et al., 2003; Wang et al., 2008).

TTTS complicates 10–15% of monozygotic multiple gestations (Duncan et al., 1997). Inter-twin transfusion is a quasi-constant event due to a balanced flow through permanent vascular placental connections between the twins that exist even in non-pathologic twin pregnancies (Denbow et al., 2000). TTTS is caused by an imbalance in these connections, creating an excessive unidirectional flow

between the twins (El Kateb & Ville, 2008). Endoscopic laser surgery with FLP is becoming the first-line treatment for the management of TTTS (Senat et al., 2004).

In the presented case, the donor twin survived even though the recipient twin died in multiple-organ failure, despite surgical management. The literature describes five cases of TTTS treated by selective FLP in which the recipient twin suffered intestinal complications. The first case presented ileal atresia with perforation and surgical management was unsuccessful (Morikawa et al., 2008). In the second (Schnater et al., 2005), third (Arul et al., 2001), and fourth cases (Saura et al., 2010), resection and anastomosis for ileal atresia were curative. In the final case (Arul et al., 2001), resection of a necrotic ileal mass was also curative. In the latter four cases, the donor twin died in utero after treatment by selective FLP. Two cases of donor twins affected by jejunal atresia and ileocecal ischemia have also been reported, with both recipient survival. They had postnatal surgical treatment and both made an uncomplicated recovery (Saura et al., 2010). In TTTS with survival of both fetuses, bowel complications can be caused by different etiologies in the donor and recipient. On one hand, there is polycythemia and hyperviscosity in the recipient. On the other hand, there is low flow and a sort of 'diving reflex' in the donor, who exhibits increased systemic vascular resistance secondary to chronic anemia.

Some authors suggest an embolic mechanism for organ damage: a placental vessel coagulated by laser surgical management would be the source of the embolus. Schnater et al. described a case in which intrahepatic thromboembolic calcifications were found upon autopsy of the donor twin, who had undergone antenatal selective FLP. This case strengthens the argument for a thromboembolic mechanism for organ lesions. On the contrary, Morikawa et al. consider that previous intervention is not a prerequisite for ischemic injury in twins suffering from TTTS (Morikawa et al., 2008). Similarly, Philip et al. reported two cases of congenital bowel perforation in non-FLP-treated TTTS: one had undergone amnioreduction and one received no antenatal TTTS treatment (Philip et al., 2002).

The uniqueness of our case stems from the fact that both twins had congenital bowel perforations secondary to a defective early vascularization of the mesenteric arterial system. Histologic analysis of the recipient twin's jejunum showed ischemic necrosis with inflammatory granulomatous lesions that support the idea of a defect in vascularization. No other organs showed similar damage, ruling out disseminated intravascular coagulation (DIC) or a coagulopathy. It is impossible to determine if the intestinal lesions were caused by a local thrombotic event or a by placental microemboli. However, as previously argued by Morikawa et al., microemboli from placental veins are unlikely to lodge preferentially in the fetal mesenteric system after having traversed the fetal cardiac circulation.

In conclusion, acute hemodynamic disorders as well as anemia or hyperviscosity can compromise the terminal mesenteric circulation and lead to ischemic and necrotic lesions in both monochorionic twins. Furthermore, the present case highlights the role of end-circulation bowel thrombi as the potential cause of subsequent intestinal perforation.

References

- Arul, G. S., Carroll, S., Kyle, P. M., Soothill, P. W., & Spicer, R. D. (2001). Intestinal complications associated with twin-twin transfusion syndrome after antenatal laser treatment: Report of two cases. *Journal of Pediatric Surgery*, *36*, 301–302.
- Chan, K. L., Tang, M. H., Tse, H. Y., Tang, R. Y., & Tam, P. K. (2005). Meconium peritonitis: Prenatal diagnosis, postnatal management and outcome. *Prenatal Diagnosis*, *25*, 676–682.
- Denbow, M. L., Cox, P., Taylor, M., Hammal, D. M., & Fisk, N. M. (2000). Placental angioarchitecture in monochorionic twin pregnancies: Relationship to fetal growth, fetofetal transfusion syndrome, and pregnancy outcome. *American Journal of Obstetrics and Gynecology*, *182*, 417–426.
- Duncan, K. R., Denbow, M. L., & Fisk, N. M. (1997). The aetiology and management of twin-twin transfusion syndrome. *Prenatal Diagnosis*, *17*, 1227–1236.
- El Kateb, A., & Ville, Y. (2008). Update on twin-to-twin transfusion syndrome. *Best Practice & Research Clinical Obstetrics and Gynaecology*, *22*, 63–75.
- Lopriore, E., Lewi, L., Oepkes, D., Debeer, A., Vandenbussche, F. P., Deprest, J., & Walther, F. J. (2008). In utero acquired limb ischemia in monochorionic twins with and without twin-to-twin transfusion syndrome. *Prenatal Diagnosis*, *28*, 800–804.
- Morikawa, M., Sago, H., Yamada, T., Hayashi, S., Yamada, T., Cho, K., Yamada, H., Kitagawa, M., & Minakami, H. (2008). Ileal atresia after fetoscopic laser photocoagulation for twin-to-twin transfusion syndrome – a case report. *Prenatal Diagnosis*, *28*, 1072–1074.
- Philip, I., Ford, A., & Haslam, R. (2002). Congenital bowel perforation in twin-to-twin transfusion syndrome. *Pediatric Surgery International*, *18*, 733–734.
- Quintero, R. A. (2003). Twin-twin transfusion syndrome. *Clinical Perinatology*, *30*, 591–600.
- Saura, L., Muñoz, M. E., Castañón, M., Eixarch, E., Corradini, M., Aguilar, C., & Ma Ribó J. (2010). Intestinal complications after antenatal fetoscopic laser ablation in twin-to-twin transfusion syndrome. *Journal of Pediatric Surgery*, *45*, E5–E8.
- Schnater, J. M., van Zalen-Sprock, R. M., Schaap, A. H., Festen, S., & Aronson, D. C. (2005). Ileal atresia and thromboembolic liver calcifications diagnosed after treatment with intrauterine laser coagulation therapy for twin-to-twin transfusion syndrome: Report of 2 cases. *Journal of Pediatric Surgery*, *40*, 875–876.
- Senat, M. V., Deprest, J., Boulvain, M., Paupe, A., Winer, N., & Ville, Y. (2004). Endoscopic laser surgery versus serial

- amnioreduction for severe twin-to-twin transfusion syndrome. *New England Journal of Medicine*, 351, 136–144.
- Shyu, M. K., Shih, J. C., Lee, C. N., Hwa, H. L., Chow, S. N., & Hsieh, F. J. (2003). Correlation of prenatal ultrasound and postnatal outcome in meconium peritonitis. *Fetal Diagnosis and Therapy*, 18, 255–261.
- Staud, R., & Corman, L. C. (1996). Association of parvovirus B19 infection with giant cell arteritis. *Clinical Infectious Diseases*, 22, 1123.
- Terzibachian, J. J., Shu, J. D., Levy, G., Destuynder, O., Agnani, G., & Daucourt, J. (1995). Prenatal diagnosis of a small intestinal volvulus. *Journal of Gynecology & Obstetrics and Biological Reproduction*, 24, 839–842.
- Wang, C. N., Chang, S. D., Chao, A. S., Wang, T. H., Tseng, L. H., & Chang, Y. L. (2008). Meconium peritonitis in utero—the value of prenatal diagnosis in determining neonatal outcome. *Taiwan Journal of Obstetrics and Gynecology*, 47, 391–396.
- Zerbini, M., Gentilomi, G. A., Gallinella, G., Morandi, R., Calvi, S., Guerra, B., & Musiani, M. (1998). Intra-uterine parvovirus B19 infection and meconium peritonitis. *Prenatal Diagnosis*, 18, 599–606.
-