

Just the Facts: How to assess a patient with constant significant vertigo and nystagmus in the emergency department

Peter Johns, MD, FRCPC*; Hans Rosenberg, MD, CCFP-EM*

CLINICAL SCENARIO

A 43-year-old female presents to the emergency department (ED) after she woke up with the sensation that the room was spinning and vomited three times at home. She continues to have significant vertigo when she presents to the ED 4 hours later. Her symptoms are worsened by head movement. She has noticed some unsteadiness but is able to walk unaided. When you examine her, she has left-beating horizontal nystagmus with a slight rotatory component to the left.

KEY CLINICAL QUESTIONS

1. What are the most common causes of this presentation?

Vestibular neuritis is the most common cause, whereas a cerebellar stroke presenting with vertigo is a less common but more dangerous cause. Due to the presence of spontaneous nystagmus and her persistent significant vertigo, this is not benign paroxysmal peripheral vertigo (BPPV). Other rare but worrisome causes of vertigo include cerebellar hemorrhage and multiple sclerosis.¹

2. What are the stroke/central symptoms or signs you should screen this patient for?

New significant headache or neck pain would be concerning for cerebellar hemorrhage or vertebral artery dissection, respectively. Physicians should assess for the usual stroke symptoms such as facial/limb weakness or numbness, as well as posterior circulation stroke symptoms, such as dysarthria, diplopia, dysmetria, dysphonia, and dysphagia. Spontaneous vertical nystagmus, if seen, would indicate a central cause. Finally, inability to walk unaided would also be concerning for stroke.² (See [Figure 1](#) – Approach Algorithm.)

3. After she has screened negative for stroke features, how can we be more certain she isn't having a cerebellar stroke that is causing her symptoms?

The HINTS plus exam is 99% sensitive and 97% specific for identifying a central cause of vertigo in patients with constant vertigo and nystagmus. Unlike commonly used stroke screening tools, such as the ABCD2 risk score, the HINTS plus exam maintains a very high sensitivity regardless of application to younger (< 60 years old) or elderly patients (up to 92 years old).³ It should not be applied in patients unless they have both significant constant vertigo and spontaneous nystagmus.

From the *Department of Emergency Medicine, University of Ottawa, Ottawa, ON.

Correspondence to: Dr. Peter Johns, 1053 Carling Ave., Ottawa, ON K1Y 4E9; Email: pjohns@toh.ca

© Canadian Association of Emergency Physicians 2020

CJEM 2020;22(4):463–467

DOI 10.1017/cem.2020.34

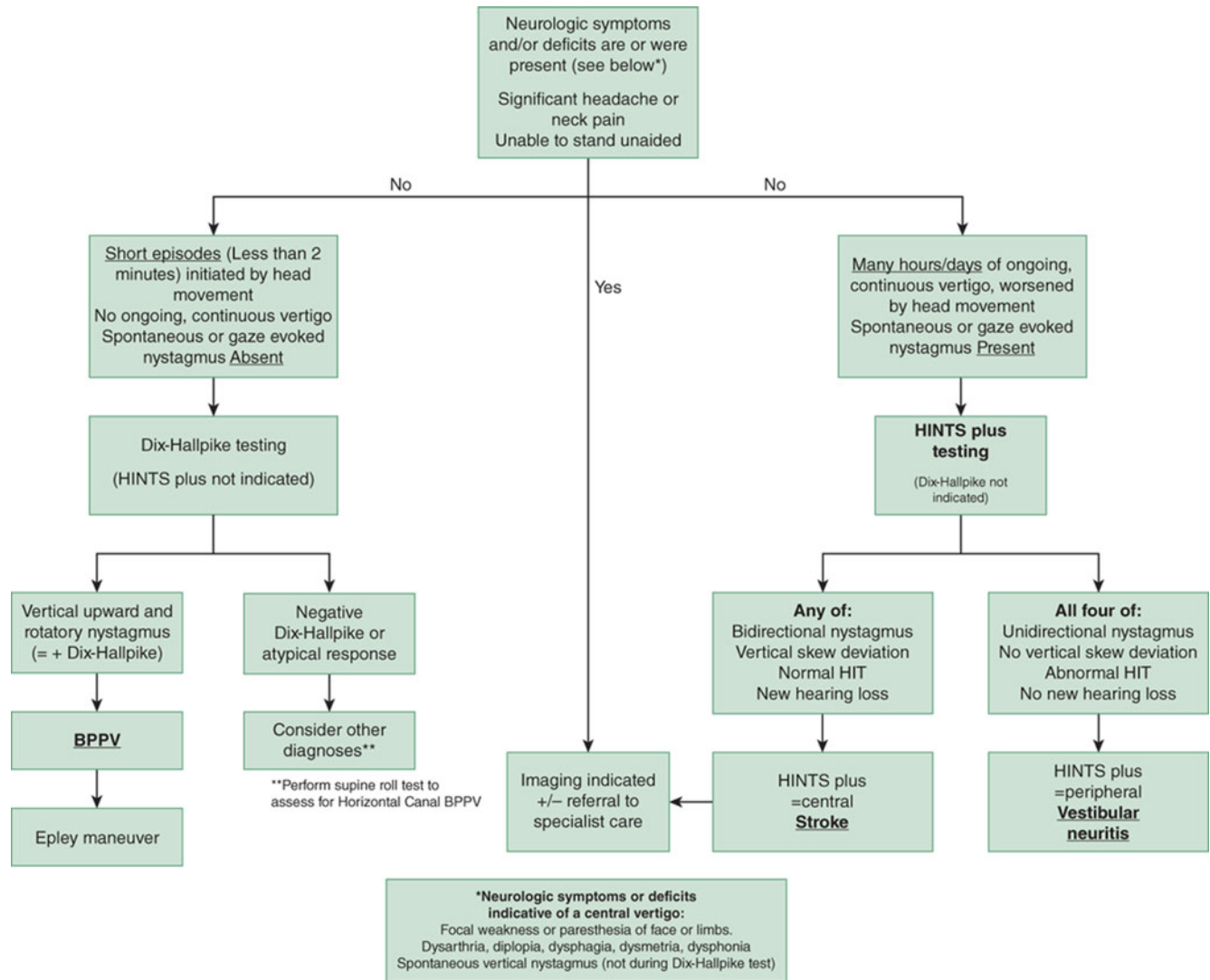


Figure 1. Algorithm approach to patients presenting with vertigo and nystagmus. (Reproduced with permission from Goldman B, Johns P. *Tintinalli emergency medicine*. 9th ed. McGraw-Hill Education, New York; 2019, Chapter 170.)

4. What is the HINTS plus exam?

The HINTS plus exam is a series of four bedside tests: nystagmus, Test of Skew, Head Impulse Test (HIT), and a bedside test of hearing. Unidirectional nystagmus, no vertical skew, an abnormal HIT, and no new hearing loss would be deemed an overall HINTS plus “peripheral” result and confirm the diagnosis of vestibular neuritis.³ The HIT is performed by asking the patient to fixate on your nose and then rapidly moving the patient’s head from 20 degrees off midline back to midline. In vestibular neuritis, one side will demonstrate an abnormal “catch-up saccade,” where the eyes will overshoot your nose and then re-fixate on your nose. This is an abnormal HIT and not seen in cerebellar strokes. Thus, the counter-intuitive finding with a normal HIT is concerning for a stroke in a patient with constant vertigo and nystagmus. (See Figure 2 – HIT Infographic.)

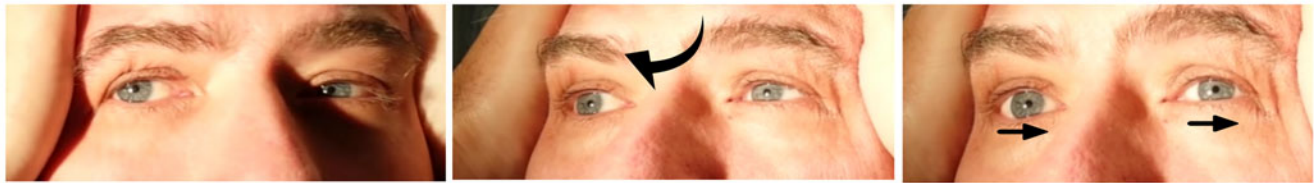(Video of HINTS plus exam being performed <https://youtu.be/84waYROI4U>)

(Video of HIT being performed <https://www.youtube.com/watch?v=XpghlvnrREI&feature=youtu.be&t=666>)

CAEP | ACMU
40
1978-2018

HOW TO PERFORM
HEAD IMPULSE TEST

[HTTPS://WWW.YOUTUBE.COM/WATCH?V=XP6HLVNRREIGT=1239S](https://www.youtube.com/watch?v=XP6HLVNRREIGT=1239S)



Abnormal HIT - Patient's head is turned by the examiner rapidly towards the patient's right. The eyes overshoot and then a catch-up saccade occurs moving the eyes back to the target. This is reassuring for vestibular neuritis.



Normal HIT - The patient's eyes remain fixed on the target when the head is turned rapidly to the left. If both sides are normal, this would be worrisome for a cerebellar stroke.

Infographic Created by Drs. Hans Rosenberg and Peter Johns

Figure 2. How to perform the head impulse test.

5. If vestibular neuritis is confirmed, what then?

No diagnostic imaging is necessary in typical cases of vestibular neuritis with a HINTS plus “peripheral” result. Anti-emetic medications, such as metoclopramide, dimenhydrinate, or meclizine, can be used for 2 or 3 days to control

nausea and vomiting. Referral to vestibular rehabilitation may hasten the recovery from vestibular neuritis. The benefit from corticosteroids in vestibular neuritis is questionable, and shared decision-making with patients regarding their use may be the best approach.⁴

6. If the patient had screened positive for central features or had a HINTS plus “central” result, what would be the workup?

Magnetic resonance imaging (MRI) after 48 hours is the optimal way to rule out a stroke.⁵ However, if cerebellar hemorrhage is a concern due to new sustained significant headache, a plain computed tomography (CT) should be performed. If new sustained neck pain is present, a computed tomography angiogram (CTA) could be performed to rule out vertebral artery dissection. If other neurologic features are present, as outlined in question 2 above, a CTA is also warranted in these circumstances. A specialist consultation with neurology would also be necessary to determine next steps and disposition.

CASE RESOLUTION

You perform the HINTS exam and only unidirectional left-beating nystagmus is seen. The HIT is abnormal, with a prominent “catch-up” saccade when her head is turned rapidly to the right. There is no vertical skew seen. Bedside test of hearing is normal bilaterally. You do not perform a Dix-Hallpike test as the presence of spontaneous nystagmus rules out BPPV. You are confident that this patient does not have a central cause of her vertigo and this is most likely vestibular neuritis. You treat her nausea with intravenous (IV) metoclopramide and afterwards she is feeling significantly better and is discharged with a 3-day supply of metoclopramide and instructions to follow up with a local expert interested in dizzy patients.

KEY POINTS

- In patients with constant significant vertigo with nystagmus, first screen for high-risk stroke/central features that would mandate imaging and referral to specialist care.
- If the patient screens negative for stroke/central features, perform the HINTS plus exam.
- Patients who screen negative for stroke/central features and have an overall HINTS plus exam with a peripheral result can be considered for discharge with appropriate follow-up.
- Patients who screen positive for stroke/central symptoms or have an overall HINTS plus exam with a central result will need diagnostic imaging and referral to specialist care.
- An MRI obtained 48 hours after onset of symptoms is the optimal method of ruling out a suspected posterior circulation stroke. If cerebellar hemorrhage or vertebral artery dissection is a concern due to new significant headache or neck pain, a plain CT or CTA could be performed respectively.

Keywords: Ear nose and throat, neurology, stroke/TIA

Competing interests: None declared.

REFERENCES

1. Tarnutzer AA, Berkowitz AL, Robinson KA, Hsieh YH, Newman-Toker DE. Does my dizzy patient have a stroke? A systematic review of bedside diagnosis in acute vestibular syndrome. *CMAJ* 2011;183(9):E571–92.

2. Goldman B, Johns P. *Tintinalli emergency medicine*. 9th ed. New York: McGraw-Hill Education; 2019.
3. Newman-Toker DE, Kerber KA, Hsieh Y, et al. HINTS outperforms ABCD2 to screen for stroke in acute continuous vertigo and dizziness. *Acad Emerg Med* 2013;20(10):987–96.
4. Fishman JM, Burgess C, Waddell A. Corticosteroids for the treatment of idiopathic acute vestibular dysfunction (vestibular neuritis). *Cochrane Datab Syst Rev* 2011(5):CD008607.
5. Saber-Tehrani AS, Kattah JC, Mantokoudis G, et al. Small strokes causing severe vertigo: frequency of false-negative MRIs and non-lacunar mechanisms. *Neurology* 2014;83:169–73.