

Main Article

Ahmet Taha Karakuzu takes responsibility for the integrity of the content of the paper

Cite this article: Karakuzu AT, Özel HE, Temir H, Özdoğan F, Genç S, Çalışkan S. Effect of drilling on otolithic organ functions in mastoidectomy. *J Laryngol Otol* 2024;1-5. <https://doi.org/10.1017/S0022215124000598>

Received: 20 December 2023

Revised: 4 January 2024

Accepted: 8 January 2024

Keywords:

Otolithic organs; mastoidectomy; benign paroxysmal positional vertigo; bucket test; subjective visual vertical; vestibular function tests

Corresponding author:

Ahmet Taha Karakuzu;

Email: ahmettahakarakuzu@gmail.com

Abstract

Objective. This study aimed to assess the effect of drilling during mastoidectomy on otolithic organ functions and development of benign paroxysmal positional vertigo using objective vestibular tests.

Materials and methods. The study included 45 adult patients diagnosed with chronic otitis media who underwent mastoidectomy with drilling. Pre-operative and post-operative assessments included tests for subjective visual vertical deviation and videonystagmography.

Results. Subjective visual vertical deviation was significantly higher in post-operative periods. On the third day, the subjective visual vertical deviation was at its maximum (1.4 degrees). Post-operatively, benign paroxysmal positional vertigo was detected in 14 patients (31.1 per cent). The most common type was ipsilateral lateral canal benign paroxysmal positional vertigo (57.1 per cent).

Conclusion. The effect of drilling on otolithic organ functions in mastoidectomy seems to be temporary and subclinical; however, it potentially could be a risk factor for the development of benign paroxysmal positional vertigo.

Introduction

The inner ear contains the utricle and saccule, which are otolithic organs housing calcium carbonate particles called otoconia on the macula. The utricle detects horizontal head movements, while the saccule detects vertical head movements. Otoconia in these organs respond to gravity and linear accelerations, stimulating hair cells on the macula and contributing to the perception of gravity and linear movements in the balance system.

Studies on otolithic organ functions are increasing, with a focus not only on their effects on the balance system but also on their broader potential effects.¹⁻⁴ The otoliths, which are the most ancient part of the vestibular sensory organs in evolutionary terms, excel in detecting various types of motion. When considering evolutionary, clinical, and physical aspects, otoliths appear superior to the semicircular canal system.⁵ The bucket test is a simple and effective method for measuring subjective visual vertical, which allows for the assessment of otolithic organ functions.⁶

The widely accepted pathophysiology of benign paroxysmal positional vertigo (BPPV) involves the displacement of otoliths from the utricle into the semicircular canals, sensitising them to gravity. Clinical observations suggest that drilling during mastoidectomy might influence otolithic organs, potentially leading to BPPV development. However, this area of study is relatively limited, primarily relying on indirect evidence. The common association of BPPV with head trauma is a well-recognised phenomenon.⁷ It is plausible that the drilling process during mastoidectomy might have a similar traumatising effect. Vibrations during canalith repositioning manoeuvres facilitate canalith movement and treatment success.⁸ Similarly, the intense vibrations caused by mastoidectomy drilling might displace otoliths from the macula. Studies have indicated that even the contralateral ear may experience hearing loss after mastoidectomy,^{9,10} suggesting that drilling can damage the inner ear, potentially affecting otolithic organs. Although prior research has linked BPPV to various middle ear surgeries,¹¹⁻¹⁴ there is limited investigation into the effects of drilling during mastoidectomy on otolithic organ functions.¹⁵ To the best of the authors' knowledge, no study has investigated the effect of drilling during mastoidectomy on otolithic organ function over time in the post-operative period.

This study aimed to prospectively assess the effect of drilling during mastoidectomy on otolithic organ functions throughout the post-operative period and to examine its potential association with the development of BPPV using objective vestibular function tests.

Materials and methods

This prospective study was conducted between April 2021 and April 2023 within the Otolaryngology Department of a tertiary referral hospital, with the approval of the ethics

committee at the University of Health Sciences, Derince Research and Training Hospital. The ethical approval number is: 2021/79.

Patients

All patients were informed about the study, and their consent was obtained both verbally and in written form. The study included 45 adult patients diagnosed with chronic otitis media based on otoscopic/microscopic examination, audiological assessments, and radiological examinations. All of the patients had undergone mastoidectomy. Only cases with a drilling duration of at least 1 hour during mastoidectomy were included in the study. Patients with limited drilling time, such as those who had undergone atticotomy or atticotomy during the procedure, were excluded from the study. Additionally, patients who had undergone revision surgery were not considered for inclusion. Furthermore, individuals with radiological or intra-operative anatomical structural defects of the inner ear (e.g., semicircular canal dehiscence) also were excluded from the study. Patients with pre-operative vestibular symptoms or a diagnosed peripheral or central vestibular disease were excluded. The vertigo dizziness imbalance symptom scale¹⁶ was administered to all post-operative patients at one month post-surgery.

Videonystagmography

Eye movements were recorded via videonystagmography using the ICS Chartr 200 VNG/ENG (Otometrics, Taastrup, Denmark). On the videonystagmography, eye movements were classified as nystagmus if they displayed the typical biphasic nystagmus pattern, repeated at least three beats consecutively, with a slow phase velocity of at least 3°. The following vestibular function tests were conducted on all patients using videonystagmography both before the surgery and on the seventh day post-operatively.

Gaze test

Patients were positioned 1 meter away from a light bar and instructed to maintain the stillness of their head and eyelids while visually tracking the target. Eye movements were recorded while patients fixated on a stationary target with a visual angle of 30° to the right, left, up and down from the centre.

Skew deviation test

Vertical movements of the eyes were assessed during recordings taken while patients fixed their gaze on a point 1 meter away. The right and left eyes were alternately covered with a plastic occluder.

Dix-Hallpike test

While recording eye movements, the patient's head was rotated 45° to the right, and the patient was swiftly transitioned from a seated to a supine position with the head lowered by 20°. The patient remained in this position for one minute before returning to the seated position. The same test was repeated with a 45° leftward head rotation. Eye movements were recorded while ocular fixation was suppressed for both sides and continued to be recorded for 10 seconds in the seated position.

Supine roll test

Patients were positioned in a supine position with the head flexed at 30°. The head was initially rotated 90° to the right, then brought back to the midline, and finally turned to the left, all while recording eye movements with ocular fixation suppressed.

Torsional, up-beating nystagmus observed during the Dix-Hallpike test and direction-changing horizontal nystagmus detected during the supine roll test were considered typical findings indicative of BPPV in the posterior canal and the lateral canal, respectively.

Bucket test

The subjective visual vertical deviation were assessed both pre-operatively and post-operatively on the 1st day, 3rd day, 5th day, 7th day, and first month using a modified bucket test with the assistance of a smartphone. During the test, patients faced forward, and their heads were placed inside a bucket with a black line at the bottom. Patients were instructed to align the line they saw in front of them perpendicularly to the ground by adjusting the orientation of the bucket. A smartphone, fixed to the outer bottom of the bucket at a 90° angle relative to the black line inside the bucket, was used for the test. Utilising the smartphone's gyroscope feature, the subjective visual vertical deviation was measured through a spirit level application (Figure 1).

Statistical analyses

Vertigo dizziness imbalance scores and subjective visual vertical deviations were compared between patients with and without BPPV using an independent sample *t*-test. Paired *t*-tests were utilised for other assessments. Statistical analyses were



Figure 1. The smartphone-assisted modified bucket test.

Table 1. Comparison of pre-operative and post-operative subjective visual vertical deviations

	Degrees $\bar{X} \pm SD$ (range)	<i>p</i>
Pre-operative	0.8 ± 0.6 (0.1–3)	
Post-operative day 1	1.1 ± 0.9 (0.1–4)	0.005*
Post-operative day 3	1.4 ± 1.4 (0–8.7)	0.013*
Post-operative day 5	1.3 ± 1.2 (0.2–7.2)	0.011*
Post-operative day 7	1.2 ± 0.8 (0.1–3.5)	0.008*
Post-operative 1st month	0.9 ± 0.6 (0.1–3.1)	0.397

*Statistically significant; SD = standard deviation

conducted using the Statistical Package for the Social Sciences (SPSS) version 20.0 (SPSS Inc., Chicago, USA). Significance was considered at $p < 0.005$, and descriptive statistics were applied for other data.

Results

Among the 45 patients enrolled in the study, 26 (57.8 per cent) were male and 19 (42.2 per cent) were female, with a mean age of 46.3 ± 11.9 (range 18–65) years old. Thirty-six patients (80 per cent) underwent canal wall down tympanomastoidectomy, while 9 patients (20 per cent) underwent intact canal wall tympanomastoidectomy.

Subjective visual vertical deviation significantly increased on post-operative day 1, day 3, day 5, and day 7 compared to pre-operative measurements but returned to pre-operative levels at the first post-operative month (Table 1). On day 3, the subjective visual vertical deviation was at its maximum (1.4°) (Figure 2). There was no statistically significant difference in subjective visual vertical deviation between patients with BPPV (1.29 ± 1.16) and patients without BPPV (1.41 ± 1.58) on day 3, when the subjective visual vertical deviation was at its maximum ($p = 0.800$).

No pathological findings were observed in the pre-operative and post-operative results of the gaze and skew deviation tests. While pre-operative diagnostic positional manoeuvres did not

reveal significant findings, 14 patients (31.1 per cent) were diagnosed with BPPV after the surgery. Out of these patients, 9 (64.3 per cent) had involvement in the same ear, 4 (28.6 per cent) in the opposite ear, and 1 (7.1 per cent) in both ears. Among patients who developed BPPV, the most common type was ipsilateral lateral canal BPPV (57.1 per cent). The characteristics of patients with post-operative BPPV are detailed in Table 2.

The Gufoni manoeuvre was conducted for patients with lateral canal BPPV, and the Epley manoeuvre was administered for patients with posterior canal BPPV. In cases with multicanal involvement, appropriate canalith repositioning manoeuvres were individually performed for each affected canal within the same session. No recurrence of BPPV was observed in the control diagnostic positional manoeuvres conducted one week later.

A statistically significant difference was observed when comparing the vertigo dizziness imbalance scores of patients with post-operative BPPV (32 ± 24.4) to scores of patients without BPPV (15.2 ± 18.3) ($p = 0.014$). Among the 14 patients with BPPV, 4 (28.6 per cent) were asymptomatic, as indicated by vertigo dizziness imbalance scores below 7.

Discussion

This study aimed to investigate the effect of drilling during mastoidectomy on otolithic organ functions and its potential association with the development of BPPV. The findings suggest that although there may be measurable changes in otolithic organ function following mastoidectomy involving drilling, these changes do not appear to lead to clinically significant impairments. The absence of a significant association between BPPV and otolithic organ function further reinforces this conclusion.

Comparing our findings with existing research is challenging due to the scarcity of studies. Ogawa *et al.*¹⁵ investigated subjective visual vertical in 71 patients who had undergone different ear surgeries. They considered subjective visual vertical tilts greater than 2.0 as pathological and measured them on post-operative day 1. Their findings indicated that within the

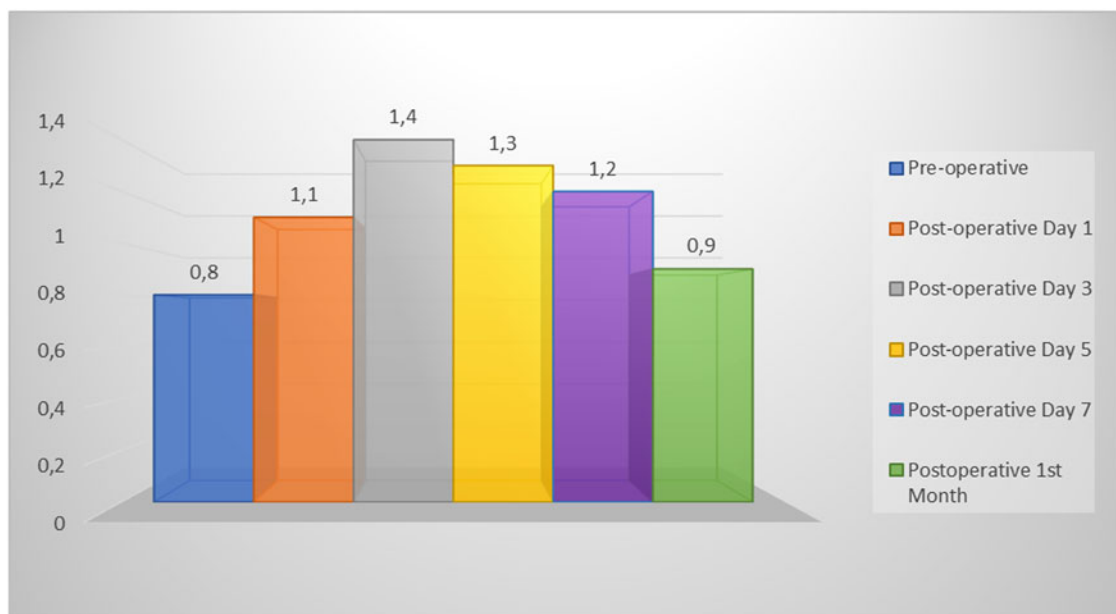


Figure 2. Post-operative subjective visual vertical deviation.

Table 2. Distribution of patients with post-operative benign paroxysmal positional vertigo; CWDTM = canal wall down tympanomastoidectomy; ICWTM = intact canal wall tympanomastoidectomy; VDI = vertigo dizziness imbalance score; CL = contralateral; IL = ipsilateral; LC = lateral canal; PC = posterior canal

	Age, gender	Operation	VDI	Variant	Diagnosis
1	18, male	CWDTM	0	Geotropic	CL LC
2	51, male	CWDTM	16	Geotropic	CL LC
3	45, male	ICWTM	54	Geotropic	CL PC
4	45, female	ICWTM	12	Geotropic	CL PC
5	58, male	CWDTM	54	Geotropic	IL PC
6	44, male	CWDTM	56	Geotropic	IL LC
7	61, female	CWDTM	0	Geotropic	IL LC
8	57, female	CWDTM	56	Ageotropic	IL LC
9	59, male	CWDTM	6	Geotropic	IL LC
10	39, female	CWDTM	56	Geotropic	IL LC
11	49, male	CWDTM	44	Geotropic	IL LC
12	49, female	CWDTM	56	Geotropic	IL LC
13	49, male	CWDTM	36	Geotropic/Ageotropic	IL PC / CL LC
14	41, male	CWDTM	2	Geotropic	IL LC + IL PC

group of 48 patients who underwent tympanoplasty with a surgical drill, 18.8 per cent experienced post-operative positional nystagmus, and 43.7 per cent exhibited subjective visual vertical tilt.¹⁵ In our study, we examined the changes in subjective visual vertical deviation over time in the post-operative period, including day 1, day 3, day 5, day 7, and the first month. We observed a significant increase in subjective visual vertical deviation starting from the first post-operative day compared to pre-operative measurements, and this deviation gradually improved by the first month. The highest recorded average deviation was 1.4° degrees on day 3.

The causal relationship between otolithic organ function, subjective visual vertical, and BPPV remains unclear, which complicates the interpretation of our findings. Some studies suggest that the presence of BPPV can influence subjective visual vertical results, and treatment for BPPV may result in improvements in subjective visual vertical values. Ferreira *et al.* reported a reduction in subjective visual vertical deviations in BPPV patients before and immediately after canalith repositioning manoeuvres.³ It has been noted that subjective visual vertical values are at their highest within the first 72 hours after the onset of BPPV symptoms.⁴ In our study, 14 (31.1 per cent) patients were diagnosed with BPPV after the surgery and received appropriate canalith repositioning manoeuvre treatment. Hence, it's uncertain whether our findings are solely attributed to otolith function or if they are also influenced by the semicircular canals' function.

It is noteworthy that post-operative BPPV was observed in approximately one-third of the patients in our study. The lifetime prevalence of BPPV stood at 2.4 per cent, with a one-year prevalence of 1.6 per cent and a one-year incidence of 0.6 per cent.¹⁷ In cases with a traumatic aetiology, its incidence varies between 10 per cent and 15 per cent.⁷ Studies associating middle-ear surgery with BPPV have reported rates ranging from 1 per cent to 11 per cent.^{11–14} In our study, the number of patients with BPPV was higher than the occurrences of BPPV in the general population, trauma cases, and after surgery, as reported in the literature. However, in clinical practice, BPPV after mastoidectomy does not typically result in this degree of morbidity. Several explanations might account for

this observation. One possible reason is that the application of videonystagmography to all patients in our study, regardless of the presence of symptoms, may have revealed the actual frequency of BPPV. The use of objective vestibular tests that eliminate ocular fixation enhances diagnostic accuracy. It has been demonstrated that ocular fixation suppresses positional nystagmus responses during diagnostic positional manoeuvres at a rate of 66.1 per cent.¹⁸ Detecting BPPV in four patients with a vertigo dizziness imbalance score of 6 or less implies that typical positional nystagmus responses associated with BPPV can be identified in asymptomatic patients when ocular fixation is eliminated with videonystagmography. In this study, the most common type of BPPV was the ipsilateral geotropic variant of lateral canal BPPV. The tendency of these patients to lie on their non-operated intact ears may facilitate utricular movement of the canaliths. This spontaneous healing effect may be a factor reducing the number of symptomatic patients. Indeed, in a retrospective review of patients with post-operative symptomatic BPPV after surgical drilling of the temporal bone, Park *et al.*¹⁴ reported that lateral canal BPPV predominantly occurred in the contralateral ear (80 per cent), with a significantly lower incidence (1 per cent) of BPPV compared to our study.

Benign paroxysmal positional vertigo, resulting from the drilling of the temporal bone, has some similarities with traumatic aetiology. A higher incidence of lateral canal involvement is commonly observed in traumatic BPPV, which typically occurs within the first two weeks and often within the first few days after the trauma.¹⁹ In our study, the videonystagmography test performed in the first week showed that the lateral canal was the most frequently affected, with a rate of 78.6 per cent. This finding aligns with the study by Park *et al.*,¹⁴ which reported that the lateral canal was affected in 90 per cent of cases with BPPV occurring 1–6 days post-operatively.

The higher incidence in the lateral canal may be due to the patient lying on the intact ear during and after the operation and the lateral canal being positioned perpendicular to the ground, which is more exposed to gravity. The risk of multicanal involvement is higher in post-traumatic BPPV.⁷ Indeed, a

high rate of multicanal involvement was detected in our patients (14.3 per cent) compared to the general population. Canal wall down tympanomastoidectomy was performed in 12 (85.7 per cent) of the patients with BPPV. The higher rate of BPPV in these patients may be attributed to the longer duration of drilling compared to intact canal wall tympanomastoidectomy. However, unlike BPPV of traumatic origin, BPPV due to otological surgery responded well to canalith repositioning manoeuvres. Patients with BPPV were subjected to canalith repositioning manoeuvres in the same session and no recurrent BPPV was observed in control diagnostic positional manoeuvres performed one week later. The occurrence of the predominantly geotropic variant due to the vibratory nature of drilling may have lowered the risk of recurrence. Nevertheless, the limited three-month follow-up period in our study might have led to the oversight of patients experiencing long-term recurrences.

- Hearing loss post-mastoidectomy may indicate that drilling could harm the inner ear, potentially affecting otolithic organs
- Benign paroxysmal positional vertigo (BPPV) is frequently associated with head trauma, and drilling in mastoidectomy might have a similarly traumatising effect
- Vibrations during canalith repositioning manoeuvres boost canalith movement and enhance treatment success
- The effect of drilling on otolithic organ functions in mastoidectomy appears to be temporary and subclinical, posing a potential risk factor for BPPV development
- Post-operative BPPV occurred in approximately one-third of patients, predominantly presenting as the ipsilateral geotropic variant of lateral canal BPPV
- Resting on the non-operated ear during the postoperative period may contribute to a reduction in patients' symptoms, which in turn could decrease the number of symptomatic patients.

This study has several limitations. Besides temporal bone drilling, factors such as prolonged positioning, inflammation resulting from chronic otitis media, and interventions on the ossicular chain potentially could have affected the study's outcomes. Conducting research comparing surgeries that share similar patient positioning requirements, including parotid surgery, otological surgeries, and non-otological surgeries completed in equivalent timeframes without the need for specific head positioning, using objective vestibular tests, could provide more conclusive insights into this subject.

Conclusion

This study suggests that measurable changes in otolithic organ function resulting from mastoidectomy with drilling do not lead to significant clinical impairments. Additionally, the lack of an association between BPPV and otolithic organ function further supports this conclusion. Post-operative BPPV was identified in about one-third of the patients, with the ipsilateral geotropic variant of lateral canal BPPV being the most common presentation. The likelihood that patients resting on their unoperated ear might contribute to the spontaneous resolution of symptoms, thereby reducing the number of symptomatic patients. The study also highlights the

importance of utilising objective vestibular tests to detect BPPV. Canalith repositioning manoeuvres proved to be an effective treatment for BPPV in these cases. Additional research is required to ascertain if vestibular changes can be attributed to factors other than drilling, such as surgical procedures and anaesthesia.

References

- 1 Shen J, Ma X, Zhang Q, Chen J, Wang L, Wang W *et al.* The functional status of vestibular otolith and conductive pathway in patients with unilateral idiopathic sudden sensorineural hearing loss. *Front Neurol* 2023;**14**:1237516
- 2 Shigeno K. Subjective visual vertical deviation in patients with early-onset direction-changing horizontal positional nystagmus. *Auris Nasus Larynx* 2023;**50**:48–56
- 3 Ferreira MM, Ganança MM, Caovilla HH. Subjective visual vertical after treatment of benign paroxysmal positional vertigo. *Braz J Otorhinolaryngol* 2017;**83**:659–64
- 4 Sapountzi Z, Vital V, Psillas G. Subjective visual vertical in patients with benign positional paroxysmal vertigo. *Hippokratia* 2017;**21**:159
- 5 Ramos de Miguel A, Zarowski A, Sluydts M, Ramos Macias A, Wuyts FL. The superiority of the otolith system. *Audiol Neurootol* 2020;**25**:35–41
- 6 Chetana N, Jayesh R. Subjective visual vertical in various vestibular disorders by using a simple bucket test. *Indian J Otolaryngol Head Neck Surg* 2015;**67**:180–4
- 7 Di Cesare T, Tricarico L, Passali GC, Sergi B, Paludetti G, Galli J *et al.* Traumatic benign paroxysmal positional vertigo: personal experience and comparison with idiopathic BPPV. *Int J Audiol* 2021;**60**:393–7
- 8 Li JC. Mastoid oscillation: a critical factor for success in canalith repositioning procedure. *Otolaryngol Head Neck Surg* 1995;**112**:670–5
- 9 Doménech J, Carulla M, Traserra J. Sensorineural high-frequency hearing loss after drill-generated acoustic trauma in tympanoplasty. *Arch Otorhinolaryngol* 1989;**246**:280–2
- 10 Lee D, Kim Y, Kim DK. Sensorineural hearing loss after surgery to treat chronic otitis media. *Ear Nose Throat J* 2021;**100**(suppl):220S–4S
- 11 Shu F, Zhang HZ, Cai JQ, Xu MQ, Jiang SS. Clinical characteristics and efficacy analysis of secondary benign paroxysmal positional vertigo after middle ear surgery [in Chinese]. *Lin Chuang Er Bi Yan Hou Tou Jing Wai Ke Za Zhi* 2020;**34**:79–82
- 12 Limb CJ, Francis HF, Lustig LR, Niparko JK, Jammal H. Benign positional vertigo after cochlear implantation. *Otolaryngol Head Neck Surg* 2005;**132**:741–5
- 13 Viccaro M, Mancini P, La Gamma R, De Seta E, Covelli E, Filippo R. Positional vertigo and cochlear implantation. *Otol Neurotol* 2007;**28**:764–7
- 14 Park SK, Kim SY, Han KH, Hong SK, Kim JS, Koo JW. Benign paroxysmal positional vertigo after surgical drilling of the temporal bone. *Otol Neurotol* 2013;**34**:1448–55
- 15 Ogawa Y, Hayashi M, Otsuka K, Shimizu S, Inagaki T, Hagiwara A *et al.* Subjective visual vertical in patients with ear surgery. *Acta Otolaryngol* 2010;**130**:576–82
- 16 Prieto L, Santed R, Cobo E, Alonso J. A new measure for assessing the health-related quality of life of patients with vertigo, dizziness or imbalance: the VDI questionnaire. *Qual Life Res* 1999;**8**:131–9
- 17 von Brevern M, Radtke A, Lezius F, Feldmann M, Ziese T, Lempert T *et al.* Epidemiology of benign paroxysmal positional vertigo: a population based study. *J Neurol Neurosurg Psychiatry* 2007;**78**:710–15
- 18 Özel HE, Karakuzu AT, Temir H, Alpay M, Özdoğan F, Genç S. Effect of ocular fixation on positional nystagmus in BPPV patients. *Int J Audiol* 2023;**62**:644–9
- 19 Balatsouras DG, Koukoutsis G, Aspris A, Fassolis A, Moukos A, Economou NC *et al.* Benign paroxysmal positional vertigo secondary to mild head trauma. *Ann Otol Rhinol Laryngol* 2017;**126**:54–60