

Microsurgical Discectomy: A Prospective Study of 200 Patients

H. Schutz and C.P.N. Watson

ABSTRACT: This report describes the results of microsurgical discectomy in a prospective study of 200 consecutive patients with intractable sciatica, followed independently by a pain clinic. Post operative morbidity was minimal, the complication rate very low, and patients were discharged home early. Leg pain was relieved in almost all patients, but back pain was relieved in only 72% of patients. The rate of return to work at one, three and twelve months post-operatively was 50%, 83% and 95% respectively. Microsurgical discectomy is an effective and safe procedure.

RÉSUMÉ: Discectomie par microchirurgie: une étude prospective de 200 patients Le présent compte-rendu décrit les résultats de la discectomie par microchirurgie dans une étude de 200 patients consécutifs souffrant de sciatique réfractaire, suivi de façon indépendante à une clinique de la douleur. La morbidité post-opératoire a été minime, le taux de complications très bas et les patients ont été renvoyés à domicile tôt après l'intervention. La douleur à la jambe a été soulagée chez presque tous les patients, mais la douleur au dos n'a été soulagée que chez 72 % des patients. Le taux de retour au travail un, trois et douze mois après l'opération était de 50 %, 83 % et 95 % respectivement. La discectomie par microchirurgie est une intervention efficace et sûre.

Can. J. Neurol. Sci. 1987; 14:81-83

The most important factor in determining successful outcome following lumbar disc surgery is the proper selection of patients. Of secondary importance is the technique used to relieve neural compression. Microsurgical discectomy is considered a godsend by some and a gimmick by others. The latter¹ believe that a thorough neural decompression of the nerve root(s) can only be accomplished by an extensive muscular and bony exposure. The former² argue that a thorough discectomy and neural decompression can be done equally well through a limited muscular and bony exposure, facilitated by magnification and illumination of the microscope. The present paper reviews the results and complications of microsurgical discectomy in the management of patients with intractable root tension, and differs from other reports in that it is a prospective study. Careful documentation and follow-up of physical and psychological factors was carried out at the University of Toronto Pain Clinic, independent of the surgeon. For each patient a total of 165 factors were recorded and analyzed, although only those considered to be of high clinical relevance are included in this paper.

METHODS

Microsurgical Discectomy

The technique has been well described by others.^{2,3,4,5} The essential aspects of the technique are listed in Table 1. The patient is placed in the knee-chest position and the level to be exposed is confirmed by x-ray. A 2.5 cm incision is made in the

Table 1: Essential steps in microsurgical discectomy

- | | |
|----|--|
| 1) | Minimal paravertebral muscle retraction |
| 2) | Preservation of all extradural fat |
| 3) | Preservation of facets and laminae |
| 4) | Minimal retraction of nerve roots |
| 5) | Thorough removal of intervertebral disc material |

midline. The dorsolumbar fascia is incised in a semicircular fashion about 2.5 cm away from the midline. The para-spinal muscles are dissected with a scalpel from the spinous process and lamina of the superior vertebra. The appropriate Williams self-retracting retractor is inserted to expose the ligamentum flavum and lamina. The operating microscope (Contraves-Zeiss) is then brought in; the ligamentum flavum is incised, and a variable amount of the inferior portion of the superior lamina and the medial portion of the facet is removed to facilitate easy entry into the interlaminar space. The nerve root and disc pathology is readily identified. The epidural fat is carefully preserved and epidural veins may be coagulated with bipolar forceps. After removal of the ruptured portion of the disc fragment(s), a window is cut into the anulus fibrosus and a radical discectomy is done with rongeurs and ring curettes. At the conclusion of the decompression, the surgeon has an excellent view of the shoulder, axilla and as much as 2.5 cm of the nerve root as well as the adjacent dura. With probes, one can palpate across the midline for medially placed lesions, and superiorly and inferiorly for migrated fragments. If necessary, the same exposure will permit the surgeon to perform a

foraminotomy, facetectomy, unilateral laminectomy and remove osteophytes from the superior and inferior margins of the vertebral bodies. Bilateral exposures, or exposure of adjacent interlaminar spaces are readily accomplished with this technique but may require lengthening of the skin incision. Microsurgical discectomy is never appropriate for patients suffering from spinal stenosis who require multiple level exposures, bilateral laminectomies and foraminotomies.

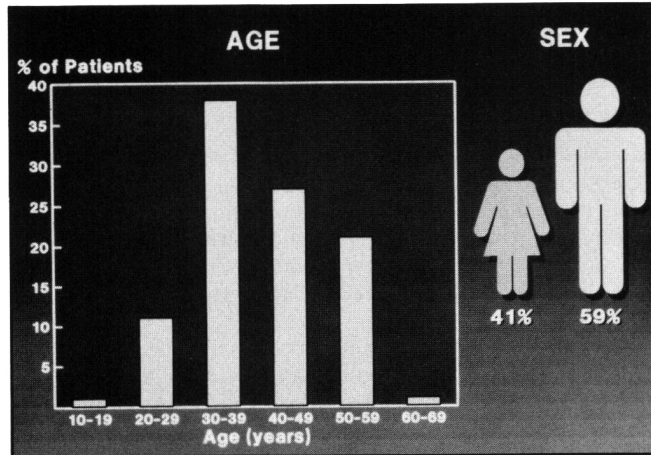


Figure 1 — Age and sex distribution in 200 patients.

Patient Selection

The age and sex distributions of the patients are shown in Figure 1. The majority of patients were between 30 and 60 years of age. Fifty-nine percent of the patients were male. The patients' occupations were described as heavy work in 29%, light work in 32% and sedentary in 39%. The number of previous episodes of sciatica and the duration of the current episode are both listed in Figure 2. Twenty-nine percent of patients had more than five previous episodes, 33% of patients had between two and five previous episodes and 38% of patients had less than two episodes. Fifty-three percent of patients had sciatica for more than six months prior to surgery. Patients with duration of symptoms shorter, less than one month, were usually those with serious neurological deficits requiring early surgery. Thirteen percent of the patients had had previous lumbar disc surgery and 10% of patients were receiving Workers' Compensation. Eighty-seven percent of patients had had at least two weeks of complete bed rest with bathroom privileges. Sixty-two percent of patients had received physiotherapy and 40% had been manipulated by a chiropractor.

Eighty-seven percent of patients had aggravation of leg pain on coughing, and 92% had limitation of straight leg raising. Eighty-five percent had limitation of trunk flexion (fingertips to the knees, or less), and 53% had some degree of scoliosis. Sixty percent demonstrated muscle weakness in a nerve root distribution and 43% had a reduced or absent ankle reflex. The knee reflex was reduced in 9%. The metrizamide myelogram or CT scan was positive at the L4-5 level in 54%, at the L5-S1 level in 43%, at the L3-4 level in 6%, at the L2-3 and L1-2 levels in 7%. Ten percent (20 patients) had radiographic evidence of two level pathology at L4-5 and L5-S1. The myelogram or CT scan was considered normal in 7%. Two percent of patients showed a complete block on myelography and the rest showed variable degrees of nerve root compression.

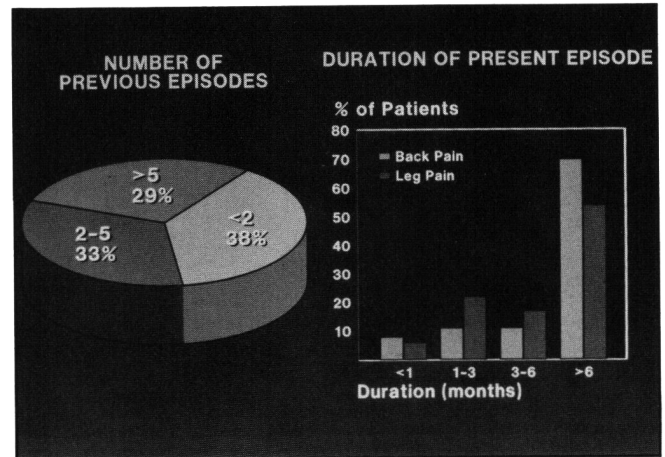


Figure 2 — Number of previous episodes of sciatica, and the duration of the present episode in 200 patients.

The duration of surgery was less than one hour in 74% of patients and blood loss was less than 50 cc in 99% of patients. The operative findings were as follows: frank sequestrated fragment of disc in 46% of patients, subligamentous extrusion in 42%, simple protrusion (bulging) in 15%, migrated free fragment in 18% and lateral recess stenosis in 12%. Thirteen percent of patients had a combination of pathological findings, most often lateral recess stenosis and a bulging disc. A radical discectomy was done in 94% and a facetectomy in 12%. Removal of the ruptured fragment alone, without clearing out the disc space ("lumpectomy") was done only once, in a patient who had a previous Chymopapain injection. All patients were allowed out of bed on the day of operation.

RESULTS

During their post-operative stay in hospital, fifty-three percent of patients required less than two doses of morphine and the rest were able to manage with codeine (30-60 mgm). The length of post-operative hospital stay is shown in Figure 3. Fifty-two percent of patients were able to go home within two days. Only one patient required post operative urinary catheterization. One patient developed a superficial wound infection (0.5%), one patient developed post-operative pneumonia (0.5%), and a variety of other complications occurred in another seven

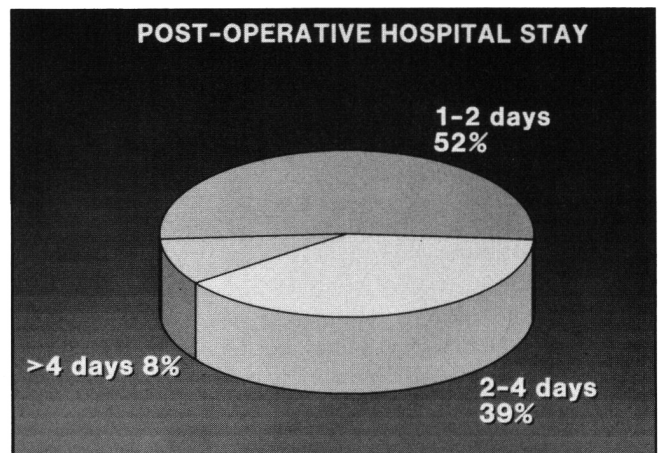


Figure 3 — Post-operative hospital stay in 200 patients.

patients (3.5%). These included urinary infection (2 patients), angina (2 patients), exacerbation of lupus erythematosus (1 patient), and retained subcuticular wire (2 patients).

All patients have been followed for a minimum of one year. Patients returned to work at one, three and twelve months post-operatively at the rate of 50%, 83% and 95% respectively. Those patients who had had previous lumbar disc surgery did as well as those with first time surgery, although they tended to have more post-operative back pain. Leg pain was improved at one, three, and twelve months post-operatively at the rate of 100%, 100% and 97% respectively. Back pain was improved at one, three, and twelve months post-operatively at the rate of 90%, 80% and 72% respectively. Recurrent disc herniations causing back and leg pain requiring a second microsurgical discectomy occurred in 3.5%. Two patients (1%) developed severe back pain with muscle spasm which required readmission to hospital two and three weeks post-operatively. The diagnosis of "aseptic discitis" was proven in one patient by negative cultures from needle aspirations and assumed in the other patient by an elevated ESR (>100) and typical x-ray changes. One patient died of a myocardial infarct three months after surgery. One patient had an inappropriate microsurgical discectomy for an osteoarthritic hip missed on physical examination. Of the 20 patients (10% of the total) who were on Workers' Compensation, six had to be considered failures because they did not return to work. The dura was torn and repaired during surgery in one patient and no patient was worse neurologically after surgery.

At three and twelve months post-operatively, follow-up assessment was done at the University of Toronto Pain Clinic. At each of these time intervals, a complete history and physical examination were performed; all patients were also evaluated by means of the Toronto Pain Questionnaire⁶ (verbal intensity scale), the pain visual analogue scale⁷ and the Beck Depression Scale.⁸ The vast majority of patients had no pain or only mild degrees of pain at the time of these follow-ups. Those patients who were depressed on the Beck Depression Scale were generally those with moderate and severe pain. There was a tendency to improvement as time progressed.

DISCUSSION

The term microsurgical discectomy seems to be preferable to other terms, such as microdiscectomy or micro lumbar discectomy, since it implies the application of microsurgical techniques to a well established and standard technique. The other terms might imply removal of only the sequestered fragment. That microsurgical discectomy is a highly effective and safe procedure in patients with intractable sciatica can no longer be denied. The advantages are a minimum of post-operative pain, early mobilization and quick, expedient discharge from hospital. The theoretical advantages include less tissue dissection and retraction, preservation of epidural fat, little nerve root retraction and preservation of the facet joints, and therefore decreased likelihood of late perineural fibrosis or facet joint arthritis.

Although the operation can be done without a surgical assistant, the microscope provides an excellent teaching opportunity for residents, nurses and students, especially when it is equipped with a diploscope, an observer tube and a television camera. Magnification and illumination provide unexcelled visualization and exposure of the operative field. Critics of the technique who suggest that visualization is compromised by the small exposure are inaccurate.

Recurrent disc protrusions at the operated level remain a vexing problem. Despite radical discectomies in this group of patients, the recurrence rate was 3.5%. The recurrence rate in this paper compares favourably with that reported by Goald (7.6%),⁴ William (9%)³ and Maroon (6.4%).² It is unlikely that recurrences represent "missed fragments" from the initial operation since the ruptured fragments are usually located in easily accessible places, often at the shoulder of the root, and are not likely to be missed with the excellent visibility and thorough exploration permitted by the microsurgical technique. Regeneration of disc material is very unlikely. It is probable that recurrent protrusions occur because fragments break away and migrate from areas of the disc space which are difficult and unsafe to completely evacuate during the initial surgery, such as the anterior and contralateral portion of the disc. Surgical repair of the anulus fibrosus after discectomy might prevent some recurrences.

The microsurgical approach to recurrent disc herniations is particularly advantageous. With the excellent illumination and magnification provided by the microscope, it becomes safer and easier to proceed with sharp dissection around the nerve root, and to correctly identify extradural scar tissue, dura, perineural adhesions, disc fragment(s) and the nerve root with the aid of the microscope.

Microsurgical technique permits the least amount of injury to normal tissue, is followed by minimal post-operative pain, allows early mobilization and early discharge from hospital, and gives a very high chance of complete relief of symptoms. It is too early to determine whether the longer term results are substantially different from those of standard discectomy, but the highly satisfactory results at 12 months are most promising.

REFERENCES

1. Fager CA. Lumbar microdiscectomy: a contrary opinion. *Clin Neurosurg* 1986; 33: 419-456.
2. Maroon JC. Microlumbar discectomy. *Clin Neurosurg* 1986; 33: 407-418.
3. Williams RW. Microlumbar discectomy; a conservative approach to the virgin herniated lumbar disc. *Spine* 1978; 3: 175-182.
4. Goald H. Microlumbar discectomy: follow-up of 477 patients. *J Microsurg* 1980; 2: 95-100.
5. Yasargil MG. Microsurgical operations for herniated lumbar disc. *Adv Neurosurg* 1977; 4: 81.
6. Melzack R, Wall PD, eds. *Textbook of Pain*. New York: Churchill Livingstone, 1984; 195.
7. Huskisson E. Visual Analogue Scale. *In*: Melzack R, ed. *Pain Management and Assessment*. New York: Raven Press, 1983; 33-37.
8. Becker AT, Ward CH, Mendelson M, et al. An inventory for measuring depression. *Arch Gen Psychiat* 1961; 4: 561-571.