



Original Article

Outcomes of CyberKnife Radiosurgery for Trigeminal Neuralgia in Patients with Multiple Sclerosis

Albert Guillemette^{1,2} , David Roberge^{1,3}, Cynthia Ménard^{1,3}, Jean-Paul Bahary^{1,3}, Elie Bou Assi^{1,4},
Dang Khoa Nguyen^{1,4,5}, Sami Obaid^{1,6,7} and Marie-Pierre Fournier-Gosselin^{1,6,7} 

¹Centre de Recherche du Centre hospitalier de l'Université de Montréal (CRCHUM), Montreal, Quebec, Canada, ²Department of Biomedical Sciences, Université de Montréal, Montreal, Quebec, Canada, ³Department of Radiation Oncology, Centre hospitalier de l'Université de Montréal (CHUM), Montreal, Quebec, Canada, ⁴Department of Neuroscience, Université de Montréal, Montreal, Quebec, Canada, ⁵Division of Neurology, Centre hospitalier de l'Université de Montréal (CHUM), Montreal, Quebec, Canada, ⁶Service of Neurosurgery, Centre hospitalier de l'Université de Montréal (CHUM), Montreal, Quebec, Canada and ⁷Department of Surgery, Université de Montréal, Montreal, Quebec, Canada

ABSTRACT: Background: The outcomes of radiosurgery for trigeminal neuralgia (TN) in patients with multiple sclerosis (MS) are not as extensively assessed as those for idiopathic or classical TN cases. **Objective:** Evaluate the safety and efficacy of radiosurgery for TN in MS patients and identify potential predictors of successful outcomes. **Methods:** A retrospective single-institution cohort study with patients treated between 2009 and 2022 was performed. Fifty patients were included, and a total of 68 radiosurgical interventions were delivered. Outcomes included the maintenance of pain relief assessed using Kaplan–Meier curves and treatment-related complications. Cox regression analyses were used to identify potential predictors of better pain relief. **Results:** Following the first radiosurgical treatments, the initial pain relief rate was 86% after a median latency period of 14 days. Adequate pain relief rates at 6, 12, 36 and 60 months were 86%, 52%, 35% and 24%, respectively. Adequate pain relief was sustained for an actuarial median of 12.7 months. After initial relief, pain recurrence occurred in 68% of patients. No statistical difference was seen in the duration of pain relief after initial or repeat radiosurgery ($p = 0.368$). The most frequent complication was facial hypesthesia (Barrow Neurological Institute facial hypesthesia scale grade II: 10%; III: 6%; IV: 0%). Ipsilateral vascular compression was predictive of better efficacy ($p = 0.024$). **Conclusion:** Radiosurgery for TN in patients with MS appears to be safe and to provide effective pain relief. Notably, radiological identification of vascular compression may predict more sustained pain relief.

RÉSUMÉ : Résultats de la radiochirurgie CyberKnife pour la névralgie du trijumeau chez les patients atteints de sclérose en plaques.

Contexte : Les résultats de la radiochirurgie pour la névralgie du trijumeau (NT) chez les patients atteints de sclérose en plaques (SP) ne sont pas aussi bien évalués que ceux qui concernent des cas de névralgie du trijumeau idiopathique ou classique. **Objectif :** Évaluer la sécurité et l'efficacité de la radiochirurgie pour la NT chez les patients atteints de SP et identifier les prédicteurs potentiels de résultats positifs. **Méthodes :** Une étude de cohorte rétrospective a été menée dans un seul établissement de santé auprès de patients traités entre 2009 et 2022. Au total, 50 d'entre eux ont été inclus tandis qu'un total de 68 interventions radio-chirurgicales ont été réalisées. Les résultats comprenaient le maintien du soulagement de la douleur, lequel a été évalué à l'aide des courbes de Kaplan-Meier, ainsi que des complications liées au traitement. Des analyses de régression à partir du modèle de Cox ont été utilisées pour identifier les prédicteurs potentiels d'un meilleur soulagement de la douleur. **Résultats :** Après les premiers traitements radio-chirurgicaux, le taux de soulagement initial de la douleur était de 86 % après une période de latence médiane de 14 jours. Les taux de soulagement adéquat de la douleur à 6, 12, 36 et 60 mois étaient respectivement de 86 %, 52 %, 35 % et 24 %. Le soulagement adéquat de la douleur a également été maintenu pendant une médiane actuarielle de 12,7 mois. Après le soulagement initial, la douleur est réapparue chez 68 % des patients. Aucune différence statistique n'a été observée dans la durée du soulagement de la douleur après la radiochirurgie initiale ou répétée ($p = 0,368$). La complication la plus fréquente était l'hypoesthésie faciale (échelle d'hypoesthésie faciale du Barrow Neurological Institute : grade II : 10 % ; III : 6 % ; IV : 0 %). Enfin, notons que la compression vasculaire ipsilatérale s'est révélée prédictive d'une meilleure efficacité ($p = 0,024$). **Conclusion :** La radiochirurgie pour la NT chez les patients atteints de SP semble être sécuritaire et soulager efficacement la douleur. En particulier, l'identification radiologique de la compression vasculaire peut permettre de prédire un soulagement plus durable de la douleur.

Keywords: CyberKnife; multiple sclerosis; radiosurgery; trigeminal neuralgia; facial pain; Gamma Knife

(Received 3 October 2024; final revisions submitted 13 January 2025; date of acceptance 10 February 2025)

Corresponding author: Marie-Pierre Fournier-Gosselin; Email: marie-pierre.fournier-gosselin@umontreal.ca

Sami Obaid and Marie-Pierre Fournier-Gosselin are co-senior author.

Cite this article: Guillemette A, Roberge D, Ménard C, Bahary J-P, Bou Assi E, Nguyen DK, Obaid S, and Fournier-Gosselin M-P. Outcomes of CyberKnife Radiosurgery for Trigeminal Neuralgia in Patients with Multiple Sclerosis. *The Canadian Journal of Neurological Sciences*, <https://doi.org/10.1017/cjn.2025.37>

© The Author(s), 2025. Published by Cambridge University Press on behalf of Canadian Neurological Sciences Federation. This is an Open Access article, distributed under the terms of the Creative Commons Attribution licence (<https://creativecommons.org/licenses/by/4.0/>), which permits unrestricted re-use, distribution and reproduction, provided the original article is properly cited.

Highlights

- CyberKnife radiosurgery provided significant acute pain relief, which gradually weaned over time.
- An ipsilateral neurovascular conflict was a predictor of more sustained pain relief.
- The rate of complications was acceptable, and side effects were tolerable in most cases.

Introduction

According to the International Classification of Headache Disorders, trigeminal neuralgia (TN) is defined as “a disorder characterized by recurrent unilateral brief electric shock-like pains, abrupt in onset and termination, limited to the distribution of one or more divisions of the trigeminal nerve and triggered by innocuous stimuli.”¹ In severe cases, TN can significantly impair the quality of life of affected patients, potentially leading to psychiatric disorders such as depression and anxiety, undernourishment and severe dehydration.^{2,3}

TN affects 3%–4% of multiple sclerosis (MS) patients, who have about a 20-fold increased risk of developing TN compared to the general population.^{4,5} Pharmacotherapy with antiseizure medications (ASM), such as carbamazepine, is the first line of treatment and is effective in 50%–60 % of cases.⁶ However, even for patients who respond to ASM, optimal pain relief is often limited by the poor tolerability of the high doses required, especially as ASMs can exacerbate neurological symptoms related to MS.⁷

For MS patients with intolerable medication side effects or inadequate pain relief, radiosurgery (typically Gamma Knife [GK] or CyberKnife [CK]) is a viable alternative. Yet, there are limited data on the clinical outcome and potential predictive factors of efficacy in this vulnerable population.^{8–12} To date, most of the available data pertain to the GK technique, while CK remains poorly documented. This scarcity is due to CK being a newer and less commonly used technique. CK has unique delivery properties, which underscores the need to conduct additional research to better understand the outcomes associated with this technique. The objectives of this study were thus to evaluate the efficacy and safety of CK radiosurgery in TN patients with MS, as well as to identify potential predictors of efficacy.

Methods

Study design

This study is a single-institution retrospective assessment. It was approved by the Centre de Recherche du Centre hospitalier de l'Université de Montréal research ethics board and conformed to the Declaration of Helsinki. The electronic medical records of patients treated at our institution between 2009 and 2022 were reviewed.

Participants

Patients with MS and refractory TN were included if they had undergone at least one CK treatment and had at least one post-treatment follow-up. Follow-ups were typically scheduled at 2, 6 and 12 months after treatment, followed by annual assessments. Of the 52 patients who were screened for eligibility, two were lost to follow-up and were excluded, leaving a total of 50 patients meeting the inclusion criteria. Notably, 1 patient underwent bilateral

treatment, resulting in 51 nerves included. Moreover, 17 patients underwent a repeat CK, accounting for a total of 68 CK treatments. Table 1 summarizes the demographic, clinical and radiological characteristics of all included patients.

Radiosurgical technique

Radiosurgical treatments were performed using CyberKnife G4 (2009–2012), VSI (2012–2017) and M6 (2017–2022) systems (Accuray Inc., Sunnyvale, USA). Treatment planning was performed on the MultiPlan or Precision platforms (Accuray Inc.) using a native high-resolution CT scan co-registered with a T1-weighted balanced steady-state gradient echo sequence with high cerebrospinal fluid/trigeminal nerve contrast and T2-weighted sequences. This step was conducted by a team of radiation oncologists (D.R., C.M., J-P.B.), medical physicists and a functional neurosurgeon (M-P.F-G.). Radiosurgical targeting was planned along the cisternal portion of the trigeminal nerve based on the nerve anatomy (length) and its proximity to critical structures (e.g., the temporal lobe, brainstem and optic nerve). For first treatments, the median maximal dose was 80 Gy (range 70.0–88.9). For repeat treatments, the median maximal dose was 60 Gy (range 60.0–70.0). As opposed to other CK approaches, where a cylindrical 5–6 mm segment of the nerve is treated, a treated volume more closely resembling a sphere was constructed by identifying a small volume on the nerve in two or three consecutive axial MRI images. Treatment duration was between 30 and 45 minutes.

Clinical outcomes: efficacy and safety

The outcomes studied were pain relief and radiation-induced complications, including facial hypesthesia. Pain relief was evaluated using the Barrow Neurological Institute (BNI) scale of pain intensity (I–V),¹³ in which a score of I indicates complete pain relief without medication, II indicates occasional pain not requiring medication, IIIa indicates no pain with continued medication, IIIb indicates persistent pain controlled with medication, IV indicates some pain not adequately controlled with medication and V indicates severe pain or no relief. BNI scores I–IIIb were considered adequate pain relief, and scores IV–V were classified as unsatisfactory relief. Facial hypesthesia was evaluated with the BNI scale of facial numbness (I–IV),¹³ in which a score of I denotes no facial numbness, II denotes mild non-bothersome numbness, III denotes somewhat bothersome numbness and IV denotes very bothersome numbness.

Imaging data analysis

MRI images (T1 and T2-weighted sequences) used for radiosurgery planning were systematically reanalyzed as part of the study to identify MS plaques and neurovascular conflicts. The presence of MS plaques along trigeminal afferents within the brainstem (pons or medulla oblongata) or at the root entry zone (REZ) was evaluated by the same investigator with content expertise (M-P.F-G.). A plaque was defined as a T1 hypointense/T2 hyperintense white matter lesion. In all cases except one, a demyelinating plaque in the REZ or pons was identified. The last case consisted of a patient with numerous demyelinating plaques in the medulla oblongata. The presence of a neurovascular conflict in the cisternal segment of the nerve was also assessed. A neurovascular conflict was considered significant when no cerebrospinal fluid was observed between the trigeminal nerve and a vessel (i.e., the superior cerebellar artery,

Table 1. Demographic, clinical and radiological data

Characteristic	No. of cases (%)
Number of cases (nerves treated)	51
Number of radiosurgical treatments delivered	68
First RS treatments	51 (75.0)
Repeat RS treatments	17 (25.0)
Sex	
Male	14 (27.5)
Female	37 (72.5)
Median age in years at first RS (range)	60.0 (26–84)
Median duration of symptoms in months at first RS (range)	62.5 (6–240)
Side treated	
Right	24 (47.1)
Left	27 (52.9)
Branches of the trigeminal nerve involved	
V1	2 (3.9)
V2	2 (3.9)
V3	20 (39.2)
V1+V2	4 (7.8)
V1+V3	0 (0.0)
V2+V3	18 (35.3)
V1+V2+V3	5 (9.8)
Active smokers	9 (17.6)
Imaging evidence of a cisternal neurovascular conflict	31 (60.8)
Prior percutaneous surgeries	4 (7.8) ^a
RFA	2 (3.9)
PBC	1 (2.0)
PBC + RFA	1 (2.0)
Baseline facial hypesthesia ^b	
I	42 (82.4)
II	9 (17.6)
III	0 (0.0)
IV	0 (0.0)
Facial hypesthesia before repeat RS treatments ^b	
I	13 (76.5)
II	4 (23.5)
III	0 (0.0)
IV	0 (0.0)
Median maximal dose in Gy at first RS (range):	80 (70.0–88.9)
Median maximal dose in Gy at repeat RS (range):	60 (60.0–70.0)

^aNumber of patients that underwent prior percutaneous surgeries. ^bHypesthesia is reported using the Barrow Neurological Institute facial hypesthesia scale. RS = radiosurgery; RFA = radiofrequency ablation; PBC = percutaneous balloon compression.

the superior petrosal vein or, in rare cases, the anterior inferior cerebellar artery).

Statistical analysis

Kaplan–Meier curves were used to evaluate pain relief at 6, 12, 36 and 60 months. Univariate analyses were conducted using a Cox proportional hazards model to identify potential predictors of sustained pain relief, focusing exclusively on first radiosurgical treatments. All statistical analyses were conducted using the open-source software Jamovi (version 1.6; retrieved from <https://www.jamovi.org>). Results were considered significant when *p* values were ≤ 0.05 .

Results

Efficacy

Table 2 details the efficacy outcomes of radiosurgery. Following the first treatments (51 cases), the median follow-up period was 43.9 months (range 3.9–174.4), and initial pain relief occurred in 86.3% of patients. The median latency period before treatment response was 14 days (range 0–152). Pain recurrence occurred in 68.2% of patients after an actuarial median of 12.7 months.

After repeat treatments (17 cases), the median follow-up period was 34.8 months (range 4.6–128.9), and initial pain relief occurred in 82.4% of patients. The median latency period before treatment response was 14 days (range 0–201). Pain recurred in 41.2% of patients after an actuarial median of 13.2 months.

After the first treatments, actuarial rates of sustained pain relief at 6, 12, 36 and 60 months were 86.0%, 52.2%, 35.0% and 24.2%, respectively. Following repeat treatments, rates were 85.7%, 62.3%, 46.8% and 46.8%, respectively. There was no difference in the maintenance of pain relief between first and repeat treatments (HR: 0.68; CI: 0.30–1.56; *p* = 0.368). For all treatments combined (first and repeat), rates of sustained pain relief at 6, 12, 36 and 60 months were 85.9%, 54.6%, 37.7% and 28.9%, respectively. A Kaplan–Meier plot of sustained pain relief is shown in Figure 1. After treatment failure, the most common salvage therapy was radiofrequency ablation (21.6%), followed by other percutaneous rhizotomies.

Safety

Table 3 outlines the complications induced by radiosurgery. After the first treatments, the most common complication was facial hypesthesia, found in 15.7% of cases. This facial numbness was non-bothersome in 9.8% (BNI II) and somewhat bothersome in 5.9% of cases (BNI III). No patient developed anesthesia dolorosa. A decreased corneal blink reflex was observed in 7.8% of cases, and dry eye/keratitis was seen in 2%. Transient masticatory weakness was reported in 2% of the cases.

Just as in first treatments, the most frequent complication after repeat radiosurgery was facial hypesthesia, occurring in 41.2% of cases (non-bothersome – BNI II – in 29.4%; somewhat bothersome – BNI III – in 11.8%). No patient developed anesthesia dolorosa. A decreased corneal blink reflex was observed in 11.8% of cases, and 5.9% reported dry eye or keratitis.

Predictors of efficacy

An ipsilateral cisternal neurovascular conflict was identified in 63.6% of cases with an adequate first treatment response. Among these cases, actuarial rates of sustained pain relief at 6, 12, 36 and 60 months were 92.7%, 62.6%, 49.5% and 32.5%, respectively. For cases without a neurovascular conflict, these rates were 71.8%, 35.9%, 9.0% and 9.0%, respectively. A Kaplan–Meier plot of sustained pain relief stratified by the presence or absence of vascular compression is shown in Figure 2. The presence of such conflict was identified as a predictor of more sustained pain relief (HR: 0.41; CI: 0.19–0.89; *p* = 0.024). Factors such as patient sex (HR: 1.70; CI: 0.69–4.18; *p* = 0.249), active smoking (HR: 2.19; CI: 0.86–5.56; *p* = 0.098) and treatment-induced facial hypesthesia (HR: 0.37; CI: 0.13–1.09; *p* = 0.071) did not emerge as statistically significant predictors of sustained pain relief.

Table 2. Efficacy outcomes following radiosurgery

Outcomes	First RS (%)	Repeat RS (%)
Median follow-up in months (range) ^a	43.9 (3.9–174.4)	34.8 (4.6–128.9)
Initial adequate pain relief ^b	44 (86.3)	14 (82.4)
Median pain relief latency period in days after RS (range)	14 (0–152)	14 (0–201)
Unsatisfactory relief ^c	30 (68.2)	7 (41.2)
Actuarial median duration of pain relief in months	12.7	13.2
Salvage therapy	27 (52.9) ^c	
RFA	11 (21.6)	
PBC	1 (2.0)	
GR	2 (3.9)	
2 RFA	5 (9.8)	
RFA + PBC	2 (3.9)	
GR + RFA	1 (2.0)	
2 RFA + PBC	2 (3.9)	
2 PBC + RFA	1 (2.0)	
4 RFA	1 (2.0)	
GR + 6 RFA	1 (2.0)	

^aFollow-up distributions are presented as supplementary material. ^bPain relief was assessed using the Barrow Neurological Institute scale of pain intensity, with a BNI I–IIIb corresponding to adequate relief. ^cNumber of patients that underwent salvage therapy. RS = radiosurgery; RFA = radiofrequency ablation; PBC = percutaneous balloon compression; GR = glycerol rhizotomy.

Table 3. Safety outcomes following radiosurgery

Complications	First RS (%)	Repeat RS (%)
Development or worsening of hypesthesia (BNI scale ^a):	8 (15.7)	7 (41.2)
II	5 (9.8)	5 (29.4)
III	3 (5.9)	2 (11.8)
IV/anesthesia dolorosa	0 (0.0)	0 (0.0)
Decreased corneal blink reflex	4 (7.8)	2 (11.8)
Keratitis/dry eye	1 (2.0)	1 (5.9)
Transient masticatory weakness	1 (2.0)	0 (0.0)

^aThe development or worsening of hypesthesia was assessed using the Barrow Neurological Institute facial hypesthesia scale. RS = radiosurgery.

Discussion

There is a lack of data on the use of radiosurgery for TN patients with MS, especially as it pertains to the CK technique. This prompted a retrospective assessment of the safety and efficacy of this technique in this vulnerable population. There are several main novel findings in the current study: (a) CK radiosurgery provided significant acute pain relief, which gradually weaned over time; (b) the presence of a neurovascular conflict was identified as a predictor of more sustained pain relief; (c) the rate of complications was acceptable, and side effects were tolerable in most cases; (d) the most common complication was facial hypesthesia; and (e) although slightly more morbid, repeat

treatments seem to be as effective as first treatments in achieving and maintaining pain relief.

Efficacy and predictors of pain relief

Overall, CK successfully provided acute pain relief, with its efficacy gradually lessening over time. The initial pain relief rate after the first treatments was 86.3%, which is similar to the 83% rate reported in a recent meta-analysis by Spina et al. (2021) on GK for TN in patients with MS.¹¹ Initial pain relief occurred at a median of 14 days, which is faster than typically observed in GK cohorts.^{8,12} This rapid response may be attributed to the distinctive non-isocentric delivery properties of the CK technique compared to the isocentric approach of the GK. However, as this is the first study exclusively dedicated to CK in MS patients, further validation is necessary to confirm this unprecedented finding. The sustained pain relief rates (86.0% at 6 months, 52.2% at 12 months, 35.0% at 36 months and 24.2% at 60 months) were comparable to those reported in larger studies,^{8–10,14} which documented pain relief ranging from 54% to 85% at 12 months, 35% to 65% at 24 months, 55% to 57% at 36 months, 24% to 44% at 48 months and 52% to 57% at 60 months.^{8–10,14}

In an effort to optimize candidate selection for radiosurgery, we further assessed whether specific clinical and radiological factors contributed to persistent pain relief. Interestingly, the presence of a cisternal vascular compression was identified as a predictor. Although this finding has not been documented in MS patients, it has been observed in non-MS cohorts.^{15,16} This favorable response in non-MS, classical TN patients with a neurovascular conflict may be attributed to the underlying pathophysiology of the disorder. In this regard, in classical TN, the commonly accepted mechanism for the painful symptoms is that mechanical compression by surrounding vessels results in focal demyelination.^{17,18} To support this, recent neuroimaging studies reported white matter abnormalities in the cisternal segment of the trigeminal nerve.^{19,20} This demyelination process affects thickly myelinated sensory fibers, likely leading to ectopic excitation, high-frequency discharges and ephaptic transmission to nociceptive fibers, generating painful signals.^{21,22} Although the mechanism of action of radiosurgery in classical TN is not entirely clear, it is recognized that radiation, which targets the cisternal segment of the nerve where the aforementioned pathological processes occur, may directly interrupt the transmission of nociceptive impulses through a local inhibitory effect.^{23,24}

To date, the pathophysiology of TN in patients with MS remains incompletely understood, but most authors agree that demyelinating plaques are the main contributors to the painful symptoms. Indeed, in their neuroimaging study assessing microstructural abnormalities in MS patients, Chen et al. (2016) reported white matter lesions in the pontine tract of the trigeminal nerve.²⁵ Although this explanation is compelling, it is important to note that in many MS cases, vascular compression coexists with a plaque.^{17,26,27} Just like in classical TN cases, this vascular compression may also contribute to the painful symptoms. Interestingly, an elegant neuroimaging study by Truini et al. (2016) reported that demyelination and vascular compression could act synergistically to elicit pain, a theory they coined the “double-crush mechanism.” The authors suggested that these two processes could give rise to distinct types of lesions affecting the trigemino-thalamic tract, an inflammatory lesion of the central myelin and a mechanical injury affecting the peripheral myelin sheaths.^{28,29} More advanced neuroimaging techniques that

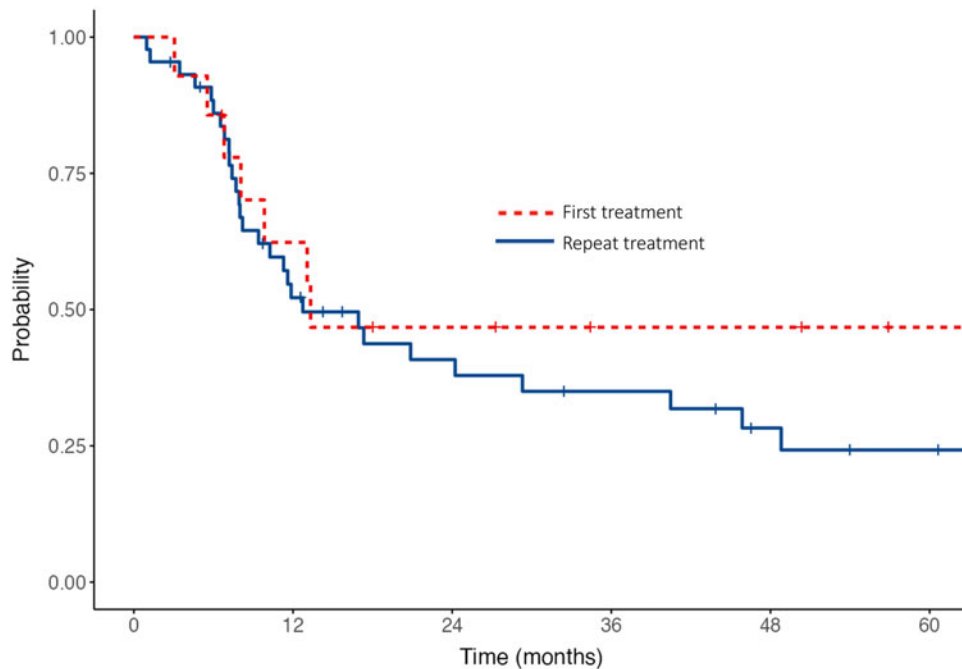


Figure 1. Kaplan-Meier curves of the maintenance of adequate pain relief stratified by whether the radiosurgery treatment was the first or repeat treatment.

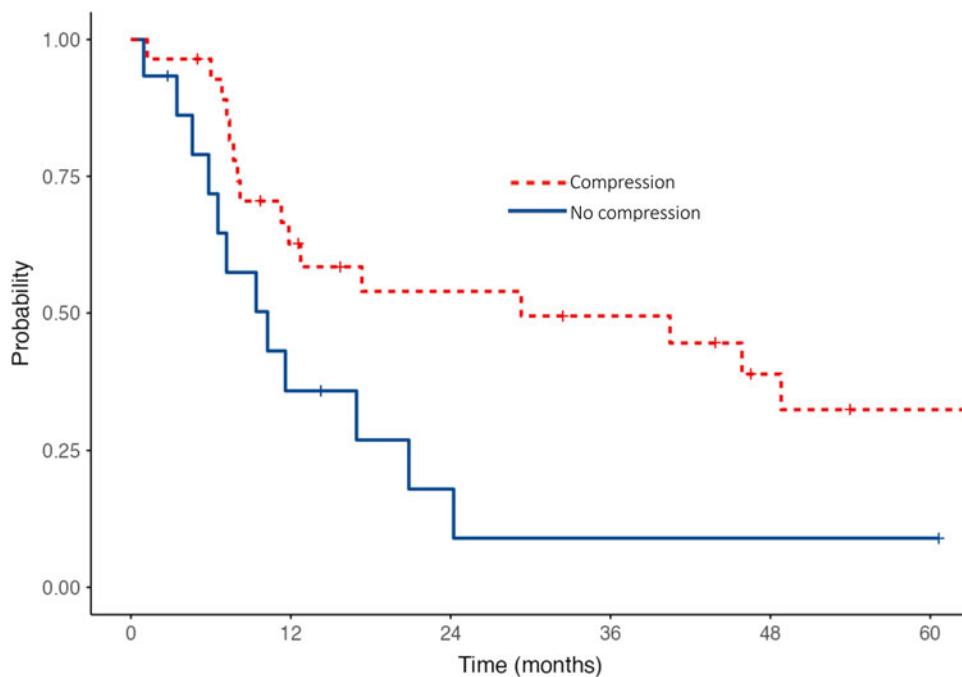


Figure 2. Kaplan-Meier curves of the maintenance of adequate pain relief after first radiosurgery treatments stratified by the presence or absence of vascular compression.

highlight microarchitectural features would aid in understanding the extent to which this double mechanism contributes to the pathophysiology.

Beyond potentially unveiling the drivers of painful stimuli, the double crush mechanism theory may also explain why MS patients with neurovascular conflicts benefit from more sustained pain relief following radiosurgery. Indeed, according to this theory, these patients also exhibit pathological processes resulting from the vascular compression itself, making radiosurgery potentially more effective for them through local peripheral mechanisms unrelated to demyelinating plaques.^{23,24} Conversely, in cases where a

demyelinating plaque in the brainstem is the sole contributor to the symptoms, radiosurgery – which does not target the central myelin – has minimal impact on the primary pain generator, potentially resulting in less effective pain relief. To our knowledge, no study identified vascular compression as a predictor of better efficacy of radiosurgery for TN in MS. This novel finding is clinically pertinent as it may help streamline the best candidates for radiosurgery, though further validation is needed.

Active smokers did not exhibit better pain relief than nonsmokers ($p = 0.098$), contrasting with Weller et al. (2014), who hypothesized that smokers experience more beneficial

effects due to a more potent radiation effect on the demyelination process. Smoking may exacerbate radiosurgically induced demyelination, potentially leading to quicker nerve dysfunction, interruption of painful stimuli and better therapeutic effect.⁹ Although a statistical trend was observed, our results were not significant, likely due to the limited statistical power of our sample size.

In classical and idiopathic TN cases, cumulative evidence suggests that radiosurgically induced hypesthesia could predict efficacy.³⁰ Indeed, hypesthesia reflects significant radiosurgically induced axonal degeneration, a potent injury likely sufficient to interrupt peripheral painful signals.³¹ However, this predictive factor was not observed in the current study or in other MS studies.¹¹ This discrepancy may be attributed to the key role of demyelinating plaques in the pathophysiology. Because the pain in MS patients originates (at least in part) from these central plaques, which are located further along in the pain pathway than the trigeminal nerve (i.e., closer to the thalamus), it is not surprising that the extent of peripheral radiosurgical injury, reflected by sensory changes, may not be related to the efficacy of radiosurgery.

Safety

Our findings indicate that radiosurgery in MS patients with TN is a safe technique. The rate of hypesthesia after the first treatments was 15.7%, which is slightly higher than the 10% rate reported in the largest cohort study to date.^{8,11} After repeat treatments, hypesthesia was observed in 41.2% of patients. This increase is likely due to pre-existing nerve damage from the initial radiosurgical treatment, the cumulative effects of the natural progression of MS and the heightened susceptibility of MS patients to neurotoxicity.³² Thankfully, radiosurgically induced facial numbness was mild and not bothersome in most cases, reinforcing the safety of the technique.

Other treatment-related complications included decreased corneal blink reflex (7.8%), dry eye/keratitis (2%) and transient masticatory weakness (2%), though these occurred infrequently. Surprisingly, decreased corneal blink reflex was, to our knowledge, never reported in previous studies,^{8–12,33} which may be due to it either not being systematically examined or not being classified as a complication because of its typically benign nature. It is also possible that clinicians may consider it merely a form of hypesthesia in the first trigeminal division rather than a separate ophthalmological issue. However, we believe that recognizing it as a distinct complication is important, as untreated corneal reflex deficits could potentially lead to more severe issues, such as dry eye and keratitis.³⁴ In our study, the incidence of such more severe ophthalmological complications (i.e., dry eye/keratitis) fell within the range reported in the literature (0%–4.1%).^{8–12,33,35} Finally, one case of transient masticatory weakness was observed, a complication not documented in other studies of MS patients but noted in 1.5% of idiopathic TN cases.^{8–12,33,35,36}

Limitations and future implications

This retrospective study contains intrinsic limitations. First, because of its retrospective design, one can expect the influence of recall bias. Second, the radiological assessment was conducted by a single evaluator. Third, pertinent and potentially predictive neuroimaging data, such as the degree of vascular compression (displacement/distortion) and the size of demyelinating plaques, were not analyzed. Fourth, important radiosurgical data were not assessed in detail such as the variable target delineation associated

with the non-isocentric CK technique. Fifth, using spherical volumes for CK treatments could limit the generalization of our results, as cylindrical volumes are more commonly used. Sixth, the relatively small sample size of this study limited the power of our analysis, prompting a large multicentric CK cohort study to provide more robust results.

Conclusion

To date, this is the first assessment of CK for the treatment of TN in MS patients. Our study's findings on the efficacy and safety of CK for TN in MS patients align with previous GK reports. Given that other treatments, including microvascular decompression, have not conclusively shown effectiveness for these vulnerable patients, radiosurgery should be considered a good option due to its ability to provide pain relief with a low risk of complications.⁷ Notably, we observed that patients with MS and a neurovascular conflict appear to benefit the most from this approach. This novel insight could influence clinical decision-making and underscores the importance of adopting a tailored imaging protocol for assessing vascular loops in the cisternal region, even for patients with MS.

Supplementary material. The supplementary material for this article can be found at <https://doi.org/10.1017/cjn.2025.37>.

Acknowledgments. We sincerely thank the Fonds de recherche du Québec - santé (FRQS) and Canadian Institutes of Health Research (CIHR) for awarding research scholarships to AG.

Author contributions. AG, SO and MPFG designed the study. All authors collected the data for the study. AG, DR, CM, SO, DKN, EBA, JPB and MPFG wrote the initial manuscript. All authors provided feedback during the writing process.

Funding statement. No funding to report.

Competing interests. The authors declare that they have no other known competing financial interests or personal relationships that could have appeared to influence the work reported in this manuscript.

Disclosures. This work was supported by two graduate research scholarships awarded to AG (CIHR: Canada Graduate Scholarships – Master's; FRQS: Master's Training for Medical Student – MD - MSc). DR reports receiving travel support from Accuray.

References

1. Headache Classification Committee of the International Headache Society (IHS). The International Classification of Headache Disorders, 3rd edition. *Cephalalgia*; 2018;38(1):1–211.
2. Wu T-H, Hu L-Y, Lu T, et al. Risk of psychiatric disorders following trigeminal neuralgia: a nationwide population-based retrospective cohort study. *J Headache Pain*. 2015;16:64.
3. Knafo H, Kenny B, Mathieu D. Trigeminal neuralgia: outcomes after gamma knife radiosurgery. *Can J Neurol Sci*. 2009;36(1):78–82.
4. Katusic S, Williams DB, Beard CM, Bergstralh EJ, Kurland LT. Epidemiology and clinical features of idiopathic trigeminal neuralgia and glossopharyngeal neuralgia: similarities and differences, Rochester, Minnesota, 1945–1984. *Neuroepidemiology*. 1991;10(5-6):276–281.
5. Houshi S, Tavallaei MJ, Barzegar M, et al. Prevalence of trigeminal neuralgia in multiple sclerosis: a systematic review and meta-analysis. *Mult Scler Relat Disord*. 2022;57:103472.
6. Sangamesh NC, Bajoria AA, Mishra S, Behera S, Sahoo SK, Bal PK. Comparative assessment of the effectiveness of carbamazepine and baclofen in the management of trigeminal neuralgia. *J Pharm Bioallied Sci*. 2024;16(3):S2197–S2198. DOI: [10.4103/jpbs.jpbs_139_24](https://doi.org/10.4103/jpbs.jpbs_139_24).

7. Di Stefano G, Maarbjerg S, Truini A. Trigeminal neuralgia secondary to multiple sclerosis: from the clinical picture to the treatment options. *J Headache Pain*. 2019;20(1):20.
8. Xu Z, Mathieu D, Heroux F, et al. Stereotactic radiosurgery for trigeminal neuralgia in patients with multiple sclerosis: a multicenter study. *Neurosurgery*. 2019;84(2):499–505.
9. Weller M, Marshall K, Lovato JF, et al. Single-institution retrospective series of Gamma Knife radiosurgery in the treatment of multiple sclerosis-related trigeminal neuralgia: factors that predict efficacy. *Stereot Funct Neuros*. 2014;92(1):53–58.
10. Conti A, Pontoriero A, Iati G, et al. Frameless stereotactic radiosurgery for treatment of multiple sclerosis-related trigeminal neuralgia. *World Neurosurg*. 2017;103:702–712.
11. Spina A, Nocera G, Boari N, Iannaccone S, Mortini P. Efficacy of Gamma Knife radiosurgery in the management of multiple sclerosis-related trigeminal neuralgia: a systematic review and meta-analysis. *Neurosurg Rev*. 2021;44(6):3069–3077.
12. Alvarez-Pinzon AM, Wolf AL, Swedberg HN, et al. Comparison of percutaneous retrogasserian balloon compression and Gamma Knife radiosurgery for the treatment of trigeminal neuralgia in multiple sclerosis. *World Neurosurg*. 2017;97:590–594.
13. Rogers CL, Shetter A, Fiedler JA, Smith K, Han P, Speiser B. Gamma knife radiosurgery for trigeminal neuralgia: the initial experience of the Barrow Neurological Institute. *Int J Radiat Oncol Biol Phys*. 2000;47(4):1013–1019.
14. Franzini A, Tropeano MP, Olei S, et al. Gamma Knife radiosurgery for the treatment of trigeminal neuralgia in patients with multiple sclerosis: a single-center retrospective study and literature review. *World Neurosurg*. 2021;149:e92–e100.
15. Brisman R, Khandji AG, Mooij RB. Trigeminal nerve-blood vessel relationship as revealed by high-resolution magnetic resonance imaging and its effect on pain relief after Gamma Knife radiosurgery for trigeminal neuralgia. *Neurosurgery*. 2002;50(6):1261–1266. discussion 6–7.
16. Erbay SH, Bhadelia RA, Riesenburger R, et al. Association between neurovascular contact on MRI and response to gamma knife radiosurgery in trigeminal neuralgia. *Neuroradiology*. 2006;48(1):26–30.
17. Antonini G, Di Pasquale A, Cruccu G, et al. Magnetic resonance imaging contribution for diagnosing symptomatic neurovascular contact in classical trigeminal neuralgia: a blinded case-control study and meta-analysis. *Pain*. 2014;155(8):1464–1471.
18. Maarbjerg S, Wolfram F, Gozalov A, Olesen J, Bendtsen L. Significance of neurovascular contact in classical trigeminal neuralgia. *Brain*. 2015;138(Pt 2):311–319.
19. Fujiwara S, Sasaki M, Wada T, et al. High-resolution diffusion tensor imaging for the detection of diffusion abnormalities in the trigeminal nerves of patients with trigeminal neuralgia caused by neurovascular compression. *J Neuroimaging*. 2011;21(2):e102–e108.
20. Leal PRL, Roch JA, Hermier M, Souza MAN, Cristino-Filho G, Sindou M. Structural abnormalities of the trigeminal root revealed by diffusion tensor imaging in patients with trigeminal neuralgia caused by neurovascular compression: a prospective, double-blind, controlled study. *PAIN*. 2011;152(10):2357–2364.
21. Devor M, Amir R, Rappaport ZH. Pathophysiology of trigeminal neuralgia: the ignition hypothesis. *Clin J Pain*. 2002;18(1):4–13.
22. Devor M, Govrin-Lippmann R, Rappaport ZH. Mechanism of trigeminal neuralgia: an ultrastructural analysis of trigeminal root specimens obtained during microvascular decompression surgery. *J Neurosurg*. 2002;96(3):532–543.
23. Hodaie M, Chen DQ, Quan J, Laperriere N. Tractography delineates microstructural changes in the trigeminal nerve after focal radiosurgery for trigeminal neuralgia. *PLoS One*. 2012;7(3):e32745.
24. Kondziolka D, Lacomis D, Niranjan A, et al. Histological effects of trigeminal nerve radiosurgery in a primate model: implications for trigeminal neuralgia radiosurgery. *Neurosurgery*. 2000;46(4):971–976. discussion 6–7.
25. Chen DQ, DeSouza DD, Hayes DJ, Davis KD, O'Connor P, Hodaie M. Diffusivity signatures characterize trigeminal neuralgia associated with multiple sclerosis. *Mult Scler*. 2016;22(1):51–63.
26. Broggi G, Ferroli P, Franzini A, et al. Operative findings and outcomes of microvascular decompression for trigeminal neuralgia in 35 patients affected by multiple sclerosis. *Neurosurgery*. 2004;55(4):830–838. discussion 8–9.
27. Athanasiou TC, Patel NK, Renowden SA, Coakham HB. Some patients with multiple sclerosis have neurovascular compression causing their trigeminal neuralgia and can be treated effectively with MVD: report of five cases. *Br J Neurosurg*. 2005;19(6):463–468.
28. Pichiecchio A, Bergamaschi R, Tavazzi E, Romani A, Todeschini A, Bastianello S. Bilateral trigeminal enhancement on magnetic resonance imaging in a patient with multiple sclerosis and trigeminal neuralgia. *Mult Scler*. 2007;13(6):814–816.
29. Truini A, Prosperini L, Calistri V, et al. A dual concurrent mechanism explains trigeminal neuralgia in patients with multiple sclerosis. *Neurology*. 2016;86(22):2094–2099.
30. Tuleasca C, Regis J, Sahgal A, et al. Stereotactic radiosurgery for trigeminal neuralgia: a systematic review. *J Neurosurg*. 2018;130(3):733–757.
31. Gorgulho A. Radiation mechanisms of pain control in classical trigeminal neuralgia. *Surg Neurol Int*. 2012;3(Suppl 1):S17–S25.
32. Miller RC, Lachance DH, Lucchinetti CF, et al. Multiple sclerosis, brain radiotherapy, and risk of neurotoxicity: the Mayo Clinic experience. *Int J Radiat Oncol Biol Phys*. 2006;66(4):1178–1186.
33. Leduc W, Mathieu D, Adam E, Ferreira R, Iorio-Morin C. Gamma Knife stereotactic radiosurgery for trigeminal neuralgia secondary to multiple sclerosis: a case-control study. *Neurosurgery*. 2023;93(3):453–461.
34. Hoşal BM, Örnek N, Zilelioğlu G, Elhan AH. Morphology of corneal nerves and corneal sensation in dry eye: a preliminary study. *Eye*. 2005;19(12):1276–1279.
35. Helis CA, McTyre E, Munley MT, et al. Gamma Knife radiosurgery for multiple sclerosis-associated trigeminal neuralgia. *Neurosurgery*. 2019;85(5):E933–E939.
36. Mohammed N, Hung YC, Eluvathingal Muttikkal TJ, Bliley RC, Xu Z, Sheehan JP. Changes in the muscles of mastication before and after primary stereotactic radiosurgery in patients with idiopathic trigeminal neuralgia. *J Neurosurg*. 2019;134:1–8.