

Clival Chordoma Presenting with Acute Brain Stem Hemorrhage

Allan D.O. Levi, Walter Kucharczyk, Arnold P. Lang and Hart Schutz

ABSTRACT: The authors present a case of a 29-year-old man who developed rapidly progressive cranial nerve palsies and a right hemiparesis secondary to a pontine hemorrhage. The rare but correct diagnosis of a clival chordoma which had invaded the brain stem and subsequently hemorrhaged was based on computed tomography and magnetic resonance imaging. The diagnosis was confirmed at surgery when the patient underwent a successful operative decompression of tumor and clot from the pons via a sub-occipital craniotomy. This represents the first case of a clival chordoma to hemorrhage into the brain stem, which was diagnosed preoperatively and the patient survived.

RÉSUMÉ: Hémorragie aiguë du tronc cérébral comme présentation initiale d'un chordome du clivus Les auteurs présentent le cas d'un homme de 29 ans qui a développé une paralysie progressive des nerfs crâniens et une hémiparésie droite secondaires à une hémorragie au niveau du pont. Un diagnostic rare mais correcte de chordome du clivus avec invasion du tronc cérébral et hémorragie ultérieure a été posé sur la tomodensitométrie et l'imagerie par résonance magnétique. Le diagnostic a été confirmé à la chirurgie, quand le patient a subi avec succès une décompression de la tumeur et du caillot du pont par une crâniotomie sous-occipitale. C'est le premier cas d'un chordome du clivus ayant provoqué une hémorragie dans le tronc cérébral, dont le diagnostic a été posé avant la chirurgie, avec survie du patient.

Can. J. Neurol. Sci. 1991; 18: 515-518

Clival chordomas are uncommon intra-cranial tumors representing only 0.15-0.2% of primary brain tumors¹. Patients with chordomas usually present with an extended history of headache and multiple progressive cranial nerve palsies. We report a case of a clival chordoma presenting with hemorrhage into the pons. The diagnosis was made correctly preoperatively based on computed tomography and magnetic resonance imaging, and appears to be the first case in the literature to survive such an event.

CASE REPORT

A 29-year-old man complained of a two day history of right arm and leg weakness, and numbness of the right face and the right half of the body. He noted that his right hand was clumsy and he was unable to write. Also he would drag his right leg. On the day of admission, he fell in the bathroom secondary to his right sided weakness. There was no headache, and no loss of consciousness.

Examination and course in hospital: The initial exam revealed a blood pressure of 125/85 and a heart rate of 82 bpm. He was alert and oriented. Cranial nerve exam demonstrated anisocoria—right*3 (react), left*2 (react). On left lateral gaze he was able to direct his eyes past mid-line. There was loss of pinprick appreciation in all three divisions of the trigeminal nerve on the right. There was right sided facial weakness. His speech was dysarthric, and there was left sided deviation of the tongue on protrusion. There was severe weakness of the right arm

and mild weakness of the right leg. Hyper-reflexia and an ongoing plantar response was present on the right. Somatic sensory exam revealed hypalgesia of the right arm and leg.

The patient's platelets and clotting times were normal. A CT scan of the head demonstrated a high density area within the pons and mid-brain, greater on the left than on the right. An erosive lesion involving the superolateral aspect of the clivus, with bone expansion was present (Figures 1a, b). There was no enhancement following contrast. Selective 4-vessel cerebral angiography was normal. One week after admission a T1- and T2-weighted magnetic resonance image showed an intra-tumoral hemorrhage into an exophytic lesion arising from the left side of the clivus and invaginating the left pons and mid-brain. The clivus was expanded and the normal fat containing marrow was replaced by tumor (Figures 2a, b).

One day following admission the patient deteriorated, with vomiting, increasing right hemiparesis, and periods of apnea. The patient refused aggressive management including mechanical ventilation; but he was started on intravenous Dexamethasone 4 mg every 6 hours, and he improved rapidly.

Three weeks post admission the patient had improved to the point where he was ambulatory, with residual right arm drift, and moderate right sided spasticity. Two days later he had a left sub-occipital craniotomy. Using a pial incision through the anterolateral pons between the level of the Vth and VIIth cranial nerves, a modest internal decompression of tumor and clot from the brainstem was achieved. Attempts to get anterior to the pons were foiled as tumor and brain stem were adherent. The patient had an uneventful recovery, with no aggravation of preoperative neurological deficits.

From the Division of Neurosurgery/Neuropathology, Mississauga Hospital, Department of Neuroradiology, The Toronto Hospital, University of Toronto, Toronto

Received April 3, 1991. Accepted May 1, 1991

Reprint requests to: Hart Schutz, M.D., Division of Neurosurgery, Mississauga Hospital, 100 Queensway West, Mississauga, Ontario, Canada, L5B 1B8

Pathological Examination: Microscopic sections revealed a lobulated tumor with typical physaliferous cells forming small whorls. There was recent (Figure 3a) and remote hemorrhage. The latter was characterized by hemosiderin deposition and by foamy macrophages and cholesterol clefts. Although the chordoma and brain stem were not juxtaposed in sections, the tumor, organizing hematoma, and brain stem parenchyma, with gliosis and Rosenthal fibers, were in continuity (Figure 3b).

DISCUSSION

Chordomas are rare, slowly growing tumors, that arise from notochordal remnants in close relation to the axial skeleton. Approximately 50% of chordomas are sacrococcygeal, 35% are intra-cranial, and 15% are vertebral.² Although clival chordomas grow slowly and metastasize infrequently, their malignant potential is a result of their critical location near the brain stem, the extremely high recurrence rate, and their relative insensitivity to radiation therapy.³ The average survival of patients harboring these tumors being 4-5 years with therapy.²

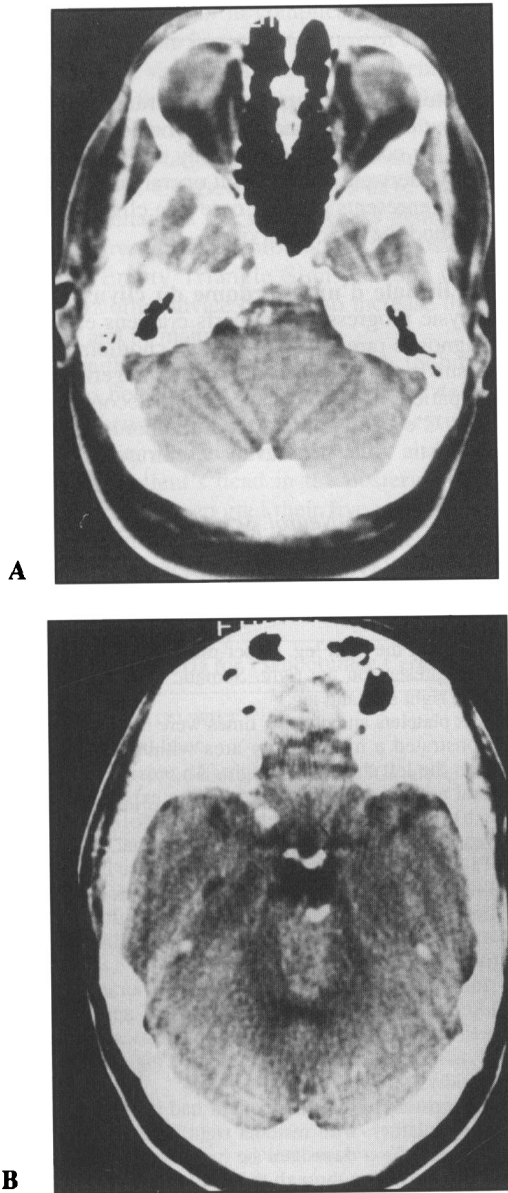


Figure 1 — Unenhanced computerized tomography of the head. (A) Axial section through the pontomedullary junction. There is a lesion in the cistern anterior to the brain stem and within the dorsal half of the clivus. The dorsal surface of the clivus is destroyed and there are some calcifications on the right side of the lesion. (B) Axial section through the pons. There is a well defined ovoid hyperdense lesion in the central portion of the pons extending to the left. The lesion appears intra-axial.

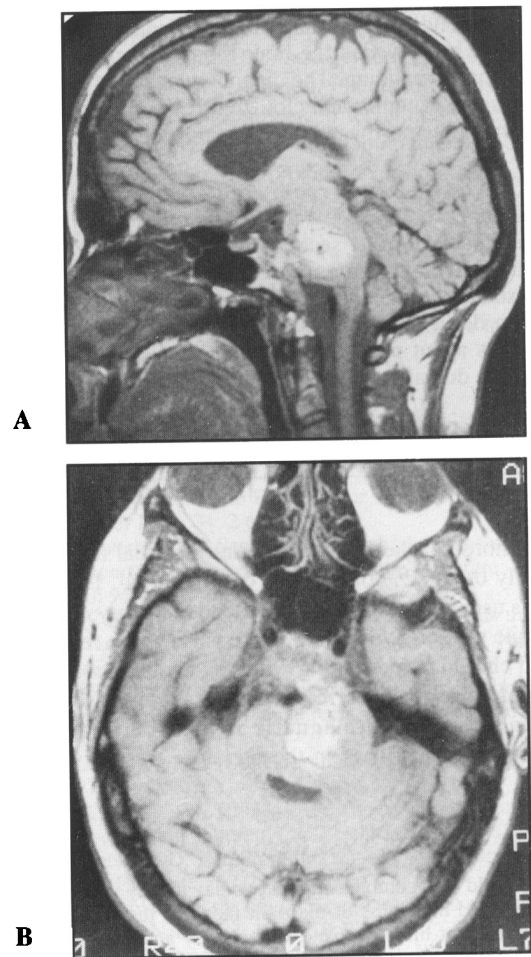


Figure 2 — T1-Weighted MRI (SE 600/20). (A) Sagittal image 5 mm to the left of midline. The normal marrow fat of the clivus has been replaced by tumor extending from the anterior lip of the foramen magnum to almost the sellar floor. A large exophytic portion of the tumor extends through the prepontine cistern into the substance of the pons. The entire brain stem is displaced dorsally. The hyperintensity of the T1-weighted MRI together with the hyperdensity on unenhanced CT indicates the presence of hemorrhage in the pontine component of the tumor. (B) Axial image through the pons. The intra-clival, intracisternal and intra-axial components of the tumor are all demonstrated on this image. There appears to be a plane separating the tumor from the brain stem (arrows).

Typically patients with clival chordomas present in their 4th decade of life, with a history ranging from months to years.⁴ An acute or sub-acute presentation is extremely uncommon. The most frequent complaint is diplopia and headache.^{2,4} However any of the cranial nerves II-XII, the pyramidal, or cerebellar pathways may be involved.

The advent of magnetic resonance imaging (MRI) has proven highly sensitive for the detection of clival chordomas. The multiplanar capability, its excellent soft tissue contrast, and its ability to clearly demonstrate the relationship between tumor and adjacent vital structures⁵⁻⁷ has improved the diagnostic accuracy and treatment planning for these tumors. Chordomas generally appear hypo- to isointense on T1-weighted images, and demonstrate moderate to extremely high signal intensity on T2-weighted images.⁷ Intra-tumoral hemorrhage has not been reported in any of the recent reviews dealing with MRI of chordomas.⁵⁻⁷ Computed tomography (CT), however remains superior in defining the exact nature of calcification, and extent of bone destruction caused by tumor.^{5,6}

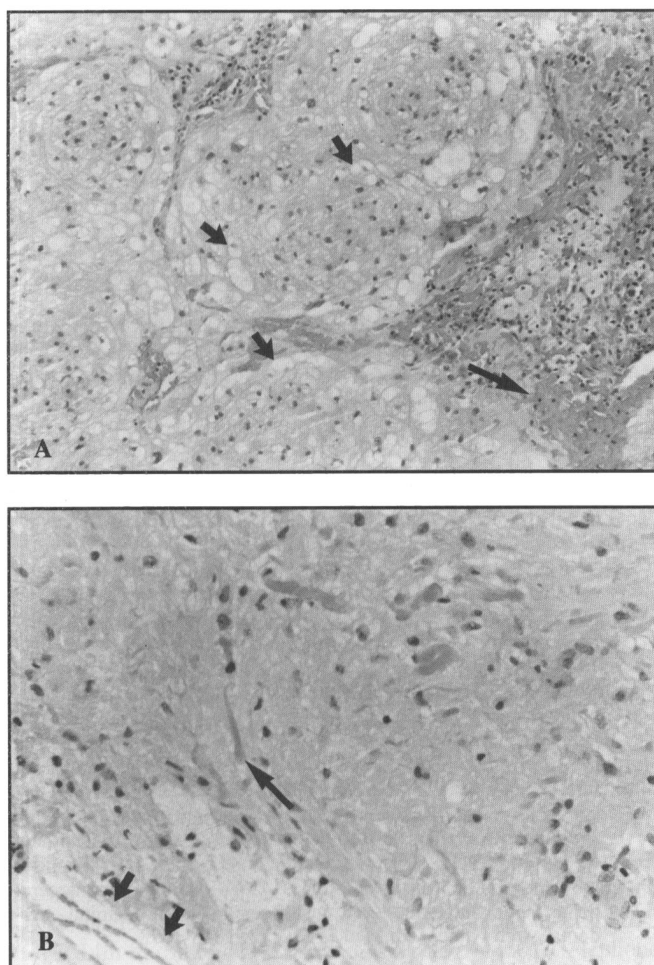


Figure 3 — Photomicrographs of the tumor. H & E. (A) Whorls of physaliferous chordoma cells with focus of recent hemorrhage (large arrows) and foamy macrophages (small arrows). x 250. (B) In continuity with Figure 3a tissue, brainstem with Rosenthal fibers (large arrow), and foamy macrophages and cholesterol clefts (small arrows). x 250.

On gross examination these tumors are gelatinous, grayish, lobulated, and pseudo-encapsulated.² In advanced cases, the tumor is no longer well defined, often penetrating the dura, and destroying surrounding bony tissue.⁸ Microscopically, fibrous strands divide the chordomas into lobules, which contain abundant mucin-containing tumor cells.⁹ The characteristic physaliferous cells with their large intra-cytoplasmic vacuoles are seen but are rarely the dominating cell. Several tumors contain a significant chondroid component, with stroma resembling hyaline cartilage containing neoplastic cells in lacunae.² These chordoma sub-types have a better prognosis.

The age of the patient and the location of the hemorrhage are important determinants in identifying the etiology of spontaneous intra-cranial bleeding. Although hypertension is frequently deemed as the cause of intra-cerebral hemorrhage, vascular malformations, aneurysms, blood dyscrasias, and brain tumors are important treatable causes which need to be identified.¹⁰ Intra-cranial hemorrhage has been reported in brain tumors in 0.9 - 11% of cases.¹⁰⁻¹⁴ Most cases of tumor associated hemorrhages occur in patients with previously diagnosed neoplasms.¹⁴ However an important sub-set of patients, such as ours, present with an apoplectic syndrome secondary to intra-tumoral bleeding as their initial symptom.

Pathologic studies reveal an overall tumor hemorrhage rate of 14.6% (macroscopic 5.4%, microscopic 9.2%).¹⁵ Certain tumor types are predisposed to hemorrhage. Pituitary adenomas have a significantly higher hemorrhage rate (15.8%) when compared to other brain tumors.¹⁴ Excluding sellar tumors, mixed oligodendroglioma/astrocytoma was found to have the highest intra-tumoral hemorrhage rate.¹⁵

Two of the most recent reviews^{14,15} which examined the question of intra-tumoral hemorrhage rate related to tumor histology found no instances of hemorrhage within chordomas from a combined total of 11 cases. In contrast, Gardner and Turner's¹⁶ clinical and pathologic study of cranial chordomas from the early 40's, detected areas of microscopic interstitial hemorrhage in two of three surgical cases. Combining the above data with the aforementioned radiologic reviews, massive hemorrhage within chordomas must be considered uncommon. Given the extremely low incidence of hemorrhage in meningiomas^{14,17} and acoustic neurinomas;^{14,18,19} extra-axial tumors presenting as an intra-axial hemorrhage are exceptional. In the present case, only through the excellent soft tissue resolution of MRI, where hemorrhagic tumor could be seen invaginating the brain stem, could the correct pathogenetic mechanism be identified.

As patients with cranial chordomas typically present with a several month history of headache and progressive cranial nerve palsies, it is not surprising that review of the world literature reveals only five previous cases to present clinically as intra-cranial hemorrhage (Table 1).^{8,26-29} None of these cases had a correct ante-mortem diagnosis established.

Numerous mechanisms have been proposed to explain the etiology of intra-tumoral hemorrhage,^{15,20,21} and intra-cranial hemorrhage in connection with brain tumors.^{14,22-25} In four of the above six cases of intra-cranial hemorrhage associated with chordomas, an intra-axial component was present. In the abstract of case 4, no mechanism was elucidated upon. In case 3, Stam and Kamphorst demonstrated at autopsy intra-tumoral hemorrhage with dissection of clot into the pons.²⁷ In case 5,

Table 1: Summary of 6 reported cases of clival chordoma presenting as intracranial hemorrhage

Case No.	Author & Year	Age (yrs), Sex	Location of Hemorrhage	Outcome
1	Simonsen, 1963	38, F	SAH/IVH	death
2	Bartolini, 1974	57, M	SAH	death
3	Stam & Kamphorst, 1982	75, M	SAH/pons	death
4	Koga et al., 1988	38, F	cerebellar	death
5	Franquemont et al., 1989	49, F	SAH/pons/cerebellum	death
6	Levi et al., 1991	29, M	pons	alive + neuro def

SAH = sub-arachnoid hemorrhage, IVH = intraventricular hemorrhage

Franquemont et al. report a case of chordoma compressing the paramedian pontine vessels with subsequent hemorrhagic infarction of the pons and the cerebellum.²⁹

In our case (case 6), frank invasion of the brain stem by the slowly growing tumor had occurred with little to no symptoms initially, only to present with rapid progression of neurological deficits after intra-tumoral hemorrhage. Pathologic study of these tumors,¹⁶ often reveals tissue which is poorly vascularized, with small, thin walled vessels confined to the stroma. Rupture of these thin walled vessels or hemorrhagic infarction due to rapid tumor growth outstripping its blood supply may have been the mechanism of intra-tumoral hemorrhage in this case.

In contrast to the uniformly fatal outcome of the other patients with clival chordomas who presented with neurological deterioration from tumoral hemorrhage, this patient survived. This may be partially attributed to the patient's young age, the administration of steroids, and that the hemorrhage was fairly well contained within the tumor and did not dissect into the white matter tracts of the brain stem.

REFERENCES

- Laws ER. Cranial chordomas. In: Wilkins RH, Rengachary SS, eds. *Neurosurgery*. Vol. 1, Edition 1. New York: McGraw Hill, 1985: 927-930.
- Hefflinger MJ, Dahlin DC, MacCarty CS, et al. Chordomas and cartilaginous tumors at the skull base. *Cancer* 1973; 32: 410-420.
- Sen CN, Sekhar LN, Schramm VL, et al. Chordoma and chondrosarcoma of the cranial base; an 8 year experience. *Neurosurgery* 1989; 25: 931-941.
- Rich TA, Schiller A, Suit HD, et al. Clinical and Pathologic review of 48 cases of chordoma. *Cancer* 1985; 56: 182-187.
- Larson TC, Houser W, Laws ER. Imaging of cranial chordomas. *Mayo Clin Proc* 1987; 62: 886-893.
- Oot RF, Melville GE, New PF, et al. The role of MR and CT in evaluating clival chordomas and chondrosarcomas. *AJR* 1988; 151: 567-575.
- Sze G, Uichanco LS, Brant-Zawadski MN, et al. Chordomas: MR Imaging. *Radiology* 1988; 166: 187-191.
- Simonsen J. Fatal subarachnoid hemorrhage originating in an intracranial chordoma. *Acta Pathol Microbiol Scand* 1963; 59: 13-20.
- Eriksson B, Gunterburg B, Kindblom L. Chordoma: A clinicopathologic and prognostic study of a Swedish national series. *Acta Orthop Scand* 1981; 52: 49-58.
- McCormick WF, Rosenfield DB. Massive brain hemorrhage: A review of 144 cases and an examination of their cause. *Stroke* 1973; 4: 946-954.
- Luessenhop AJ, Shevlin WA, Ferrero AA, et al. Surgical management of primary intracerebral hemorrhage. *J Neurosurg* 1967; 27: 419-427.
- Mutlu N, Berry RG, Alpers BJ. Massive cerebral hemorrhage: Clinical and pathological correlations. *Arch Neurol* 1963; 9: 644-661.
- Russell DS. The pathology of spontaneous intracranial hemorrhage. *J Roy Soc Med* 1954; 47: 689-693.
- Wakai S, Yamakawa K, Manaka S, et al. Spontaneous intracranial hemorrhage caused by brain tumor: its incidence and clinical significance. *Neurosurgery* 1982; 10: 437-444.
- Kondziolka D, Bernstein M, Resch L, et al. Significance of hemorrhage into brain tumors: Clinicopathologic study. *J Neurosurg* 1988; 67: 852-857.
- Gardner WJ, Turner O. Cranial Chordomas. A clinical and pathologic study. *Arch Surg* 1941; 42: 411-425.
- Lazaro RP, Messer HD, Brinker RA. Intracranial hemorrhage associated with meningioma. *Neurosurgery* 1981; 8: 96-101.
- Gleeson RK, Butzer JF, Grin OD, Jr. Acoustic neurinoma presenting as sub-arachnoid hemorrhage: Case report. *J Neurosurg* 1978; 49: 602-604.
- McCoyd K, Barron KD, Cassidy RJ. Acoustic neurinoma presenting as sub-arachnoid hemorrhage. *J Neurosurg* 1974; 41: 391-393.
- Hirano A, Matsui T. Vascular structures in brain tumors. *Hum Pathol* 1975; 6: 611-621.
- Weller RO, Foy M, Cox S. The development and ultrastructure of the microvasculature in malignant gliomas. *Neuropath Appl Neurobiol* 1977; 3: 307-322.
- Andrews BT, Raffel C, Rosegay H. Subarachnoid hemorrhage from a peripheral intracranial aneurysm associated with a malignant glioma: report of a case. *Neurosurgery* 1985; 17: 645-649.
- Hart MN, Byer JA. Rupture of middle cerebral artery branches by invasive astrocytoma. *Neurology* 1974; 24: 1171-1174.
- Memon MY, Neal A, Inami R, et al. Low grade glioma presenting as subarachnoid hemorrhage. *Neurosurg* 1984; 14: 574-577.
- Poon TP, Solis OG. Sudden death due to massive intraventricular hemorrhage into an unsuspected ependymoma. *Surg Neurol* 1985; 24: 63-66.
- Bartolini G. Il cordoma del clivus quale causa di emorragia cerebrale: discussione anatomica-clinica su di osservazione autptica. *Boll Soc It Biol Sper* 1974; 50: 912-918.
- Stam FC, Kamphorst W. Echordosis physaliphora as a cause of fatal pontine hemorrhage. *Eur Neurol* 1982; 21: 90-93.
- Koga N, Kadota Y, Hatashita Y, et al. A case of clivus chordoma showing hemorrhage in the posterior fossa (Jpn). *No Shinkei Geka—Neurological Surgery* 1988; 16: 417-421.
- Franquemont DW, Katsetos CD, Ross GW. Fatal acute pontocerebellar hemorrhage due to an unsuspected sphenoccipital chordoma. *Arch Pathol Lab Med* 1989; 113: 1075-1078.