

## DOUBLE TRISOMY AS A MOSAIC

### Case History (48,XYY,+21/47,XY,+21) and Survey of the Literature of Mixed Autosomal-Gonosomal Trisomies

G. SCHWANITZ, M. HAGNER

Department of Human Genetics and Anthropology, University of Erlangen; and City Pediatric Hospital, Regensburg, GFR.

---

*The case of a boy is reported showing the typical symptoms of Down's syndrome, in whom the chromosome analysis revealed a mosaic karyotype: 50% 48,XYY,+21/50% 47,XY,+21. Findings of 92 cases from the literature are summarized to show the frequencies of double gonosome-autosome aneuploidies compared with single trisomies. Referring to the different chromosomes involved, the aneuploid cell formation, the frequencies of combinations, as well as the tendency to mosaic formation are analyzed. The age of parents at the time of birth and the life expectancy are described as well as the clinical symptoms. Theories concerning the origin of double aneuploidies are discussed.*

---

The cytogenetic investigation of a mongoloid infant showed at chromosome analysis a mosaic of the sex chromosomes XY and XYY, as well as trisomy 21 throughout.

#### CASE HISTORY

Alois A., born 25.9.1974.

Mother 29 years, father 35 years at birth of the child. Three elder, healthy siblings, no miscarriages or still-births. Birth was one week earlier than the expected date, birth weight 3620 g, length 52 cm, head circumference 34.5 cm.

#### *Clinical findings*

The child presents the typical symptoms of Down's syndrome (Fig. 1) and clinical signs of heart disease. Because of weakness of the sucking and drinking reflexes, the child had to be fed by tube until his eighth month.

#### *Developmental anamnesis*

At the age of 6 months, the child shows a developmental age of 1½ months, whereby the motor coordination, grip and perception show better development than general body control. The social reactions are especially retarded, there is hardly any contact with the environment, and the baby utters no sounds. EQ lies at about 0.3.

Dedicated to Professor Dr. G. Koch in honor of his 65th birthday (7.2.1978)

CODEN: AGMGAK 27 67 (1978) — ISSN: 0001-5660  
*Acta Genet. Med. Gemellol.*, 27: 67-74

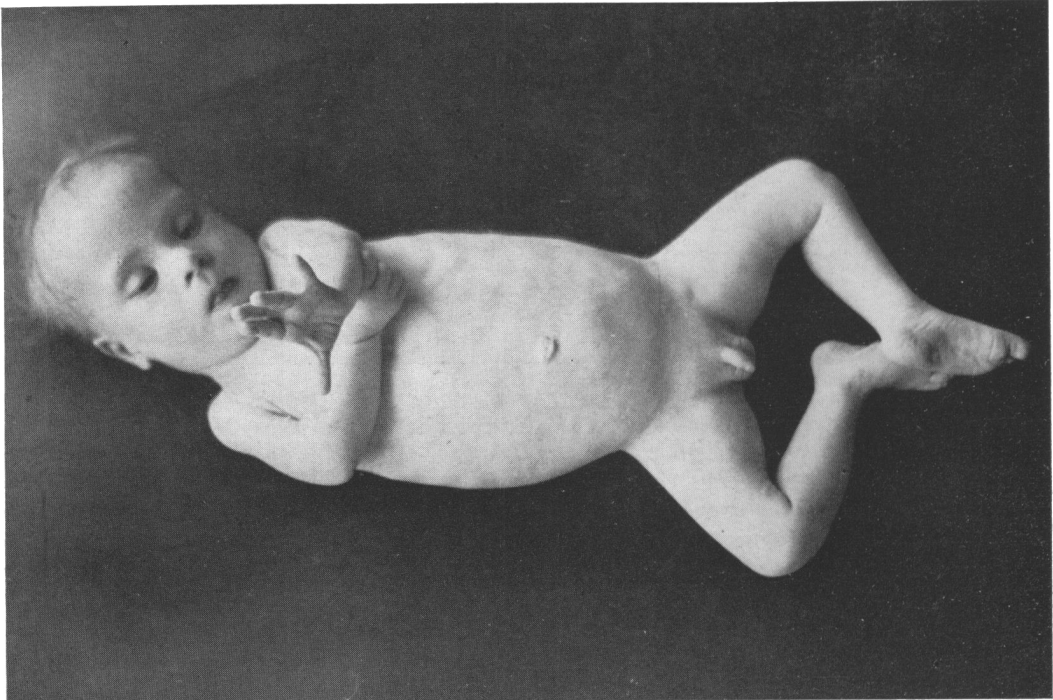


Fig. 1. Alois A., 6 months.

#### *Cytogenetic findings*

At chromosome analysis of the lymphocyte cultures, 50% of the mitoses showed a karyotype 47,XY,+21, and 50% the karyotype 48,XYY,+21 (Fig. 2).

Sixty-eight per cent cells from buccal smears and lymphocytes showed F-bodies, 10% showing 2 F-bodies per cell (Fig. 3).

#### *Dermatoglyphics*

The dermatoglyphics show the characteristic changes for Down's syndrome as well as extreme dysplasia of the palms and soles. The D.S. score according to Beckman totals 17 and therefore lies within the range of male mongoloids with proven trisomy 21 ( $14.77 \pm 0.53$ ).

### DISCUSSION

#### 1. *Frequencies of double gonosome-autosome aneuploidies in the group of autosome trisomies*

##### (a) Own Investigations

At the Erlangen Institute for Human Genetics, 630 patients have been examined in whom an autosomal trisomy could be proven: 568 showed a free trisomy 21, 45 a trisomy 18, 16 a trisomy 13, and 1 a trisomy 8.

During the same period, 3 children were observed with double aneuploidy. Two of them

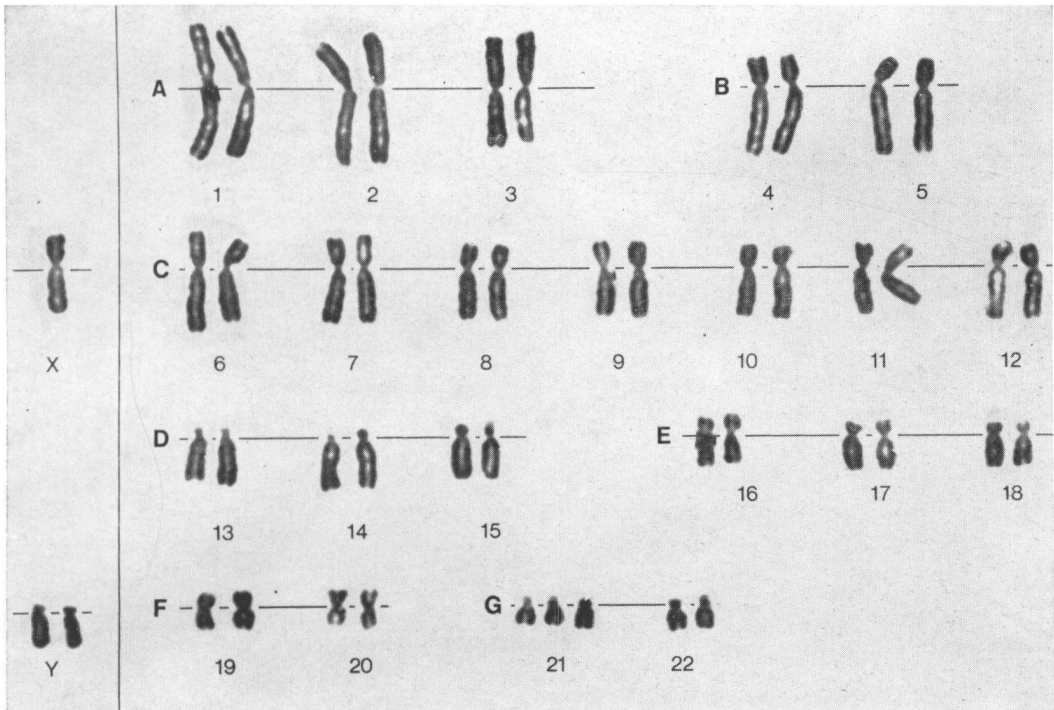


Fig. 2. Karyotype of the patient Alois A.: 48,XYY,+21.

presented a combined autosomal-gonosomal aneuploidy; the above-mentioned patient and a girl with Turner/trisomy 21 mosaic. The third one had a double autosomal aneuploidy, having additional chromosomes 18 and 21.

The frequency of double aneuploidy in the sum of our patients with trisomy 21 therefore lies at about 0.5%.

#### (b) Literature

Hamerton found 2 cases of double aneuploidy in 133 mongoloid children, Pfeiffer 1 in 68. The theoretical frequency of double aneuploidies is taken as a product of the frequencies of single aneuploidy. For the example, combination of Klinefelter's syndrome and mongolisms, this would mean a theoretical frequency of 1 : 300,000 male births.

Summaries of screening examinations of male births including more than 20,000 children show, however, an actual frequency of 1 : 11,500. This combination of double aneuploidy is therefore observed 30 times more often than would be theoretically expected.

On the whole, we found 93 cases of double autosomal-gonosomal aneuploidy in the literature.

#### 2. Combinations of double aneuploidies and their distribution

By far the greatest proportion of the above-mentioned number of cases (68 cases) appear as a combination of trisomy 21 with various types of gonosomal aneuploidy, in 18 cases gonosome abnormalities were combined with trisomy 18, and in 7 with trisomy 13.

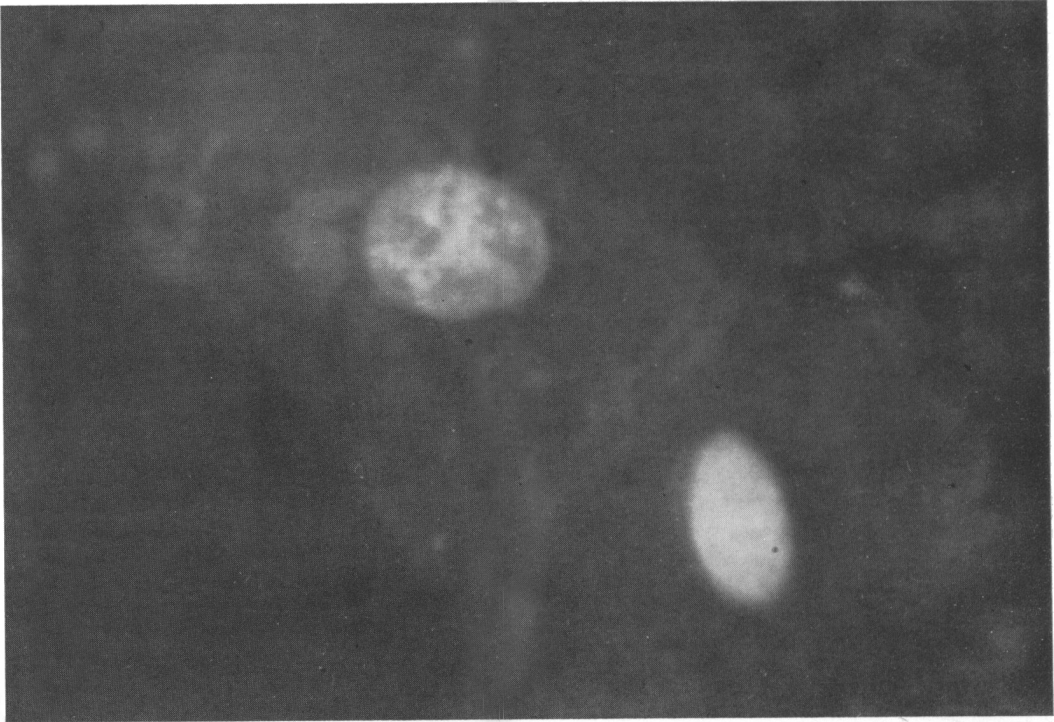


Fig. 3. Lymphocytes of the patient with 1 and 2 F-bodies.

Most frequently combined with trisomy 21 is the Klinefelter's syndrome, followed by the combination with XYY and XO at about equal frequency, while XXX is seldom found (Table). For combinations of trisomy 18 with gonosome aneuploidy, cases involving the Y chromosome are rarely seen. This may be possibly traced back to the known discrepancy between the sexes in the occurrence of trisomy 18.

Trisomy 13 is found only in combination with XXY and XO.

If the various types of gonosomal aneuploidy are compared, the extreme variation in the inclination to form mosaics is striking: in 41 combinations with XXY, 16 combinations with XYY, and 12 XXX combinations, only 5 cases of mosaics were observed, while from 24 XO combinations 23 were shown to be mosaics.

### 3. Age of parents

The average maternal age for trisomy 21 according to Smith and Berg (1976) stands at 34.43 years. For the above patients ( $N = 66$ ) the average maternal age was 32.0 years and therefore slightly lower than expected. This difference is above all due to the lower maternal age of the mosaic patients: in the mosaics an average of 29.6 years ( $N = 19$ ) was calculated, while for penetrant double aneuploidies 32.9 years ( $N = 47$ ) were shown.

So, there is a direct connection of maternal age referred to penetrant double aneuploidies and to mosaics. It is possible that different aetiological factors play a role in the origin of double aneuploidy.

Table. Frequency of the different double aneuploidy forms.

Chromosome results	Total number of cases*	Share of mosaics
Trisomy 21 + XXY	29	0
+ XYY	16	1
+ XXX	5	1
+ XO	18	17
Trisomy 18 + XXY	9	1
+ XXX	7	1
+ XO	2	2
Trisomy 13 + XXY	3	1
+ XO	4	4
	93	

\* Including all cases from the literature (cf. References) and the present one.

The low maternal age of 27.4 years (N = 11) for the 48,XYY,+21 group of penetrant double aneuploidy cases was particularly striking, as it lies almost within the normal range (average maternal age for the general population of the FRG 27.02 years). Therefore the paternal age for this group was also considered, if possible. In as far as a count of 7 cases may allow any sort of assertion, it shows an increase over the general population (average age 30.5 years) with an average of 31.9 years.

#### 4. Life expectancy

The average life expectancy of the children with aneuploidy combinations with chromosomes 13 or 18 was, as expected, extremely low (26 days, N = 16), while for the patients with combinations with trisomy 21 no obvious difference was noted from those with trisomy 21 only, nor was any expected.

#### 5. Clinical symptoms

The clinical picture of the patients was to a large extent determined by the autosomal disturbance; with a higher portion of XO-cells, however, the symptoms of Turner syndrome were apparent.

In most of the mongoloids with Klinefelter's syndrome a hypogonadism was observed. However, this is also found in mongoloids with trisomy 21 only. In any case, in various patients an increased gonadotropin value was found as well as female body proportions, gynecomastia, and testicular changes, all characteristic of Klinefelter's syndrome. These symptoms must therefore be due to the gonosomal disturbance.

In the combinations with XXX and XYY, apparently no additional clinical symptoms were observed.

#### 6. Familiar findings

No familial tendency to chromosomal abnormalities was found in any of the patients. Three cases were twin pregnancies, and in 1 case we found an increased familial risk of miscarriage.

### 7. Cytogenetic investigations

The chromosome analyses were made on lymphocyte cultures in about half of the cases. In addition, skin, fascia, and bone marrow were investigated. For the mosaic cases, several tissues were usually analyzed, whereby a variable distribution of the cell lines in the different tissues was sometimes found. In half of the cases the sex chromatin was also determined. The results agreed in all cases with the results of the chromosome analyses.

### 8. Theories as to the origin of double aneuploidies

*Penetrant double aneuploidy* can arise from a fusion of a gamete with 25 chromosomes with another having 23 chromosomes, or from a fusion of 2 gametes with 24 chromosomes. A further possible origin is a post-zygotic nondisjunction with subsequent loss of the hypoploid cell line.

The most probable explanation for the origin of a *mosaic* is, in most cases, a post-zygotic loss of chromosomes. This theory is particularly supported by the fact that there occur almost exclusively mosaics of the XO/autosome combination, since with monosomic X it is not very probable that the disturbance occurs at gametogenesis; rather at zygotic mitosis.

## LITERATURE

- Abrisqueta T.A. 1966. Chromosome study of different phenotypical deviations. *Hum. Chrom. Newsl.*, 18: 4.
- Al-Aish M.S., Dodson W.E., Plato Ch. C. 1971. Down's syndrome with XYY: 48,XYY,G+. *Amer. J. Dis. Child.*, 121: 444-446.
- Bach Ch., Toubanc J.E., Gautier M. 1973. Une observation de double aneuploïdie chromosomique: Trisomie 18 et XXY. *Ann. Genet.*, 16: 61-66.
- Baguena Candela R., Forteza Bover G., Amat Aguirre E. 1965. Un nuevo tipo de aberración cromosómica: el mosaico normal/trisomia G-monosomia XO. *Med. Española*, 54: 256.
- Baguena Candela R., Forteza Bover G., Ortiz Hernandez M.D., Comin Ferrer J. 1966. Un caso con estigmas del síndrome de Bonnevie-Ullrich y de mongolismo y cariotipo 45/XO-trisomia G. *Med. Española*, 55: 454-461.
- Barakat B.Y., Der Kaloustian V.M. 1973. Combined autosomal — sex chromosomal mosaicism in a newborn female with mongolism. (4th Int. Conf. Birth Def., Vienna). *Excerpta Medica*, Amsterdam, 297.
- Borgaonkar D.S. and others 1969. Pers. comm. in Laxova R. et al. 1971.
- Cohen M.M., Bumbalo T.S. 1967. Double aneuploidy. Trisomy 18 and Klinefelter's syndrome. *Amer. J. Dis. Child.*, 113: 483-486.
- Cohen M.M., Davidson R.G. 1972. Double aneuploidy (47,XX,21+/45,X) arising through simultaneous double non-disjunction. *J. Med. Genet.*, 9: 242-244.
- Court Brown W.M., Harnden D.G., Jacobs P.A., Maclean N., Mantle D.J. 1964. *Med. Res. Council. Spec. Rep.*, 305: 1-239.
- Day R.W., Wright S.W., Koons A., Quigley M. 1963. XXX 21-trisomy and retinoblastoma. *Lancet*, II: 154-155.
- Dekaban A. 1965. Twins, probably monozygotic: one mongoloid with 48 chromosomes, the other normal. *Cytogenet.*, 4: 227-239.
- Dhadial R.K. 1970. New human double trisomy or tetrasomy. *J. Med. Genet.*, 7: 75-76.
- Dhom G. 1960. Über Gonadendysgenese beim Neugeborenen und jungen Säugling mit chromatinnegativem Kernbefund. *Acta endocrin.*, 34: 105.
- Duillo M.T., Serra G. 1969. Trisomia 21 associata a mosaicismo gonosomico. *Min. Pediat.*, 21: 2196-2201.
- Ebbin A.J., Chu Lim R., Towner J.W., Wilson M.G. 1972. A double aneuploid mosaic: Trisomy 13 and XXY. *J. Med. Genet.*, 9: 365-367.
- Edgren J., de la Chapelle A., Kääriäinen R. 1966. Cytogenetic study of seventy-three patients with Down's syndrome. *J. ment. Defic. Res.*, 10: 47-62.
- Efinski D., Duma H., Apostolovski B., Sofijanov N., Risteovski B., Darkovski S. 1974. Klinefelter's and Down's syndrome in an adolescent with abnormal EEG. *Clin. Genet.*, 5: 81-85.
- Engel E., Haddow J.E., Lewis J.F., Tipton R.E., Overall J.C., McGee B.J., Levrat O.J., Engelde-Montmollin M. 1967. Three unusual patterns in children. *Amer. J. Dis. Child.*, 113: 322-328.
- Erdtmann B., Gomes De Freitas A.A., De Souza R.P., Salzano F.M. 1971. Klinefelter's syndrome and G trisomy. *J. Med. Genet.*, 8: 364-368.

- Feiertag-Koppen C.C.M., Anders G.J.P.A., Stronk M.G., Boevé H.J. 1966. Mosaicism of X and G chromosomes. *Lancet*, I: 1271.
- Ford C.E., Jones K.W., Miller O.J., Mittwoch U., Penrose L.S., Ridler M., Shapiro A. 1959. The chromosomes in a patient showing both mongolism and Klinefelter syndrome. *Lancet*, I: 709-710.
- France N.E., Evison P.G.H., Butler L.J., Snodgrass G.J.A.I., Crome L., Keith C.G. 1967. Trisomy D<sub>1</sub> (13-15) associated with XO/XY mosaicism. *J. Med. Genet.*, 4: 134-138.
- Grosse K.-P., Hopfengärtner F., Schwanitz G. 1971. Doppelte Aneuploidie: 46,XX/45,XO/47,XX,G+. *Humangenetik*, 13: 333-337.
- Grouchy J. de, Emerit I., Gennes J.-L. de, Vernant P. 1965. Syndrome de Klinefelter chez un garçon trisomique 21 âgé de six ans. *Presse méd.*, 73: 1209-1212.
- Gustavson K.-H., Ivemark B.I., Zetterquist P., Böök J.A. 1962. Postmortem diagnosis of a new double-trisomy associated with cardiovascular and other anomalies. *Acta paediat.*, 51: 686-697.
- Haas L., Lewis F.J.W. 1966. Double trisomy: trisomy 17-18 with triple X in a female infant. *J. Pediat.*, 69: 660-662.
- Hall B. 1963. Two cases, pers. comm. in Laxova R. et al. 1971.
- Hall B. 1964. Mongolism in newborns. A clinical and cytogenetic study. *Acta paediat. Suppl.* 154.
- Hamerton J.L., Jagiello G.M., Kirman B.H. 1962. Sex-chromosome abnormalities in a population of mentally defective children. *Brit. med. J.*, I: 220-223.
- Hamerton J.L., Giannelli F., Polani P.E. 1965. Cytogenetics of Down's syndrome (mongolism) I. Data on a consecutive series of patients referred for genetic counselling and diagnosis. *Cytogenet.*, 4: 171-185.
- Harnden D.G., Miller O.J., Penrose L.S. 1960. The Klinefelter-mongolism type of double aneuploidy. *Ann. Hum. Genet.*, 24: 165-169.
- Haylock J., Dennett X., Fitzgerald M. 1963. Two cases of the 18 trisomy syndrome, one in combination with an XXY karyotype. *Hum. Chrom. Newsl.*, 9: 15.
- Hecht F., Nievaard J.E., Duncanson N., Miller J.R., Higgins J.V., Kimberling W.J., Walker F.A., Smith G.S., Thuline H.C., Tischler B. 1969. Double aneuploidy: the frequency of XXY in males with Down's syndrome. *Amer. J. hum. Genet.*, 21: 352-359.
- Hsu L.Y.F., Strauss L., Alter A.V., Kim H.J., Hirschhorn K. 1975. Prenatal diagnosis of double trisomy. *Amer. J. Dis. Child.*, 129: 381-382.
- Hustinx T.W., Eberle P., Geerts S.J., Brink J.T., Woltring L.M. 1961. Mongoloid twins with 48 chromosomes (AA+A<sub>21</sub>XXY). *Ann. Hum. Genet.*, 25: 111-115.
- Hustinx T.W.J., Ter Haar B.G.A., Scheres J.M.J.C., Rutten F.J. 1974. Autosomal/heterosomal mixoploidy: a report on two patients, a female with a 45,X/47,XX,+21 and a male with a 45,X/47,XY,+21 chromosome constitution. *Ann. Génét.*, 17: 225-234.
- Lanman J.T., Sklarin O.S., Cooper H.L., Hirschhorn K. 1960. Klinefelter's syndrome in a ten-month-old mongolian idiot: report of a case with chromosome analysis. *New Engl. J. Med.*, 263: 887-890.
- Laxova R., McKeown J.A., Saldafia P., Timothy J.A.D. 1971. A case of XYY Down's syndrome confirmed by autoradiography. *J. Med. Genet.*, 8: 215-219.
- Leary P.M., Webb P.M., Melzer C.W., Close H.G. 1975. Down's syndrome with additional XYY aneuploidy. *Clin. Genet.*, 8: 55-58.
- Lehmann O., Forssman H. 1960. Klinefelter's syndrome and mongolism in the same person. *Acta paediat.*, 49: 536-539.
- Lewis F.W.J., Haas L. 1965. Group E trisomy in a triple X female infant. *Hum. Chrom. Newsl.*, 16: 21.
- Maclean N., Mitchell J.M., Harnden D.G., Williams J., Jacobs P.A., Buckton K.A., Baikie A.G., Court Brown W.M., McBride J.A., Strong J.A., Close H.G., Jones D.C. 1962. A survey of sex-chromosome abnormalities among 4514 mental defectives. *Lancet*, I: 293-296.
- Madahar D.P., Dosik H., Wexler I. 1974. 48,XXX,+18 double trisomy. *J. Med. Genet.*, 11: 309-311.
- Mailhes J.B., Moore Ch. M., Gershanik J.J. 1977. A case of double trisomy in a liveborn infant: 48,XXY,+13. *Clin. Genet.*, 11: 147-150.
- Medenis R., Forbes A., Rosenthal I.M. 1962. Mosaicism associated with mongolism. *Abstracted Soc. Pediat. Res.*, 572.
- Migeon B.R. 1965. G<sub>1</sub> trisomy in a XYY male. *Hum. Chrom. Newsl.*, 17: 16.
- Milcou S., Maicanesco M. 1963. Syndrome de Klinefelter associé au mongolisme et à l'ectopie testiculaire bilatérale. *Path. Biol.*, 11: 1247-1250.
- Murken J.D., Lippoldmüller E., Spiess H. 1972. XYY-Syndrom und Trisomie 21 (48,XXY,21+). *Mshr. Kinderheilk.*, 120: 469-471.
- Murken J.D. et al. 1972. 48,XXY,+21. Pers. comm. in Murken J.D. et al. 1972.
- Neu R.L., Scheuer A.Q., Gardner L.I. 1971. A case of 48,XXX,21+ in an infant with Down's syndrome. *J. Med. Genet.*, 8: 533-535.
- Nielsen J., Veitner M., Holm V., Askjaer A.A., Reske-Nielsen E., Žižka J. 1978. Klinefelter's syndrome and trisomy 18 in a newborn boy. *Clin. Genet.*, 13: 259-264.
- Osztovcics M., Ivády G., Bühler E.M. 1971. XYY chromosomal complement, proven by fluorescence, in a child with trisomy 21: 48,XXY,21+. *Humangenetik*, 13: 144-150.
- Pergament E., Kadotani T. 1965. A new double aneuploid: XXY D-trisomy. *Lancet*, II: 695.
- Pfeiffer R.A. 1964. Doppelte Aneuploidie (Trisomie 21 und XXY) bei einem Säugling. *Arch. Kinderheilk.*, 171: 69-79.
- Pfeiffer R.A. 1964. Chromosome abnormalities in children with congenital malformations. *Hum. Chrom. Newsl.*, 12: 10.
- Pfeiffer R.A. 1964. Pers. comm. in Pfeiffer R.A. 1964.

- Prieur M., Dutrillaux B., Carpentier S., Berger R., Raoul O., Rethoré M.-O., Lejeune J. 1972. Mosaïque 45,X/47,XY,+21. *Ann. Génét.*, 15: 195-196.
- Prieur M., Dutrillaux B., Lafourcade J., Roy C., Lejeune J. 1976. Mosaïque 45,X/47,XY,+13, chez une fille âgée de 19 ans. *Ann. Génét.*, 19: 199-202.
- Ricci N., Borgatti L. 1963. XXX 18-trisomy. *Lancet*, II: 1276-1277.
- Root A.W., Bongiovanni A.M., Breibart S., Mellman W.J. 1964. Double aneuploidy: Trisomy 21 and XO/XX sex chromosome mosaicism. *J. Pediat.*, 65: 937-939.
- Schinzl A., Schmid W., Prader A. 1974. Turner phenotype: mosaic 45,X/47,XY,+18. *J. Mcd. Genet.*, 11: 101-104.
- Sénéze J., Lafourcade J., Lejeune J., Thoyer-Rozat J. 1964. Double aneuploïdie: trisomie-21 et syndrome de Klinefelter chez un couple de jumeaux monozygotes. *Bull. Fédér. Soc. Gyn.*, 16: 529-535.
- Sever L.E. Turner phenotype: mosaic 45,X/47,XY,+18. *Pers. comm.*
- Shapiro A., Ridler M.A.C. 1960. The incidence of Klinefelter's syndrome in a mental deficiency hospital. *J. ment. Defic. Res.*, 4: 48-50 and pers. comm. to Hamerton 1962 in Hamerton et al. 1965.
- Smith G.S., Delay M.R. 1965. Human chromosome patterns in mentally retarded individuals. *Hum. Chrom. Newsl.*, 16: 27.
- Stoll C., Frey D., Willard D., Messer J. 1976. Down's syndrome with XYY additional aneuploidy. *Hum. Genet.*, 34: 85-88.
- Taylor A.I., Moores E.C. 1967. A sex chromatin survey of newborn children in two London hospitals. *J. Med. Genet.*, 4: 258-259.
- Taylor A.I. 1968. Autosomal trisomy syndromes: A detailed study of 27 cases of Edwards' syndrome and 27 cases of Patau's syndrome. *J. Med. Genet.*, 5: 227-252.
- Taylor A.I. 1970. Further observations of cell selection in vivo in normal/G trisomic mosaics. *Nature (Lond.)*, 227: 163-164.
- Toublanc M. 1971. A propos d'une observation d'une double aneuploïdie chromosomique: trisomie 18 et XXY. Thèse, Paris.
- Townes Ph. L., White M.R., Stiffler S.J., Goh K. 1975. Double aneuploidy. *Amer. J. Dis. Child.*, 129: 1062-1065.
- Turpin R., Thoyer-Rozat J., Lafourcade J., Lejeune J., Caille B., Kessler A. 1964. Coïncidence de mongolisme et de syndrome de Klinefelter chez l'un et l'autre jumeaux d'une paire monozygote. *Pédiatrie*, 19: 43-52.
- Tsukino R., Sasaki M., Moriguchi O. 1971. A case of Turner-Down mosaicism with 45,X/46,X,G+ constitution. *Chromosome Inf. Serv.*, 12: 21-22.
- Uchida I.A., Bowman J.M. 1961. XXX 18-trisomy. *Lancet*, II: 1094.
- Uchida I.A., Lewis A.J., Bowman J.M., Wang H.C. 1962. A case of double trisomy: Trisomy No. 18 and triplo-X. *J. Pediat.*, 60: 498-502.
- Uchida I.A., Ray M., Duncan B.P. 1966. 21 trisomy with an XYY sex chromosome complement. *J. Pediat.*, 69: 295-298.
- Van Gelderen H.H., Hustinx T.W.J. 1961. Combinatie van het Klinefelter-syndroom met mongolisme. *Ned. T. Geneesk.*, 105: 1925-1928.
- Van Gelderen H.H., Gaillard J.L.J., Schaberg A. 1967. Trisomy G/normal mosaics in non-mongoloid mentally deficient children. *Acta paediat. Scand.*, 56: 517-525.
- Van Wijck J.A.M., Blankenburg G.J., Stolte L.A.M. 1964. XO/XX mosaicism and mongolism in the same person. *Lancet*, I: 171.
- Verresen H., van den Berghe H. 1965. 21-trisomy and XYY. *Lancet*, I: 609.
- Vignetti P., Ferrante E., Capotorti L. 1965. Un caso di trisomia 21 (mongolismo) associata a triplo X. *Acta Paediat. Lat. (Reggio Emilia)*, 18: 40.
- Yunis J.J., Hook E.B., Alter M. 1964. XXX 21-trisomy. *Lancet*, I: 437-438.
- Zellweger H., Abbo G. 1965. Familial mosaicism attributable to a new gene. *Lancet*, I: 455-457.
- Zellweger H., Abbo G. 1967. Double trisomy and double trisomic mosaicism. *Amer. J. Dis. Child.*, 113: 329-337.
- Zergollern L., Hoefnagel D. 1964. X-chromosome mosaicism with trisomy-21. *Lancet*, I: 1108-1109.