

Main Article

Salman Hashmi takes responsibility for the integrity of the content of the paper

Cite this article: Hashmi S, Hussain SZM, Matto O, Dewhurst S, Qayyum A. To evaluate the results of mastoid obliteration and reconstruction of posterior meatal wall after canal wall down mastoidectomy using ready-to-use, self-setting hydroxyapatite bone cement. *J Laryngol Otol* 2025;1–6. <https://doi.org/10.1017/S0022215124001737>

Received: 13 April 2024

Revised: 12 June 2024



Accepted: 27 June 2024

Keywords:

Cholesteatoma; Osseo-integrated implants; Sensorineural hearing loss; Magnetic resonance imagery; Hearing aids

Corresponding author: Salman Hashmi;
Email: salmanhashmi1404@gmail.com

To evaluate the results of mastoid obliteration and reconstruction of posterior meatal wall after canal wall down mastoidectomy using ready-to-use, self-setting hydroxyapatite bone cement

Salman Hashmi¹ , Syed Zohaib Maroof Hussain² , Owais Matto¹, Samuel Dewhurst¹ and Asad Qayyum¹

¹Peterborough City Hospital, UK and ²Leicester Royal Infirmary, UK

Abstract

Objectives. Despite a lot of scientific advancements in otology, canal wall-down mastoidectomy is still considered to be the standard of care in the management of extensive cholesteatoma. To avoid large cavity related problems, mastoid obliteration has been described in the literature for many decades. Controversy prevails among otologists regarding the materials used for obliteration. This study aimed to evaluate the results of mastoid obliteration and reconstruction of posterior meatal wall after mastoidectomy using ready-to-use, self-setting hydroxyapatite bone cement.

Methods. Retrospective analysis was performed of all consecutive patients who underwent canal wall down mastoidectomies and primary mastoid obliteration with ready-to-use, self-setting hydroxyapatite bone cement. Minimum follow-up was 1 year. Primary Outcome measures include need for explantation and post-operative complications.

Results. Total of 26 patients were included in the study. Only one patient required complete explantation. All patients acquired dry cavities in the final follow-up. Few minor complications including external auditory canal granulations and post-aural wound dehiscence. There was no cholesteatoma recidivism.

Conclusion. Ready-to-use, self-setting hydroxyapatite bone cement serves the purpose of mastoid obliteration. In addition, it is time efficient and requires less expertise. It has excellent outcomes in terms of cholesteatoma recidivism. We recommend further research in this area with a large cohort.

Introduction

Canal wall down (CWD) mastoidectomy is still considered to be standard of care in the management of extensive cholesteatoma, despite the advancement in otologic surgery. It provides the surgeon with adequate exposure and is still considered best for eradicating the disease and prevention of recurrence. Apart from surgical complications, it is also associated with some long-standing problematic sequelae. Namely, need for regular cleansing, risk of discharging cavities, repeated infections and granulation formation, caloric effects, lifestyle alterations and water precautions. Additionally, it also limits the options for hearing rehabilitation and reconstruction. Mastoid obliteration hence helps to overcome all these adverse outcomes. Additionally, obliteration of the mastoid and epitympanum also prevents the tympanic membrane from retracting because there is no space to retract¹; hence, it helps in preventing recurrence. Although described in literature from the beginning of the past century, controversy prevails among otologists regarding the materials used for obliteration. Many surgeons favour the use of autologous muscle, cartilage and bone dust. However, due to numerous limiting factors, it is not possible to get the autologous tissue on all occasions, especially in patients with extensive disease, large cavities and where patients have had multiple operations. Hence, the use of alloplastic material has come into practice.

Various merits have been narrated regarding the use of synthetic materials over autologous materials. Such as, ready-to-use, unlimited quantity, malleable, lack of disease contamination and long-term resorption.² Numerous materials have been used by surgeons in the past few decades, namely calcium phosphate cement or granules, bio-glass, silicone gel, titanium etc. Literature describes success rates of these materials comparable to the autologous

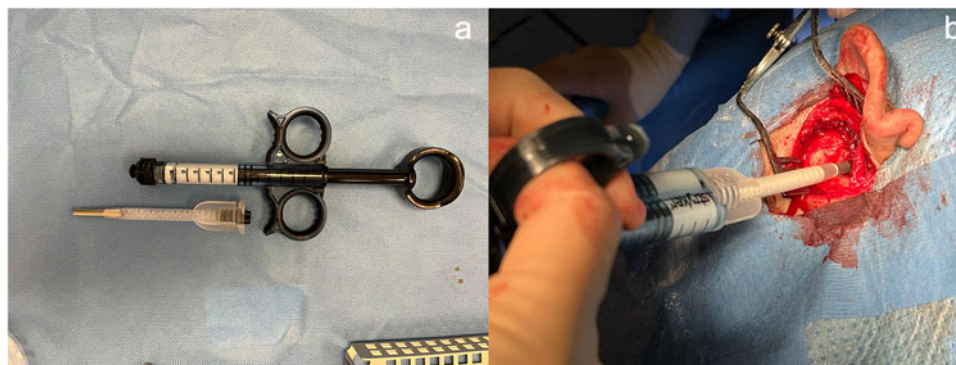


Figure 1. (a) DirectInject™ double-barrel syringe system. (b) Injecting pre-mixed HAP cement into the mastoid cavity. HAP = hydroxyapatite.

materials.³ Hydroxyapatite (HAP) is generally reported as one of the commonest artificial materials used for obliteration. Since its first successful use in mastoid obliteration reported by Yung in 1996,⁴ many authors have reported encouraging outcomes Calcium phosphate which is a naturally occurring major inorganic constituent of the bones, is generally available in two forms for clinical use, namely HAP and tricalcium phosphate. Although both are reported to have high osseointegration and osseointegration, HAP is more stable and less biodegradable. Consequently, more suitable for maintaining the reconstructed cavity.⁵ HAP is available in granules and cement forms. Overall, HAP cement form seems to be more appropriate in reconstruction of the posterior canal wall and attic because of its self-sustainability.

Nevertheless, the use of different synthetic materials has been mentioned; however, the search for the ideal material continues. Theoretically, an ideal material should have all the merits that an autologous lack. Namely, it should be ready to use, quickly adjustable and malleable to shape according to the reconstruction requirement.⁶ Therefore, we intend to present our pilot study of patients in which a novel material is used for the reconstruction of the posterior canal wall and mastoid cavity.⁷ The aim of the study is to establish the safety and effectiveness of a ready-to-use, self-setting HAP bone cement as a novel material for obliteration of mastoid cavities following CWD mastoidectomies. To our knowledge, its use has never been reported for mastoid obliteration.

Materials and methods

Patients and setting

This was a retrospective study conducted at a district general hospital in the United Kingdom. All patients who underwent CWD mastoidectomies for cholesteatoma and primary mastoid obliteration using HAP ready-to-use bone cement between 2017 and 2021 were included. This study included people of both genders, and there was no age limit. We excluded patients who had been followed up for less than one year and a different material was used for mastoid obliteration other than DirectInject (DI™). All patients were identified from the coding used for CWD mastoidectomy.

Surgical intervention

All patients subjected to the intervention had cholesteatoma, granulations or chronic discharge as the indication of the surgery.

All surgeries were performed by the senior author of this study. All patients underwent CWD mastoidectomies through the post-aural approach and primary mastoid obliteration and reconstruction of the cavity, post-canal wall and scutum were performed by filling with DI™ (Stryker, Portage, MI, USA) in the cavity and lining it medially with either a superiorly based temporalis muscle flap or a combination of inferiorly based occipitalis muscle flap and superiorly based peri-cranial flap along with the autologous cartilage. The ear was packed with Bismuth iodoform paraffin paste (BIPP) ribbon gauze which was removed in three weeks post-operation.

Implantation material

The material used for obliteration in this study is marketed as DI™ and is a calcium phosphate-based HAP bone cement. It is a non-restorable, moldable material. Additionally, it is known to be isothermic and osteoconductive. It consists of a sterile dual paste system injected from a double-barrel delivery syringe system through the mixer-cannula (Figure 1).⁸ The delivered paste has a sculpting time of 2.5 minutes and a setting time of up to 7.5 minutes maximum despite being in a wet field. Its use is generally marketed by the company known for neurosurgical burr holes etc. Furthermore, its delivery system with a cannulated syringe makes it flexible for instilling exactly in the area of need.

Outcome measures

Primary outcome: It includes product safety and biocompatibility. Product safety was determined by post-operative complications, and the failure of the biocompatibility was termed as being a need for surgical explantation.⁹

Secondary outcome: It includes cholesteatoma recidivism and functional outcomes. Cholesteatoma recidivism was defined as disease recurrence identified clinically or radiologically until the end of follow-up, which warrants surgical intervention. Functional outcomes were defined by infection control and hearing outcomes. Infection control, which was assessed 3 to 4 weeks, 3 to 6 months but before 12 months and after 12 months. Furthermore, the latest follow-up was recorded as well. All the outcome measures are summarised in Table 1.

We used the Merchant *et al.*¹⁰ scale for control of ear discharge. Grade 3 was considered as failure of infection control, shown in Table 2.

Table 1. Outcome measures of our study

| Primary | Secondary |
|------------------------------|--------------------------|
| Need for explantation | Cholesteatoma recidivism |
| Post-operative complications | Infection control |
| | Hearing outcomes |

Table 2. Merchant *et al.* scale for infection control

| Grade | Description |
|-------|-------------------------------------------------------------------------------------------------------------------------------------------------------------------------------------------------------------------------------------------------------------|
| 0 | No episode otorrhea and no pus or granulation tissue' on otologic examination |
| 1 | One episode of otorrhea of <2 week duration in a three-month period or no otorrhea but feeling of wetness in the ear |
| 2 | More than one episode of otorrhea in a three-month period or an episode of otorrhea more than two weeks or otologic examination showing localised granulation tissue/pus that was promptly cured with antibiotic drops, curettage or silver nitrate cautery |
| 3 | Constant purulent otorrhea on a daily basis, or otologic examination showing extensive granulation tissue or need for a revision procedure to control infection |

Hearing outcomes were determined by the latest pre-operative and most recent post-operative audiograms. Bone conduction thresholds average and airborne gap (ABG) were compared at 500, 1000, 2000 and 4K Hz.¹¹ ABGs were reported in four groups of 0-10, 10-20, 20-30 and more than 30.¹²

Statistical analysis

Data were collected from theatre records and clinic letters. During this study, the patients' privacy and confidentiality were maintained, and anonymised data were used for analysis. All the categorical variables were collected and analysed as proportions. The following variables were recorded and analysed: mastoidectomy type; cavity lining material (muscle, peri-cranium, cartilage); method of tympanic membrane reconstruction; findings (infection control) at 3 weeks, 3-6 months, 12 months, and latest follow-up post-operatively; surgical complications; details of any return to the theatre following obliteration.

Ethical approval was obtained for this study from the National Health Services (NHS) Health Research Authority (Ref 22/HRA/2875). This study was conducted in accordance with the tenets of the Declaration of Helsinki.

Results

A total of 26 patients were included in the study, out of which 1 was lost to follow-up. Hence, 25 patients were analysed who had completed their minimum one-year follow-up. Mean follow-up was 25.7 months (12-57 months). Out of a total of 25 eligible patients, the proportion of males was higher (20). The right side was dominant. In terms of surgical intervention, most of the cases were revision and the main surgical intervention was modified radical mastoidectomy (MRM) and subsequent reconstruction of the mastoid and post-canal wall using ready-to-use, self-setting HAP bone cement. Along with DI™, cartilage (either tragal or conchal) was used to create neo-canal wall. Additionally, for support, a muscle flap (occipitalis or temporalis) and/or peri-cranium was also used.

Granulation over the healing canal was seen during the healing phase in some patients as depicted in Table 3. However, these settled completely in 3 months with medical management with topical ear drops. No cholesteatoma recidivism was found in any of our cases. Although there was no cholesteatoma recurrence, interestingly three patients lit up on diffusion-weighted magnetic resonance imaging (DW MRI). However, subsequent second look ruled out the disease. Dry cavities and external auditory canals were obtained in all cases on the final follow-up except one. However, six patients had to undergo revision surgery for partial/total explantation to attain dry cavities as described in the study outcomes in Table 3.

Hearing outcomes are shown in Figure 2. Mean bone conduction thresholds pre- and post-surgery were 24.3 and 26.3, respectively.

Discussion

Since the time Mosher in 1911 described the mastoid obliteration,¹³ mastoid obliteration has remained a matter of debate in all regards from its indication to the material used for obliteration. However, most surgeons who advocate obliteration initially were using musculoplasty techniques for obliteration. Leonard *et al.* in 1973 was the first group to report the use of porous ceramics for obliteration.¹⁴ Among many other materials described in the literature, one of the most widely used materials in the past three decades is HAP, which is a naturally occurring major inorganic constituent of the bones. Its use has been demonstrated in both granular and cement forms with desirable results.

As described above ready-to-use, self-setting HAP bone cement is highly osseointegrative, non-biodegradable and has very good osseointegration with partial explantation in three patients where the implant was not covered laterally with muscle flap as shown in Figure 3.

The main goals of mastoid obliteration are attaining a dry self-cleaning cavity, with ideally no cholesteatoma recidivism. We assessed the outcomes in this regard by evaluating how long it took to become a dry ear and cholesteatoma recurrence. In our study, none of the cases had any cholesteatoma recidivism. Despite a few of our cases lighting up on DW-MRI, subsequent surgical exploration confirmed the absence of cholesteatoma.

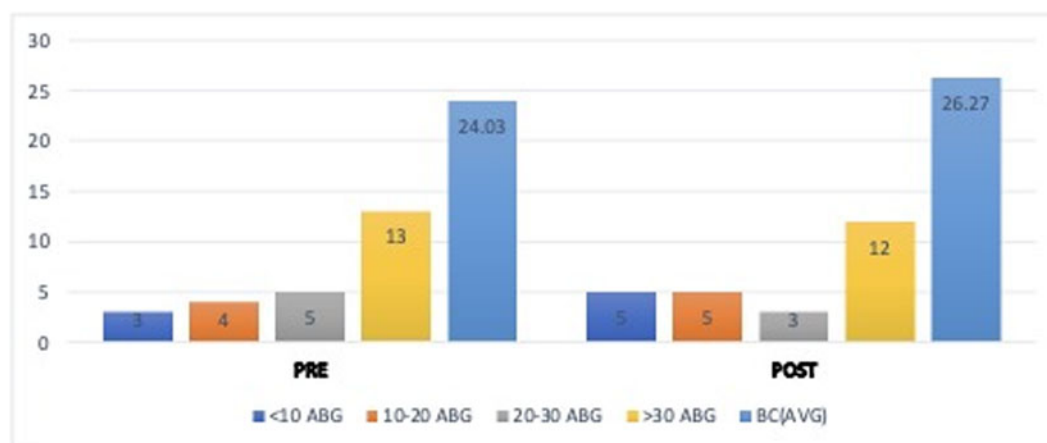
We had to explant the material in one case completely as the patient developed post-operative subcutaneous wound infection which could not be controlled with conservative measures. This individual developed polypoidal granulations over the junction of the neo-tympanum and the roof of external auditory canal (EAC). Despite medical management for a few months, we were not able to acquire dry ears and granulations could not be resolved. Hence, a revision surgery was performed to explant the material. Subsequently, a dry ear was achieved and has remained so at two years of follow-up. It is difficult to say whether we could have achieved the same results with partial explantation. As this was one of our early cases, we did explant completely; however, in subsequent cases with similar problems, we only performed a partial explant (as described in the paragraph below) and similar results were achieved.

Further, three patients were also re-explored because of non-healing post-aural scar and infection. None of these three cases had any discharge in the auditory canal. However, all cases showed good osteointegration and after partial removal, these patients

Table 3. Comparison between various implant materials

| Graft material | Total no. of patients | Follow-up (months) | Complications | Graft rejection |
|------------------------|-----------------------|--------------------|------------------------------------------------------------------------------------------------------------------------------------------------------------------------------------------------------------------------------------------------------------------------------------------------------------------------------------------------|-----------------|
| HAP cement (16) | 43 | 6–24 | Otorrhea /infection 3 (6.9%) Granulation tissue 7 (16.2%) | 9/43 (20.9%) |
| HAP granules (16, 4) | 54 | 12–60 | Otorrhea/infection 4 (7.4%) Granulations 2 (3.7%) | 1/54 (1.85%) |
| BAG (S53P4) (16) | 199 | 12–98 | Otorrhea/infection 12(6%) Granulations 2(1%) Post-op pain 1 (0.5%) | 1/199 (0.5%) |
| BAG 45S5 (16) | 60 | 6–24 | Otorrhea/ 7 (11.66%) | 2/60 (3.3%) |
| Titanium (17) | 20 | 12–36 | No complications | 0/20(0) |
| Silicone (18) | 20 | 6–90 | No complications | 1/20 (5%) |
| Our study ¹ | 25 | 12–57 | Temporary VII N weakness 1 (4%) EAC Granulations 3 (18.75%) Wound dehiscence 3 (12.5%) Superficial wound infection 01 Outcomes Need for explantation Total (01) Partial (05) Secondary outcome Cholesteatoma recidivism (0) Infection Control Merchant Grade 0/I (19) Infection Control Merchant Grade I (01) | 1/25 (4 %) |

BAG = bioactive glass; HAP = hydroxyapatite.

**Figure 2.** Hearing outcomes.

did very well with healed post-aural incisions with dry auditory canals and shallow self-cleansing cavities. All these patients have infections in the subcutaneous plane with partial infection of the implant. The infected part of the implant failed to osseointegrate with clear demarcation between osseointegrated (non-infected) and non-osseointegrated (infected) components of the implant. On further analysis, it was identified that covering the lateral part of the implant with muscle and good hygiene of the post-aural wound helps reduce the infection rates.

We also noted that most (four of six) cases mentioned above were from the initial cohort of the patients who underwent this technique. In the subsequent cases, results were more robust with early stabilisation of the cavity noted. A recent review by Choong *et al.* published in the *Journal of the Australian College of Surgeons* analysed 31 articles that mainly looked for the complication rates among different materials. Interestingly, major complication rates among autologous, allogenic versus synthetic materials were 6.8 per cent, 5.6 per cent versus 7.6 per cent.¹⁵ Allogenic materials are

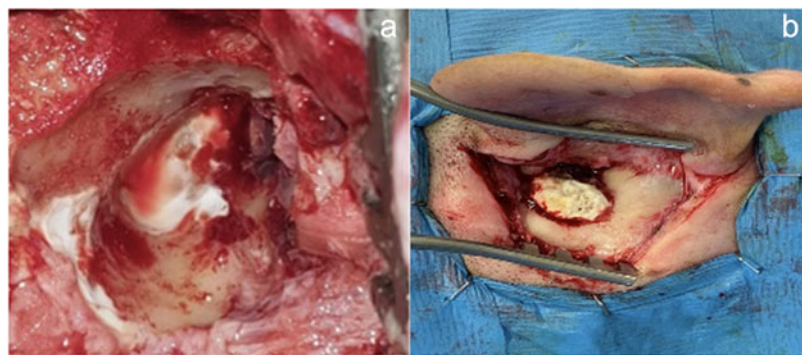


Figure 3. Osteointegration of HAP the bone cement (a) after partial explantation and (b) on re-exploration. HAP = hydroxyapatite.

generally not recommended because of the risks of transmissible diseases. Most common materials used were cartilage, muscle flaps and bone paste. The overall graft extrusion rate with synthetics among 448 ears was 3.6 per cent. Both Choong *et al.* and Skoulakis *et al.*, who have done a detailed review of this subject have not found any unusual complications apart from known mastoidectomy risks.^{15,16} We compared the rejection and complication rates with different synthetic materials shown in Table 3 (see above). In comparison, results look similar to other materials used in the literature and, as such, no unusual complications were noticed. Main complication noted was granulations in the EAC, which in fact is common even in non-obiterated mastoid cavities as well in the early healing period.^{17,18}

Hearing rehabilitation is not the main goal of mastoid obliteration itself. However, we analysed the audiometric thresholds to ensure that the material has no adverse effect on bone conduction thresholds. On average overall ABG remained stable or improved. None of the patients developed dead ear post-obliteration. See Figure 1.

Strengths of our study included solely using the most experienced otologist to avoid any bias of surgical expertise. A limitation of our study was the retrospective nature and the small sample size.

- The novel cement proves to be a safe and reliable choice for mastoid obliteration, particularly beneficial in cholesteatoma revision surgery.
- The results show favourable outcomes in terms of infection control and prevention of cholesteatoma recurrence.
- Its good biocompatibility suggests that the material is well-tolerated by the body, reducing the likelihood of adverse reactions post-surgery.
- The results also demonstrate adequate muscle flap coverage and post-operative good hygiene practices for better and quicker wound healing.
- Ready to use, self-setting hydroxyapatite bone cement is a good alternative to autologous options, potentially offering advantages in availability and reduced donor site complications.

Conclusion

Our pilot study shows that this novel ready-to-use calcium phosphate cement is a safe and reliable option for mastoid obliteration especially in cholesteatoma revision surgery. The material had favourable outcomes in terms of infection control and the absence of cholesteatoma recurrence. It also showed good biocompatibility. The researchers also emphasised the value of good hygiene and adequate muscle flap coverage in lowering infection rates and acquiring early dry cavities. Overall, the study provides

insights into the use of a novel material as a potential alternative to autologous materials in mastoid obliteration.

Acknowledgement. None.

Financial disclosure. None.

Conflict of interest. None.

References

- 1 van der Toom HFE, van der Schroeff MP, Pauw RJ. Single-stage mastoid obliteration in cholesteatoma surgery and recurrent and residual disease rates: a systematic review. *JAMA Otolaryngol Head Neck Surg* 2018;**144**:440–6
- 2 el-Seifi A, Fouad B. Long-term fate of plasty in the middle ear. *ORL J Otorhinolaryngol Relat Spec* 1998;**60**:198–201
- 3 LeClair KL, Bessen SY, Rees CA, Saunders JE. Outcomes of a novel alloplastic technique for external auditory canal repair in tympanomastoidectomy. *Laryngoscope Invest Otolaryngol* 2020;**5**:743–9
- 4 Yung MW. The use of hydroxyapatite granules in mastoid obliteration. *Clin Otolaryngol Allied Sci* 1996;**21**:480–4
- 5 Jeong J, Kim JH, Shim JH, Hwang NS, Heo CY. Bioactive calcium phosphate materials and applications in bone regeneration. *Biomater Res* 2019;**23**:4
- 6 Shah AM, Jung H, Skirboll S. Materials used in cranioplasty: a history and analysis. *Neurosurg Focus* 2014;**36**:E19
- 7 Stryker. A pre-clinical evaluation of a novel calcium phosphate bone cement: DirectInject®. In: https://cmf.stryker.com/assets/files/3q/directinject_biocomp_wp_vfinal.pdf [8 January 2021]
- 8 DirectInject [Internet]. In: <https://cmf.stryker.com/products/directinject> [30 August 2021]
- 9 Ridenour JS, Poe DS, Roberson DW. Complications with hydroxyapatite cement in mastoid cavity obliteration. *Otolaryngol Head Neck Surg* 2008;**139**:641–5
- 10 Ramsey MJ, Merchant SN, McKenna MJ. Postauricular periosteal-pericranial flap for mastoid obliteration and canal wall down tympanomastoidectomy. *Otol Neurotol* 2004;**25**:873–8
- 11 de Veij Mestdagh PD, Colnot DR, Borggreven PA, Orelia CC, Quak JJ. Mastoid obliteration with S53P4 bioactive glass in cholesteatoma surgery. *Acta Otolaryngol* 2017;**137**:690–4
- 12 Committee on Hearing and Equilibrium guidelines for the evaluation of results of treatment of conductive hearing loss. American academy of otolaryngology-head and neck surgery foundation, inc *Otolaryngol Head Neck Surg* 1995;**113**:186–7
- 13 Mosher HP. A method of filling the excavated mastoid with a flap from the back of the auricle. *Laryngoscope* 1911;**21**:1158–63
- 14 Leonard RB, Sauer BW, Hulbert SE, Per-Lee JH. Use of porous ceramics to obliterate mastoid cavities. *J Biomed Mater Res* 1973;**7**: 85–95

- 15 Choong KWK, Kwok MMK, Shen Y, Gerard J-M, Teh BM. Materials used for mastoid obliteration and its complications: a systematic review. *ANZ J Surg* 2022;**92**:994–1006
- 16 Skoulakis C, Koltsidopoulos P, Iyer A, Kontorinis G. Mastoid obliteration with synthetic materials: a review of the literature. *J Int Adv Otol* 2019;**15**:400–4
- 17 El-Sayed Abd Elbary M, Nasr WF, Sorour SS. Platelet-rich plasma in reconstruction of posterior meatal wall after canal wall down mastoidectomy. *Int Arch Otorhinolaryngol* 2018;**22**:103–7
- 18 Cho SW, Cho Y-B, Cho H-H. Mastoid obliteration with silicone blocks after canal wall down mastoidectomy. *Clin Exp Otorhinolaryngol* 2012;**5**: 23–7