

*Diagnostic Challenge*

# Diaphragmatic hernia: an unexpected cause of pseudopleural effusion

Eeling Goh

**CASE HISTORY**

A previously well 38-year-old man presented to the emergency department with acute shortness of breath lasting 2 days. He denied chest pain, cough, or fever. There was no history of trauma. He did not have any medical history of note and was not on any long-term medications. On arrival, the vital signs were temperature 36.5°C (97.7°F), heart rate 130 beats/min, respiratory rate 30 breaths/min, blood pressure 135/80 mm Hg, and oxygen saturation of 85% on room air. He was in moderate respiratory distress. The jugular venous pressure was raised, and there were bilateral coarse lung crackles. Heart sounds appeared to be louder on the right. There was no pitting pedal edema. Laboratory investigations, including complete blood count, serum electrolytes, and cardiac enzymes, were normal. The electrocardiogram was unremarkable. The pro-brain natriuretic peptide (pro-BNP) level was elevated at 2,256 ng/L. A chest radiograph showed a massive left pleural effusion causing tracheal deviation and mediastinal shift (Figure 1). An arterial blood gas taken on high-flow oxygen showed a pH of 7.24, carbon dioxide partial pressure of 84 mm Hg, oxygen partial pressure of 86 mm Hg, bicarbonate of 35 mmol/L, and oxygen saturation of 94% consistent with type 2 respiratory failure, for which the patient was put on noninvasive ventilation. The initial diagnosis based on the clinical findings and investigations was heart failure, and the patient received intravenous glyceryl trinitrate and diuretics.

The patient was transferred to the coronary care unit for continued management. Repeated chest radiographs during the clinical course revealed persistent

left pleural effusion despite clinical improvement. Needle aspiration was attempted blindly, but no fluid was drained. A chest computed tomographic (CT) scan (Figure 2) showed a large left diaphragmatic hernia with herniation of the bowel loops and mesentery with shift of the mediastinum to the right. There was near-complete collapse of the left lung. No pleural effusion was present. The patient subsequently improved and was weaned off noninvasive ventilation. Surgical repair was recommended, but the patient chose to leave without further care.

**DISCUSSION**

Congenital diaphragmatic hernias result from the developmental failure of the muscular entities of the diaphragm, causing displacement of abdominal contents into the thorax. The two main types are Bochdalek hernia (due to posterolateral defects) and Morgagni hernias (due to subcostosternal defects). These hernias appear to be more common than previously reported, with a reported incidence of 17% of Bochdalek hernias in adults.<sup>1</sup> Bochdalek hernias have a left-sided predominance of up to 90%. This is likely due to protection by the liver on the right side. Failure to consider the diagnosis can almost be expected given the nonspecific symptoms: chest pain, dyspnea, and gastrointestinal complaints. Failure to consider the diagnosis early can lead to worsening morbidity for complications, including intestinal obstruction, intestinal perforation, and respiratory distress, which are not uncommon and have been described in several case reports.<sup>2-4</sup> Our patient presented with acute respiratory distress and was

From the Department of Emergency Medicine, Alexandra Hospital, Singapore.

**Correspondence to:** Dr. Eeling Goh, Department of Emergency Medicine, Alexandra Hospital, 378 Alexandra Road, Singapore 159964; Ee\_Ling\_GOH@juronghealth.com.sg.

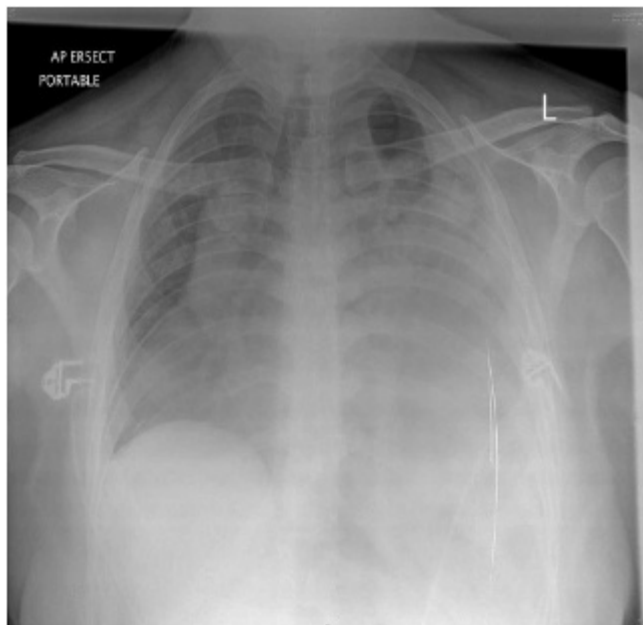
This article has been peer reviewed.

© Canadian Association of Emergency Physicians

CJEM 2014;16(5):411-412

DOI 10.2310/8000.2013.131140

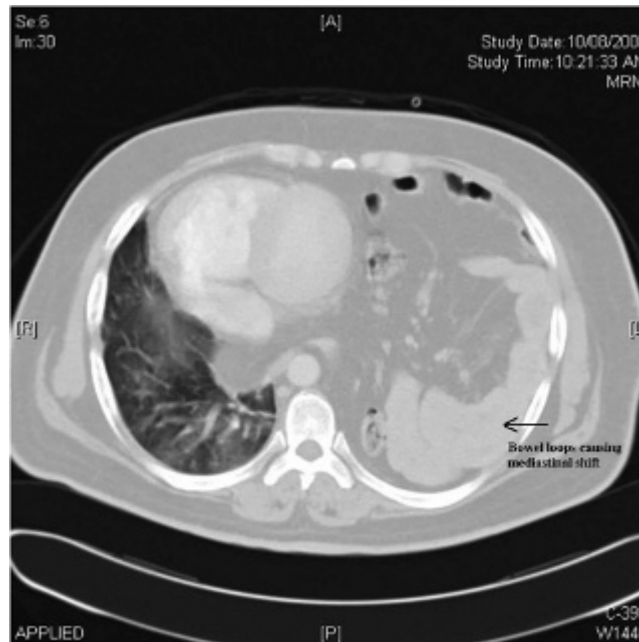



**Figure 1.** Opacification of left hemithorax with tracheal deviation and mediastinal shift.

treated for heart failure. In retrospect, the auscultatory findings of coarse crackles on the left lung field may have been bowel sounds. The hernia masqueraded as a massive pleural effusion on the chest radiograph. The nonhomogeneous nature (which can be attributed to bowel shadows) and the presence of a mediastinal shift—unusual even in massive pleural effusions—should have led the clinician to consider other diagnoses. The ground-glass opacities on the right lung field with a raised pro-BNP level can be explained by right-sided heart failure. This is not an uncommon complication associated with diaphragmatic hernias. This explained why the patient improved with diuretics and noninvasive ventilation. The finding of the diaphragmatic hernia may have been incidental.

Diagnosis may be straightforward when plain chest films show the presence of bowels in the thorax. They have been misinterpreted as pleural effusion in several case reports, as in our patient.<sup>5,6</sup> In such circumstances, thoracentesis or needle aspiration performed blindly may puncture the abdominal contents in the thorax. If in doubt, insertion of a nasogastric tube that reveals intrathoracic positioning of the stomach may confirm the diagnosis. Further evaluation with CT or magnetic



**Figure 2.** Herniation of bowel loops and mesentery with shift of mediastinum to the left and near-collapse of the left lung.

resonance imaging prior to invasive procedures when the diagnosis is being considered can avoid morbidity.

**Competing interests:** None declared.

**Keywords:** diaphragmatic hernia, dyspnea, pleural effusion

## REFERENCES

- Mullins ME, Stein J, Saini SS, Mueller PR. Prevalence of incidental Bochdalek's hernia in a large adult population. *AJR Am J Roentgenol* 2001;177:363-6, doi:10.2214/ajr.177.2.1770363.
- Berman L, Stringer D, Ein SH, Shandling B. The late-presenting pediatric Bochdalek hernia: a 20-year review. *J Pediatr Surg* 1988; 23:735-9, doi:10.1016/S0022-3468(88)80414-7.
- Naunheim KS. Adult presentation of unusual diaphragmatic hernias. *Chest Surg Clin N Am* 1998;8:359-69.
- Kocakusak A, Arıkan S, Senturk O, Yucel AF. Bochdalek's hernia in an adult with colon necrosis. *Hernia* 2005;9:284-7, doi:10.1007/s10029-004-0302-x.
- Kumar RV, Ramana DV, Gopal PR. Giant morgagnian hernia masquerading as pleural effusion. *J Indian Med Assoc* 2004;102: 98-9.
- Wooldridge JL, Partrick DA, Bensard DD, Deterding RR. Diaphragmatic hernia simulating a left pleural effusion. *Pediatrics* 2003;112:e487, doi:10.1542/peds.112.6.e487.