

# A case of infective endocarditis in an 8-year-old boy 3 months after transcatheter atrial septal defect closure using Figulla Flex II occluder

## Brief Report

**Cite this article:** Toyoshima Y, Tanaka T, and Matsuhisa H (2023) A case of infective endocarditis in an 8-year-old boy 3 months after transcatheter atrial septal defect closure using Figulla Flex II occluder. *Cardiology in the Young* **33**: 1030–1032. doi: [10.1017/S104795112200347X](https://doi.org/10.1017/S104795112200347X)

Received: 9 May 2022  
Revised: 17 October 2022  
Accepted: 17 October 2022  
First published online: 11 November 2022

### Keywords:

Child; atrial septal defect; infective endocarditis; vegetation; Figulla Flex II atrial septal defect occluder

### Author for correspondence:

Y. Toyoshima, MD, Department of Cardiology, Kobe Children's Hospital, 1-6-7, Minatojima - Minamimachi, Chuo-ku, Kobe, Hyogo, 650-0047, Japan. Tel: 81-78-945-7300; Fax: 81-78-302-1023.  
E-mail: [yuka.toyoshima224@gmail.com](mailto:yuka.toyoshima224@gmail.com)

Yuka Toyoshima<sup>1</sup> , Toshikatsu Tanaka<sup>1</sup>  and Hironori Matsuhisa<sup>2</sup>

<sup>1</sup>Department of Cardiology, Kobe Children's Hospital, Kobe, Japan and <sup>2</sup>Department of Cardiovascular Surgery, Kobe Children's Hospital, Kobe, Japan

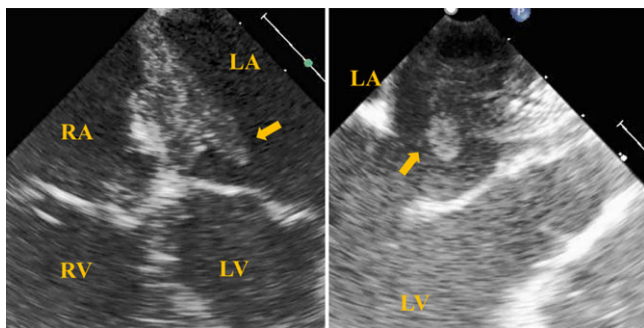
### Abstract

Infective endocarditis is a rare complication of atrial septal defect closure using transcatheter procedure. We report about infective endocarditis in an 8-year-old boy 3 months after transcatheter closure using a Figulla Flex II atrial septal defect occluder. Transesophageal echocardiography showed vegetation attached to the left atrium side of the device. Device removal and atrial septal defect closure were performed. The device was less endothelialized on the left than on the right atrium side. Therefore, insufficient endothelialization may cause infective endocarditis.

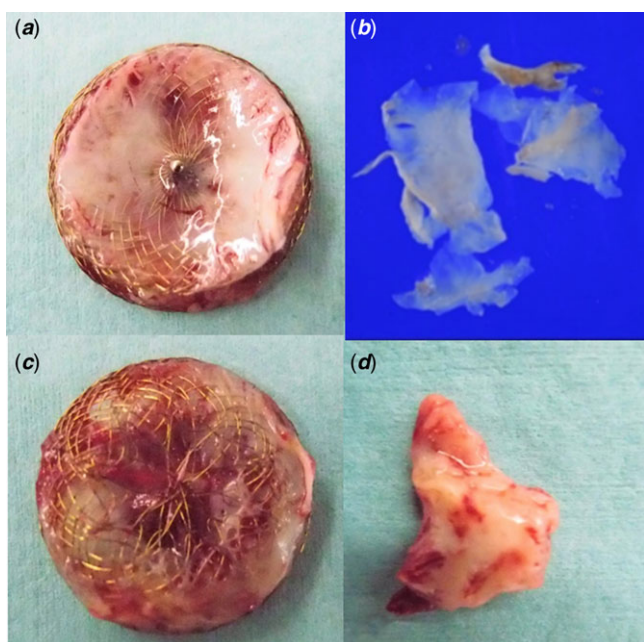
Some complications of atrial septal defect closure by transcatheter procedure require surgical removal, such as perforation of the aorta or atrial wall. Infective endocarditis with secundum atrial septal defect is a rare but also important complication<sup>1</sup> because it is sometimes found after transcatheter closure and it requires surgery.

### Case

An 8-year-old boy (body weight, 27.6 kg) had atrial septal defect, which was diagnosed based on the presence of negative T waves in a school-based electrocardiogram screening. He was admitted to our hospital for transcatheter atrial septal defect closure. Percutaneous atrial septal defect closure was performed under general anaesthesia. One gram of cefazolin sodium was administered intravenously before the procedure. Transesophageal echocardiography showed secundum atrial septal defect with a poor aortic rim, and the diameter of the balloon was 18 mm. We implanted a 21-mm Figulla Flex II (FF-II) atrial septal defect occluder without any complications, and he was discharged. He was maintained on 5 mg/kg/day of aspirin. He had a history of atopic dermatitis that had resolved a few years ago. He took no medication for atopic dermatitis, but eczematous crusts were observed at the medial aspect of each joint. His skin was dry, and he often scratched his whole body. He had no history of immunodeficiency. Two months after the procedure, he developed fever with intermittent headache. The fever persisted despite intake of sefcapen pivoxil. Two days after the onset of symptoms, he came to the emergency outpatient of our hospital. *Staphylococcus aureus* was detected from his blood culture. He was admitted to our hospital with the diagnosis of infective endocarditis. On admission, the body temperature was 37.2°C, and he did not appear ill. The patient had no atopic lesion on the skin, no Osler nodule, and no Janeway lesion. Cardiothoracic ratio on chest radiography was 45%; there was no cardiomegaly, pleural effusion, or dislodgement of the device. Electrocardiogram showed a negative T wave in V2–V4, unchanged from that at the first admission. Laboratory testing showed: C-reactive protein concentration, 5.94 mg/dL; white blood cell count,  $6.9 \times 10^9/L$  (56.7% neutrophils); and platelet count,  $113 \times 10^9/L$ . Fibrinogen and D-dimer levels were 5.72 g/L and 1.2 µg/mL, respectively. Transthoracic echocardiography did not reveal any vegetation. He was treated with cefazolin sodium, gentamicin, and rifampicin.<sup>2</sup> His fever was alleviated on day 6 of admission. Transesophageal echocardiography was performed on day 12 of admission which revealed a floating vegetation attached to the inferior part of the left atrial disk (Fig 1). Its location in the left atrium increased the risk for systemic embolisation. Head MRI did not reveal any abnormal findings. On day 14 of admission, we removed the device and closed the atrial septal defect surgically. The part of the vegetation adhered to the atrial wall near the mitral valve. The device and the vegetation were removed. Culture of the vegetation was negative. He was treated with gentamicin for 2 weeks, and the other antibiotics for 6 weeks and discharged. Gross examination of the disks showed that the right atrial disk surface was covered with thin smooth white endothelium, while left atrial disk surface was not (Fig 2). Photomicrograph of the atrial septum and vegetation revealed fibrinolysis in the myocardium, fibrotic connective tissue, and granulation tissue. There was infiltration of neutrophils, lymphocytes, plasma cells, and fibrotic lesions. No bacterial cell was found, but this was compatible with



**Figure 1.** Transesophageal echocardiography at the second admission shows floating vegetation attached to the inferior part of the left atrial disk. LA, left atrium, RA right atrium, LV, left ventricular, RV right ventricular.



**Figure 2.** Macroscopic aspects of the disks. The right atrial disk (a). The endothelium which covers the right atrial disk (b). The left atrial disk which is not covered with the endothelium (c). The vegetation is attached to the left atrial disk (d).

healed infective endocarditis. Photomicrograph of the endothelium on the surface of the disk showed endothelial cells, endocardium, and myocardium. Lymphocytes, plasma cells, and macrophages infiltrated the endocardium.

## Discussion

We presented the case of an 8-year-old boy with infective endocarditis after transcatheter closure of atrial septal defect using FF-II occluder. There are few reports of infective endocarditis after implantation of FF-II occluder. A previous report has shown 21 cases of infective endocarditis after transcatheter closure of atrial septal defect,<sup>3</sup> seven of these were in children. Infective endocarditis may occur at any time from 2 days up to 12 years after the procedure. *Staphylococcus aureus* was detected from blood culture in most cases. Many cases were detected by transesophageal echocardiography. The site of vegetation was the left atrium in 10 cases, left and right atria in 6 cases, and right atrium in a case, suggesting that most cases of infective endocarditis occur in the left atrium.

Treatment involved antibiotics in only 3 cases, while surgical removal of the device was performed in 18 cases, implying that surgical procedures were performed in many cases. The association between endothelialization and infective endocarditis was notable. Five cases did not have endothelialization, three cases were incomplete, and three cases showed endothelialization. In 8 of 11 cases, there was incomplete endothelialization. Even though infective endocarditis was rare in previous reports, the incidence is likely to increase as more of these procedures are performed; thus, the number of patients who have late complications might increase. Therefore, infective endocarditis might be one of the important complications after atrial septal defect device closure with device embolisation and perforation of the aorta or atrial wall. Screening by transesophageal echocardiography is insufficient and should be done urgently regardless of age. The device was less endothelialized on the left atrium which attaches to the vegetation than on the right atrium. Some previous reports explained the device showing also incomplete endothelialization, which suggested that insufficient endothelialization might induce infective endocarditis.<sup>4-7</sup> Differences in the degree of endothelialization between the device surfaces in right and left atria have been noted. Notably, the left atrium is more likely to exhibit insufficient endothelialization and to have adherent vegetations. There are some possible reasons for insufficient endothelialization of the left atrium. One of those is the structural feature of FF-II occluder. FF-II occluder has no left atrial hub, and it is assumed that this could be reducing the risk of thrombus formation on left atrial side and a single nitinol wire mesh with reduced wire concentration towards the centre giving the device additional flexibility. This potential benefit claimed by the manufacturers will have to be weighed against the decreased endothelialization. Second, blood flow and how blood interacts with the device differ between the two chambers; these may lead to decreased endothelialization of the device surface in the left atrium. Finally, a substance or factor in venous blood may enhance endothelialization in the right atrium. Further research on the mechanisms underlying the differences in endothelialization is warranted. Moreover, it is challenging to detect cases of insufficient endothelialization, and we need more expertise. On a larger device, poor endothelialization and thrombus attachment were observed 6 months after implantation by angioscopy from the right atrium.<sup>8</sup> It suggests that when using larger devices, the use of antiplatelets and antibiotic prophylaxis for dental procedures may need to be recommended for longer than 6 months. In the present case, the portal of entry of bacteria was suspected to be the skin. Atopic dermatitis is associated with severe infection including endocarditis.<sup>9,10</sup> The patient had no apparent atopic lesion on the skin, but he had a history of atopic dermatitis, and he often scratched his skin during admission. It suggests that patients who have a history of atopic dermatitis should be carefully observed after atrial septal defect device closure.

## Conclusion

We report the case of a patient who developed infective endocarditis 3 months after implantation of FF-II atrial septal defect occluder. Practitioners need to follow up patients after atrial septal defect device closure to avoid infective endocarditis, which is an important complication of this procedure.

**Acknowledgements.** The authors would like to express their gratitude to Dr Shogo Otake and Dr Masashi Kasai in the Division of Infectious Disease,

Department of pediatrics, Kobe Children's Hospital, who contributed treat the patient's infection, and Editage ([www.editage.com](http://www.editage.com)) for English language editing.

**Financial support.** This research received no specific grant from any funding agency, commercial, or not-for-profit sectors.

**Conflicts of interest.** None.

**Ethical standards.** All procedures performed in studies involving human participants were in accordance with the ethical standards of the institutional committee with the 1964 Helsinki declaration and its later amendments. The patient and his parents gave informed consent. All authors have read and approved the final manuscript.

## References

1. Sarris GE, Kirvassilis G, Zavaropoulos P, et al. Surgery for complications of trans-catheter closure of atrial septal defects: a multi-institutional study from the European Congenital Heart Surgeons Association. *Eur J Cardiothorac Surg* 2010; 37: 1285–1290.
2. Habib G, Lancellotti P, Antunes MJ, et al. 2015 ESC Guidelines for the management of infective endocarditis: The Task Force for the Management of Infective Endocarditis of the European Society of Cardiology (ESC). Endorsed by: European Association for Cardio-Thoracic Surgery (EACTS), the European Association of Nuclear Medicine (EANM). *Eur Heart J* 2015; 36: 3075–3128.
3. Amedro P, Soulatges C, Fraisse A. Infective endocarditis after device closure of atrial septal defects: case report and review of the literature. *Catheter Cardiovasc Interv* 2017; 89: 324–334.
4. Tamura Y, Yonehara Y, Horibata Y, et al. The first described case of late infective endocarditis after implantation of Figulla Flex II ASD occluder. *J Cardiol Cases* 2021; 23: 214–217.
5. Slesnick TC, Nugent AW, Fraser CD Jr., Cannon BC. Images in cardiovascular medicine. Incomplete endothelialization and late development of acute bacterial endocarditis after implantation of an Amplatzer septal occluder device. *Circulation* 2008; 117: e326–327.
6. Zahr F, Katz WE, Toyoda Y, Anderson WD. Late bacterial endocarditis of an amplatzer atrial septal defect occluder device. *Am J Cardiol* 2010; 105: 279–280.
7. Kitamura H, Yamamoto M, Kagase A. Mobile vegetations on a poorly endothelialized atrial septal defect closure device. *JTCVS Tech* 2021; 7: 240–241.
8. Tanabe Y, Suzuki T, Kuwata S, et al. Angioscopic evaluation of atrial septal defect closure device neo-endothelialization. *J Am Heart Assoc* 2021; 10: e019282.
9. Narla S, Silverberg JI. Association between atopic dermatitis and serious cutaneous, multiorgan and systemic infections in US adults. *Ann Allergy Asthma Immunol* 2018; 120: 66–72.e11.
10. Kondo N, Kondo N, Fukuda I. Rising awareness of the relationship between infective endocarditis and atopic dermatitis. *Circ J* 2013; 77: 1693–1694.