

Letter to the Editor: New Observation

Early Malignant Transformation of Intracranial Epidermoid Cyst: A Case Report and Systematic Review

Chia-Chen Tsai¹ , Mirna Hennawy², Stephen Yip³ , Kira Tosefsky^{1,4}, Justin Oh⁵, Mostafa Fatehi⁶, Rebecca Harrison² and Alexander D. Rebchuk⁶ 

¹Faculty of Medicine, University of British Columbia, Vancouver, BC, Canada, ²Division of Neurology, University of British Columbia, Vancouver, BC, Canada, ³Department of Pathology and Laboratory Medicine, University of British Columbia, Vancouver, BC, Canada, ⁴MD/PhD Program, University of British Columbia, Vancouver, BC, Canada, ⁵Division of Radiation Oncology, University of British Columbia, Vancouver, BC, Canada and ⁶Division of Neurosurgery, University of British Columbia, Vancouver, BC, Canada

Keywords: epidermoid cyst; chemotherapy; pembrolizumab; squamous cell carcinoma

Intracranial epidermoid cysts (IECs) are benign congenital lesions accounting for 0.2%–1.8% of primary intracranial tumours.¹ They commonly occur at the cerebellopontine angle (CPA), presenting with headaches and cranial neuropathies.¹ Herein, we report a case of IEC that underwent malignant transformation into squamous cell carcinoma (SCC) 14 months post-resection. We discuss a novel treatment paradigm with pembrolizumab, carboplatin, capecitabine and radiation therapy. Additionally, we conducted a systematic review of IECs undergoing early malignant transformation.

A 48-year-old healthy female presented with left-sided tinnitus and vertigo. MRI revealed a diffusion-restricted left CPA lesion (Figure 1A). She underwent a left retrosigmoid craniotomy with gross total resection. Pathology was consistent with an IEC. As the surgery was performed at an outside institution, the excised tissue was not available for further pathological or molecular testing. Fourteen months later, she presented again with progressive headache, nausea, vomiting and diplopia. MRI of the brain revealed an enlarging, peripherally enhancing cystic lesion within the prior resection cavity (Figure 1B–C). MRI spine confirmed leptomeningeal dissemination in the lumbar and sacral spine.

She underwent re-operation with fenestration and cyst drainage. A subtotal resection was undertaken as the cyst was adherent to surrounding neurovascular structures. Pathology revealed atypical keratinising squamous cells, dyskeratotic keratinocytes and a brisk mitotic rate. Immunohistochemistry demonstrated strong pan-keratin (AE1/AE3, CAM5.2, Dako Cytokeratin), diffusely positive p40 and focal epithelial membrane antigen (EMA) immunoreactivity; negative p16, SOX10, MelanA and HMB45; Ki67 index 25%–30%; and PD-L1 (clone 22C3) tumour proportion score of 40% (Figure 2). Personalised oncogenomic testing with next-generation DNA sequencing identified homozygous deletions in *BARD1*, *MTAP* and *CDKN2A/B*, *FANCA* intron 10 mutation, *ETV6-CDK6* fusion

and *TP53* R282P single nucleotide variant. The pathological diagnosis on re-resection was malignant SCC.

Postoperatively, she received adjuvant radiotherapy (26.7 Gy in 10 fractions) to the tumour bed followed by pembrolizumab (2 mg/kg) and carboplatin (area under curve [AUC] 5 mg/(mL·min)) every 3 weeks, completing four cycles. She then continued pembrolizumab alone every 3 weeks for five cycles. During this time, an MRI of the brain revealed a leptomeningeal deposit on the left abducens nerve, which was subsequently treated with focal radiation (22.5 Gy in 5 fractions). Given disease progression, she was switched to capecitabine (1250 mg/m² twice daily for 14 days followed by 7 days off) for 5 cycles. She remains alive 20 months after SCC diagnosis, without radiographic progression.

We conducted a systematic review of MEDLINE, EMBASE and Scopus from inception until December 2023 for cases of malignant transformations of IECs within 2 years of diagnosis. This identified 17 patients (8 females, 9 males) with mean age 56.1 (SD: 13.8) years (Supplementary Table 1). Most IECs (71%) were in the CPA. All underwent initial surgical resection with subtotal resection achieved in 71%. All transformed to SCC in a mean 11.0 (SD: 6.6) months post-resection. Two (12%) had leptomeningeal carcinomatosis. Fourteen (82%) cases underwent a second surgery, with six (35%) receiving adjuvant radiotherapy and/or chemotherapy. The mean survival time was 6.8 (SD: 9.1) months.

Despite IECs being considered benign, approximately 135 cases with malignant transformation have been reported.¹ While the average transformation time is 82.7 months,² we observed an accelerated progression within 14 months. Our review identified only 17 other IEC cases progressing to SCC within 2 years of initial diagnosis. The mechanism underlying accelerated malignant transformation remains unknown. Postulated causes include intrinsic tumour (e.g. high proliferative indices, oncogenic mutations predisposing tumours to rapid malignant progression)

Correspondence author: Alexander D. Rebchuk; Email: alexander.rebchuk@vch.ca

Cite this article: Tsai C-C, Hennawy M, Yip S, Tosefsky K, Oh J, Fatehi M, Harrison R, and Rebchuk AD. Early Malignant Transformation of Intracranial Epidermoid Cyst: A Case Report and Systematic Review. *The Canadian Journal of Neurological Sciences*, <https://doi.org/10.1017/cjn.2025.45>

© The Author(s), 2025. Published by Cambridge University Press on behalf of Canadian Neurological Sciences Federation. This is an Open Access article, distributed under the terms of the Creative Commons Attribution licence (<https://creativecommons.org/licenses/by/4.0/>), which permits unrestricted re-use, distribution, and reproduction in any medium, provided the original work is properly cited.

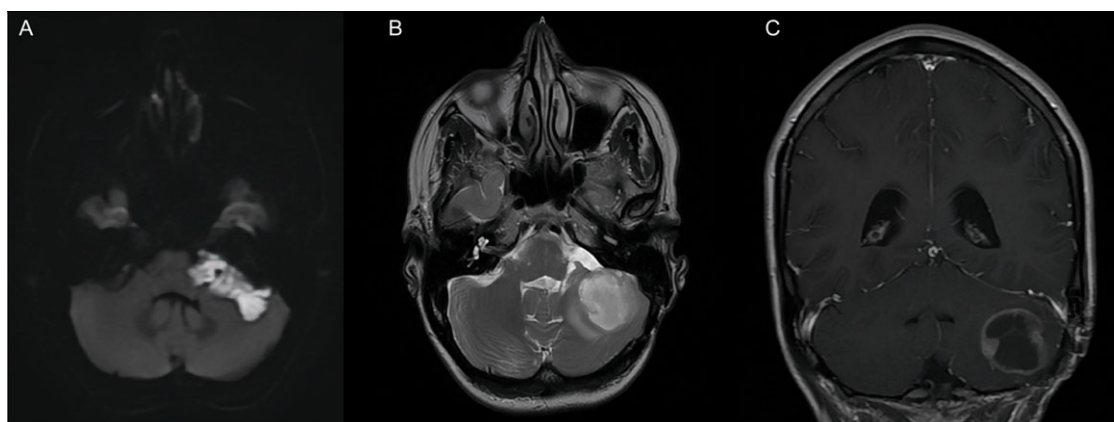

Figure 1. (A) Axial diffusion-weighted imaging (DWI) MRI of the benign-appearing left cerebellopontine angle tumour (43 × 17 mm) with diffusion restriction 11 months prior to index resection. (B) Axial T2 Fluid-attenuated inversion recovery (FLAIR) and (C) coronal T1 contrast-enhanced MRI demonstrating recurrent left cerebellopontine angle tumour (32 × 26 mm) 14 months post-index resection.

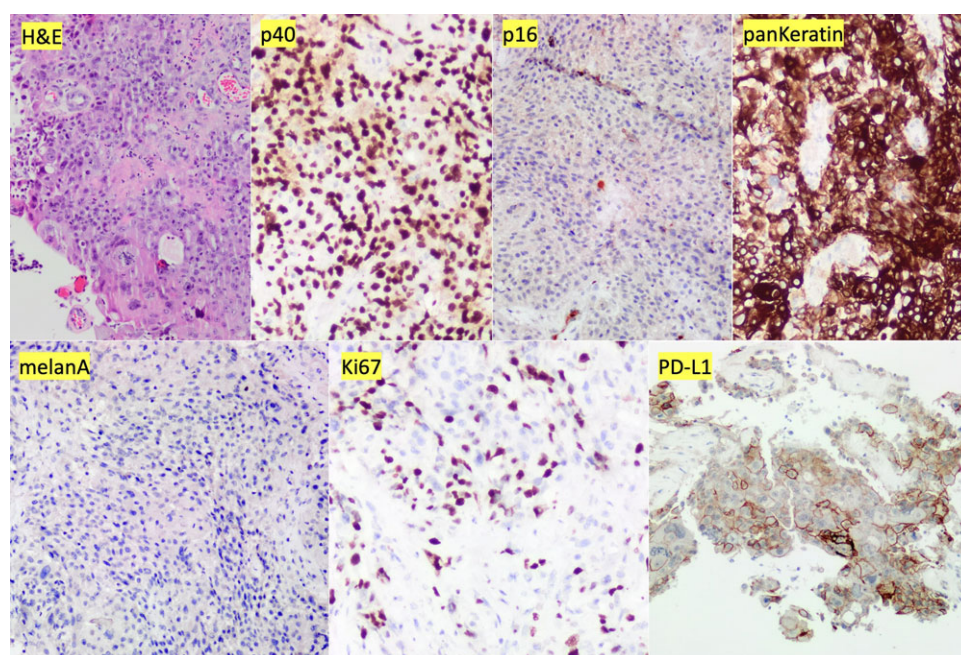


Figure 2. Haematoxylin and eosin (H&E) stains show fragments of atypical keratinising squamous cells infiltrating fibrous tissue with dyskeratotic keratinocytes and elevated mitotic rate consistent with squamous cell carcinoma. Immunohistochemistry demonstrates diffusely positive p40, p16 negative, strong pan-keratin (AE1/AE3, CAM5.2, Dako Cytokeratin), melanA negative, Ki67 tumour nuclear labelling index approximately 25%–30% and PD-L1 (clone 22C3) tumour proportion score of 40%.

and patient factors (e.g. altered or compromised immune systems). These factors, combined with surgical manipulation that may promote inflammation and pro-tumourigenic microenvironments, may accelerate progression.

While we cannot fully account for the accelerated malignant transformation in our case, we hypothesise potential contributors based on our genetic analysis. Intratumoural genetic alterations, particularly *TP53* mutation and *CDKN2A/B* homozygous deletion, which both function as tumour suppressor genes commonly altered in head and neck SCC (HNSCC),³ occurred in our case. Further, *MTAP* loss, also found in our case, has been associated with several solid tumours.⁴ We suspect that chronic inflammation from residual cystic tissue likely further drove transformation.

Personalised onco-genomics ancillary testing can help guide biology-driven therapeutic management, especially with atypical presentations and those without established treatments. In our

case, biomarker analysis identified microsatellite stability and low tumour mutational burden, suggesting limited benefit from PD-1 immune checkpoint inhibitor treatment.⁵ Notably, recent KEYNOTE-B10 trial results support pembrolizumab efficacy independent of PD-L1 expression,⁶ suggesting other mechanisms may underlie response in SCC. *MTAP* loss suggests potential benefit from anti-metabolite therapies,⁴ with capecitabine selected in our case because of its role in HNSCC treatment and evidence of blood-brain barrier penetrance.^{7–9}

Given the rarity of IEC malignant transformation, multidisciplinary collaboration is essential to guide management. In our case, treatment included surgical resection, adjuvant radiation therapy and chemotherapy. Our review found that while all cases underwent surgery, only 35% received adjuvant therapies. Adjuvant radiation therapy has been noted to yield higher overall survival than surgery alone.¹ Currently, there is no standard

chemotherapy regimen for primary intracranial SCC. We report novel pembrolizumab and carboplatin use in primary intracranial SCC, supported by clinical trials reporting promising HNSCC antitumour activity and safety.⁶ Following cycle completion, our patient started capecitabine, which has shown efficacy in HNSCC and central nervous system (CNS) penetration.⁷ While this remains a novel treatment for primary intracranial SCC, our patient has responded positively with no clinical or radiographical progression. Leptomeningeal dissemination from solid tumours is associated with poor prognosis and survival. Our patient received seven cycles of pembrolizumab prior to disease progression and remains alive on next-line therapy, despite leptomeningeal disease, supporting a therapeutic impact of immunotherapy. There is an ongoing phase III trial evaluating cetuximab and palbociclib use for CDKN2A homozygous loss in recurrent and metastatic HNSCC,¹⁰ which may be a future treatment option for our case.

Herein, we describe a case of accelerated progression of IEC to malignant SCC. Following surgical re-resection and radiation therapy, we achieved remarkable tumour stability with the novel application of pembrolizumab, carboplatin and capecitabine. Our review identified 17 other cases of early malignant transformation of IECs with a mean survival time of 6.8 months. Our patient remains alive 20 months following malignant transformation, without radiographic progression, demonstrating the potential benefit of our treatment paradigm. Further research is needed to determine the molecular and genetic factors contributing to accelerated malignant progression of IECs.

Supplementary material. The supplementary material for this article can be found at <https://doi.org/10.1017/cjn.2025.45>.

Author contributions. CT and ADR designed the work. CT and MH wrote the main manuscript text. CT and KT conducted all data collection and analysis. SY, JO, MF, RH and ADR substantively revised the work. All authors reviewed and approved the final manuscript prior to submission. All authors agree to be accountable for their contributions and ensure all inquiries related to the work are resolved with documentation.

Funding statement. None.

Competing interests. All authors report no conflicts of interest.

References

1. Eatz TA, Elarjani T, Chen SH, et al. Malignant transformation of an intracranial epidermoid cyst 25 years after initial surgery: a case report and systematic review. *World Neurosurg.* 2023;177:e52–e65. doi: [10.1016/j.wneu.2023.05.039](https://doi.org/10.1016/j.wneu.2023.05.039).
2. Sakamoto H, Akimoto J, Tsutsumi M, Ken KM, Ichimasu N, Kohno M. Radio-pathological characteristics of malignant transformation of an epidermoid cyst in the cerebellopontine angle: a case report. *Surg Neurol Int.* 2022;13:135. doi: [10.25259/SNI_1226_2021](https://doi.org/10.25259/SNI_1226_2021).
3. Deneka AY, Baca Y, Serebriiskii IG, et al. Association of TP53 and CDKN2A Mutation Profile with Tumor Mutation Burden in Head and Neck Cancer. *Clin Cancer Res.* 2022;28:1925–1937. doi: [10.1158/1078-0432.Ccr-21-4316](https://doi.org/10.1158/1078-0432.Ccr-21-4316).
4. Tang B, Testa JR, Kruger WD. Increasing the therapeutic index of 5-fluorouracil and 6-thioguanine by targeting loss of MTAP in tumor cells. *Cancer Biol Ther.* 2012;13:1082–1090. doi: [10.4161/cbt.21115](https://doi.org/10.4161/cbt.21115).
5. Goodman AM, Sokol ES, Frampton GM, Lippman SM, Kurzrock R. Microsatellite-stable tumors with high mutational burden benefit from immunotherapy. *Cancer Immunol Res.* 2019;7:1570–1573. doi: [10.1158/2326-6066.CIR-19-0149](https://doi.org/10.1158/2326-6066.CIR-19-0149).
6. Dzienis M, Cundom J, Fuentes CS, et al. Pembrolizumab plus carboplatin and paclitaxel as first-line therapy for recurrent/metastatic head and neck squamous cell carcinoma (KEYNOTE-B10): a single-arm phase IV trial. *J Clin Oncol.* 2024;42:2989–2999. doi: [10.1200/jco.23.02625](https://doi.org/10.1200/jco.23.02625).
7. Morikawa A, Peereboom DM, Thorsheim HR, et al. Capecitabine and lapatinib uptake in surgically resected brain metastases from metastatic breast cancer patients: a prospective study. *Neuro Oncol.* 2015;17:289–295. doi: [10.1093/neuonc/nou141](https://doi.org/10.1093/neuonc/nou141).
8. Freedman RA, Gelman RS, Anders CK, et al. TBCRC 022: a phase II trial of Neratinib and capecitabine for patients with human epidermal growth factor receptor 2-positive breast cancer and brain metastases. *J Clin Oncol.* 2019;37:1081–1089. doi: [10.1200/JCO.18.01511](https://doi.org/10.1200/JCO.18.01511).
9. Bachelot T, Romieu G, Campone M, et al. Lapatinib plus capecitabine in patients with previously untreated brain metastases from HER2-positive metastatic breast cancer (LANDSCAPE): a single-group phase 2 study. *Lancet Oncol.* 2013;14:64–71. doi: [10.1016/S1470-2045\(12\)70432-1](https://doi.org/10.1016/S1470-2045(12)70432-1).
10. Adkins D, Oppelt P, Lu E, et al. *Palbociclib and Cetuximab Versus Cetuximab Monotherapy for Patients With CDKN2A-altered, HPV-unrelated Head and Neck Squamous Cell Carcinoma Who Experienced Disease Progression on a PD-1/L1 Inhibitor.* ClinicalTrials. Gov. 2024. Updated 2024 Jun 17. <https://clinicaltrials.gov/study/NCT04966481>.