

THE CHARACTERISATION OF INDIVIDUALS WITH RESPECT TO WILSON'S DISEASE

SEAN O'REILLY

Department of Neurology, The George Washington University Medical Center, Washington, D.C., USA

In the case of heredo-familial diseases it is desirable to identify the abnormal genotype, the homozygously abnormal individual, if possible while still asymptomatic, and the carrier of the abnormal gene or allele, the heterozygote.

So far as Wilson's disease is concerned, it is possible to diagnose individuals as presymptomatic homozygotes by finding Kayser-Fleischer corneal rings on slit-lamp microscopy, or by demonstrating increased liver-copper on needle biopsy.

False-negative results are common, however, and more reliable identification of the presymptomatic homozygote as well as the heterozygote can be achieved by studies of the physiology of copper, using tracer doses of radioactive copper, ⁶⁷copper, which has a physical half-life of about 61 hours. Using this method it can be shown:

- 1. That there is prolonged retention of copper in the whole body in both homozygotes and heterozygotes, the former showing more prolonged retention than the latter.*
 - 2. In both there is retention of copper in the liver, again more marked in the homozygote than in the heterozygote.*
 - 3. There is decreased intestinal excretion of copper in both cases as manifested by decreased biliary radiocopper and decreased stool radiocopper, and again this is most marked in the homozygote.*
 - 4. Urinary excretion of radiocopper is usually increased significantly in the homozygote, but is usually normal or only very slightly increased in the heterozygote.*
 - 5. The additional finding of impaired ceruloplasmin biosynthesis is sufficient usually to distinguish with certainty between the presymptomatic homozygote and the heterozygote.*
-

When we speak of characterising individuals with respect to a disease process we mean to answer the question, "Does he have it or not?"

In the case of clinically obvious diseases, such as an infectious process or cancer, this may be easy, though we do recognise the fact that an infection may be latent and only indirectly identifiable, and a cancer, especially of some internal organs, may be occult. Where heredo-familial disorders are concerned we are at pains to identify the abnormal genotype, the homozygously abnormal, and the carrier of the abnormal gene or allele, the heterozygote.

One of the goals of biochemical genetics is to identify the former while still presymptomatic, so that preventive treatment may be instituted if available. If the heterozygous state can be identified in the case of recessive heredity, its only purpose is to provide information for genetic counseling, though one hopes too that elucidation of the effect of an abnormal allele may illuminate the metabolic abnormalities determined by the defective gene.

The condition known in the English-speaking world as Wilson's disease is thought to

be transmitted as an autosomal recessive defect. Its phenotypic manifestations are very variable, not only in terms of age of onset, but also in regard to the clinical phenomenology. The latter reflect a variety of predominant organ involvement and we can recognise broad, though overlapping, groups of phenotypes:

1. *Primarily neurologic* - Classic Wilson's disease and pseudosclerosis of Westphal and Strümpell.
2. *Primarily hepatic* - One variety of "idiopathic" juvenile cirrhosis, the primary abdominal form referred to by Bramwell in 1916.
3. *Primarily renal* - A variety of renal tubular acidosis.
4. *Primarily hemopoietic* - Presenting as hemolytic anemia.

Common to all the phenotypic expressions of the disease is a clinical phenomenon unique to this disease — the Kayser-Fleischer corneal ring.

This artefact of nature is important as *the* clinical diagnostic hallmark of the disease, so important that when we can identify its presence by slit-lamp microscopy in an asymptomatic patient, we can say with confidence that that patient is a homozygote of Wilson's disease. But it is also important as a sign of the characterisation of the disease in terms of chemical pathology of the tissues.

It has been known for 30 years or more that there is in this disease abnormal accumulations of copper in the liver and in the cornea; indeed copper is variably increased in all tissues in which it has been measured. Furthermore, there is little doubt, at this point in time, that the accumulations of copper are responsible for the organ damage and the clinical manifestations of the disease. As a corollary, the clinical signs can be reversed in many cases and prevented from appearing in asymptomatic homozygotes by adequate chelation therapy as for example with penicillamine.

So we can say that individuals could be diagnosed as presymptomatic homozygotes of Wilson's disease by finding increased liver-copper on needle biopsy. The only problem is that the deposition of copper is so variable in its degree, even in the liver, that it is entirely possible to get false-negative results on random needle biopsy.

The kind of studies which I will now summarise, though tedious and expensive, are in my view much more reliable in identifying the presymptomatic homozygote, and have the further advantage that by their means we can also identify the heterozygote, provided the latter does not have clinical or laboratory evidence of hepatocellular failure.

These are studies of the physiology of copper using tracer doses of radioactive copper, ⁶⁷copper, which has a physical half-life of about 61 hours. Following intravenous administration, its elimination from the body is monitored in two ways — by whole-body counting, and by measuring stool and urinary excretion. The distribution of the tracer in the body can be visualised by means of a whole-body scanner or a scintillation camera, but for diagnostic purposes we prefer to record hepatic uptake and release by means of an external probe-counter.

It is also possible to monitor the incorporation of copper into two of the blood copper-proteins, ceruloplasmin in the plasma and erythrocyuprein in the red cells, if specific antisera to these proteins are available, but this is not necessary for diagnostic purposes. We know that some homozygotes of this disease and most, if not all, heterozygotes, have no problem with ceruloplasmin biosynthesis: the erythrocyuprein date, while interesting, add nothing to the diagnostic characterisation of the individual being studied.

TABLE 1
EXCRETION OF ⁶⁷COPPER IN CONTROL SUBJECTS
Excretion of ⁶⁷Cu after I.V. dose compared to whole-body retention (10-12 day collection unless otherwise noted)

Patient	Age (years)	Sex	Status	Stool ⁶⁷ Cu (% dose)	Urinary ⁶⁷ Cu (% dose)	Stool & urine	Whole-body T 1/2 (days)
<i>T.F.</i>	21	F	Normal	40	0.6	40.6	23
<i>C.P.</i>	50	M	Normal	39 (14 days)	0.54 (14 days)	39.54	29
<i>W.W.</i>	25	M	Neurol. control	23.3 (14 days)	0.58 (14 days)	23.88	27
<i>H.W.</i>	61	M	Mild cirr. Neurol. control	34	0.6	34.6	19
<i>G.C.</i>	22	M	Normal	14 (8 days)	0.3 (8 days)	14.3	27
<i>R.G.</i>	40	M	Cirrhotic	11 (4 days)	0.5 (4 days)	11.5	23
<i>J.J.</i>	48	M	Cirrhotic	21 (9 days)	0.5	21.5	
<i>W.K.</i>	46	M	Cirrhotic Fatty liver ascites	8	2	10	45
<i>R.H.</i>	39	M	Cirrhotic ascites	11.8 (14 days)	2.35 (14 days)	14.15	47

TABLE 2
EXCRETION OF ⁶⁷COPPER IN WILSONIAN PATIENTS (HOMOZYGOTES)
Excretion of ⁶⁷Cu after I.V. dose (10-12 day collection unless otherwise noted)

Patient	Age	Sex	Stool ⁶⁷ Cu (% dose)	Urinary ⁶⁷ Cu (% dose)	Cumulative stool & urine	Whole-body T 1/2 (days)
<i>L.B.</i>	44	F	3.9	1.5	5.4	74
<i>D.B.</i>	18	M	0.4	6.2	6.6	97
<i>K.C.</i>	38	F	10	3.2	13.2	296
<i>S.G.</i>	20	F	2.2, 2.3	2.6, 1.4	4.8, 3.7	108, 104
<i>B.G.</i>	15	M	3.8 (3 days) 3 (8 days)	2.4 (3 days) 1.9 (8 days)	6.2, 4.9	106, 129
<i>J.H.</i>		M	4.4	4.2	8.6	122
<i>C.O.</i>	17	F	5.6	4.7	10.3	232
<i>J.O. Jr.</i>	16	M	2.6	2.4	5	192

TABLE 3
EXCRETION OF ^{67}Cu IN WILSONIAN PATIENTS (HETEROZYGOTES)
Excretion of ^{67}Cu after I.V. dose (10-12 day collections unless otherwise noted)

Patient	Age	Sex	Stool ^{67}Cu (% dose)	Urinary ^{67}Cu (% dose)	Cumulative stool & urine	Whole-body T 1/2 (days)
<i>J.O. Sr.</i>	68	M	9.8	0.45	10.25	45
<i>A.O.</i>	54	F	23 (14 days)	0.8 (14 days)	23.8	104
<i>R.G.</i>	48	M	7.3 (5 days)	0.5 (5 days)	7.8	73
<i>M.G.</i>	18	M	19	0.6	19.6	51
<i>J.C. Jr.</i>	53	M	10	0.6	10.6	63
<i>T.C.</i>	22	M	9	1.2	10.2	75

Such studies of the physiology of copper have been carried out in a reasonable large number of control subjects (including normal volunteers), known homozygotes of Wilson's disease, presumptive heterozygotes (parents), and family members, usually sibs of known homozygotes.

Two populations were studied — a Chinese population at U.S. Naval Medical Research Unit No. 2 (NAMRU-2) in Taipei, Taiwan, and an American population at the Clinical Study Center, San Francisco General Hospital.

The results of the studies in each center were comparable. Tables 1, 2 and 3 show the elimination of copper (cumulative stool and urinary excretion and whole-body half-times). Figures 1, 2 and 3 show in graphic form the data from representative individual studies. Figures 4, 5 and 6 demonstrate the pattern of uptake and release of radiocopper by the liver as documented by external probe counting in the normal subject, the homozygously abnormal, and the heterozygote of Wilson's disease.

It should be pointed out that the data plotted in Figures 4, 5 and 6 are ratios, counts per minute versus counts per minute zero time (CPM/CPM₀). At zero time all the radioactivity is in the blood pool, hence these ratios reflect net hepatic uptake and release.

What do such studies reveal?

1. That in those persons homozygous and heterozygous for this disease there is prolonged retention of copper in the body.
2. That this prolonged retention is, in large part probably, due to retention of copper in the liver, with failure of intestinal excretion: the retention by liver is documented by external probe counting.
3. The reduced intestinal excretion of copper is corroborated by the reduction in stool radiocopper, most marked in the homozygously abnormal.
4. Although the homozygote exhibits a variable increase in urinary excretion of copper, it is not sufficient to compensate for the reduction in stool elimination, and the cumulative stool and urinary data in general agree very well with the whole-body measurements.

A further statement can be made about the intestinal excretion data. Animal studies had shown that most of the stool copper is derived from the bile, and in a number of the human

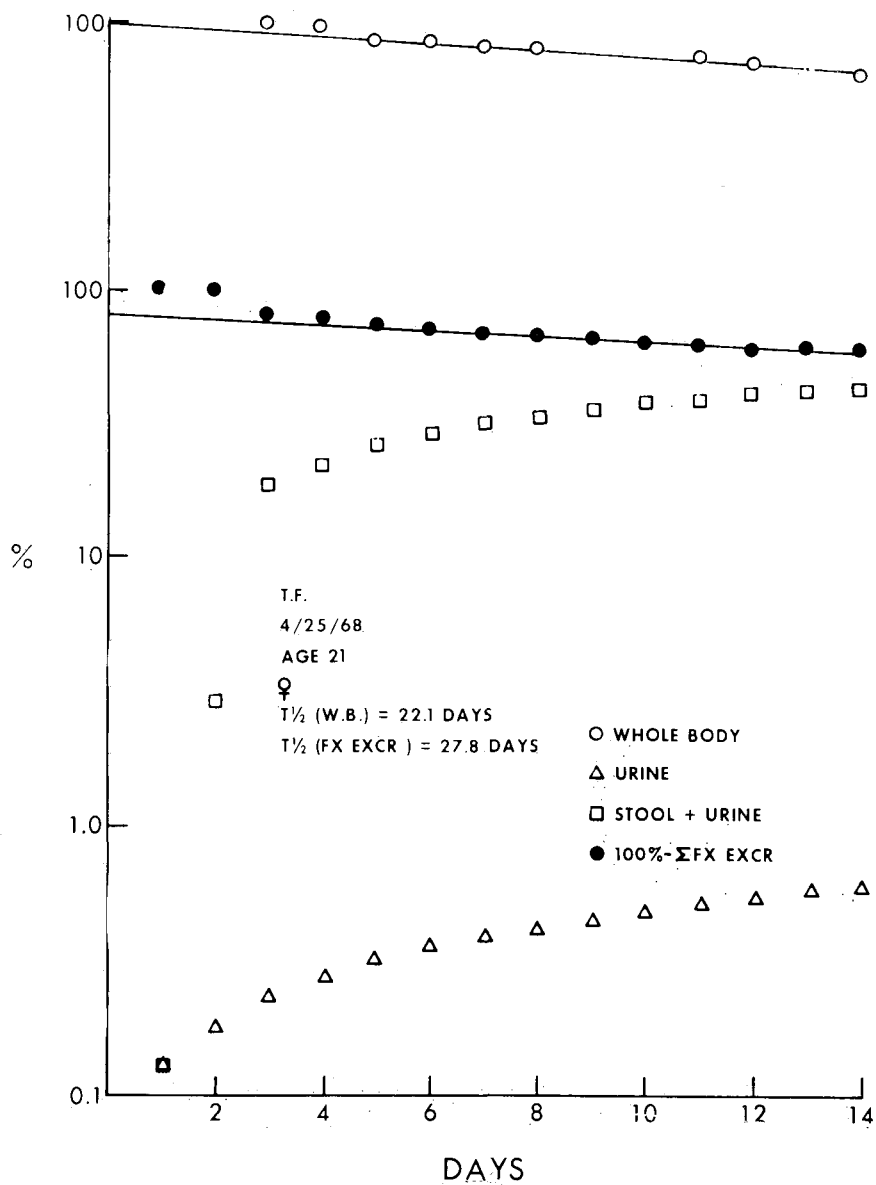


Fig. 1. Excretion of copper in normal subject.

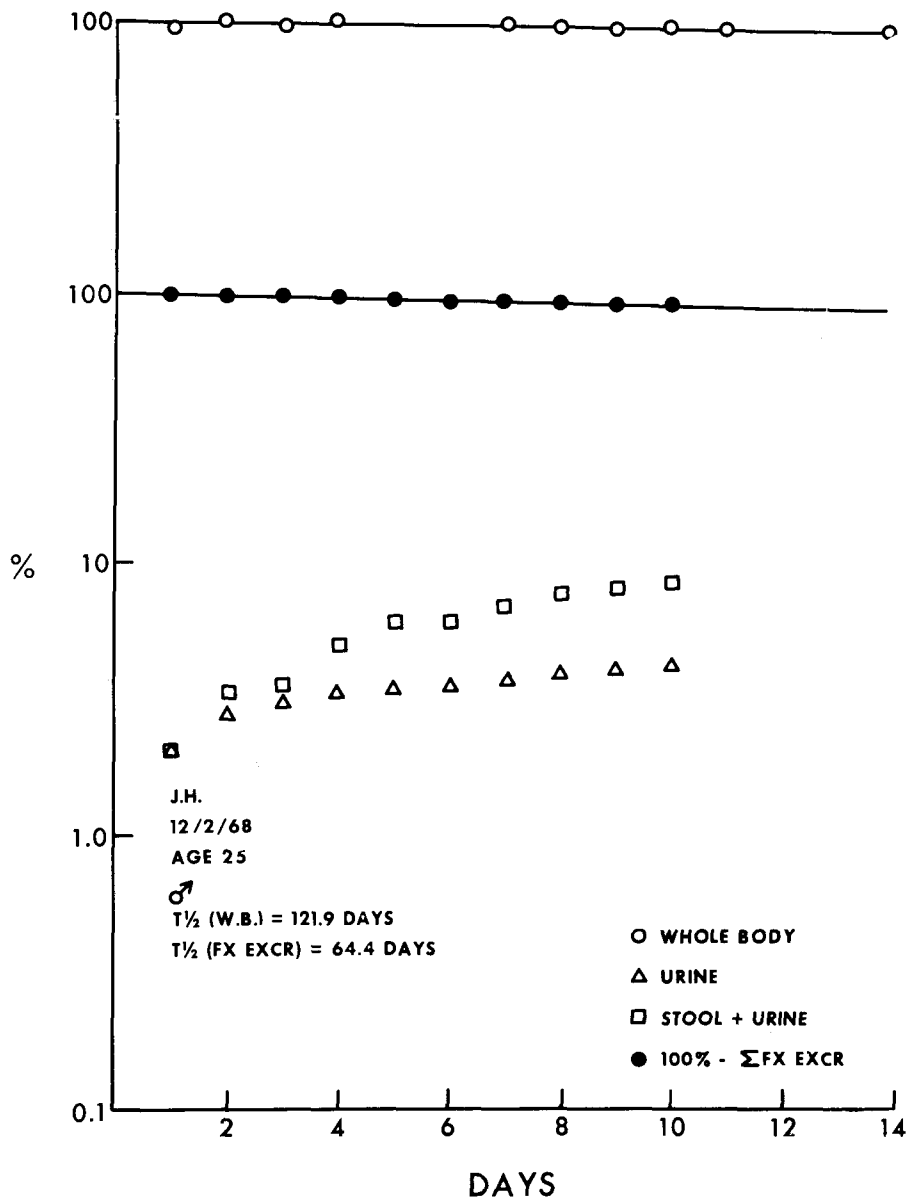


Fig. 2. Excretion of copper in homozygote of Wilson's disease.

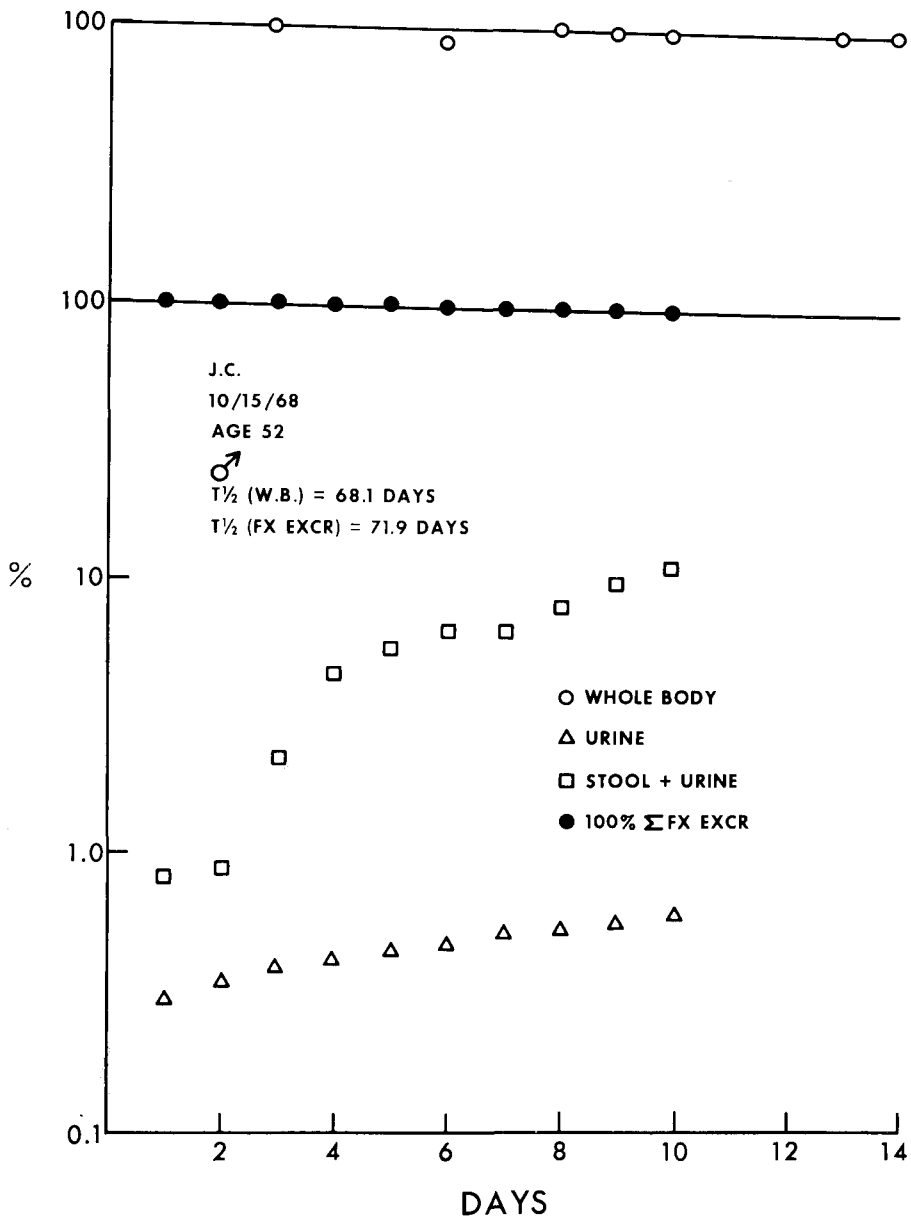


Fig. 3. Excretion of copper in heterozygote of Wilson's disease.

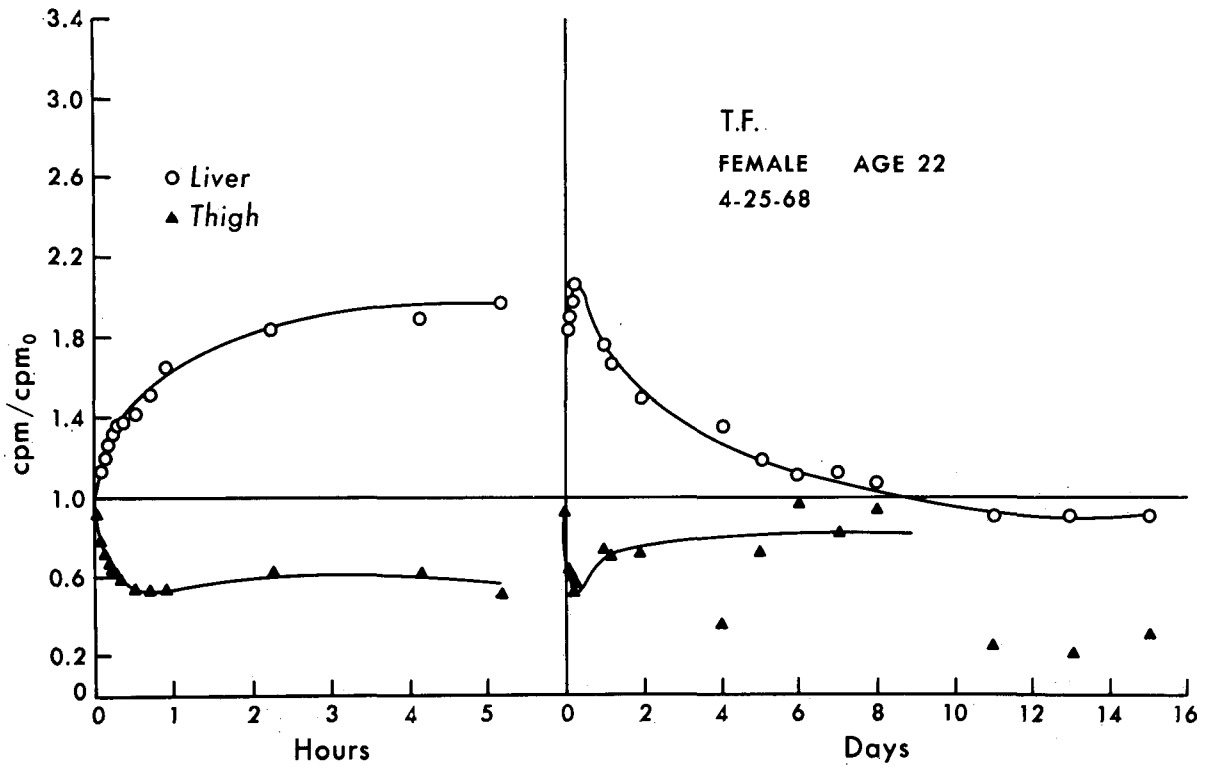


Fig. 4. Liver and thigh muscle net uptake of radiocopper in the normal subject.

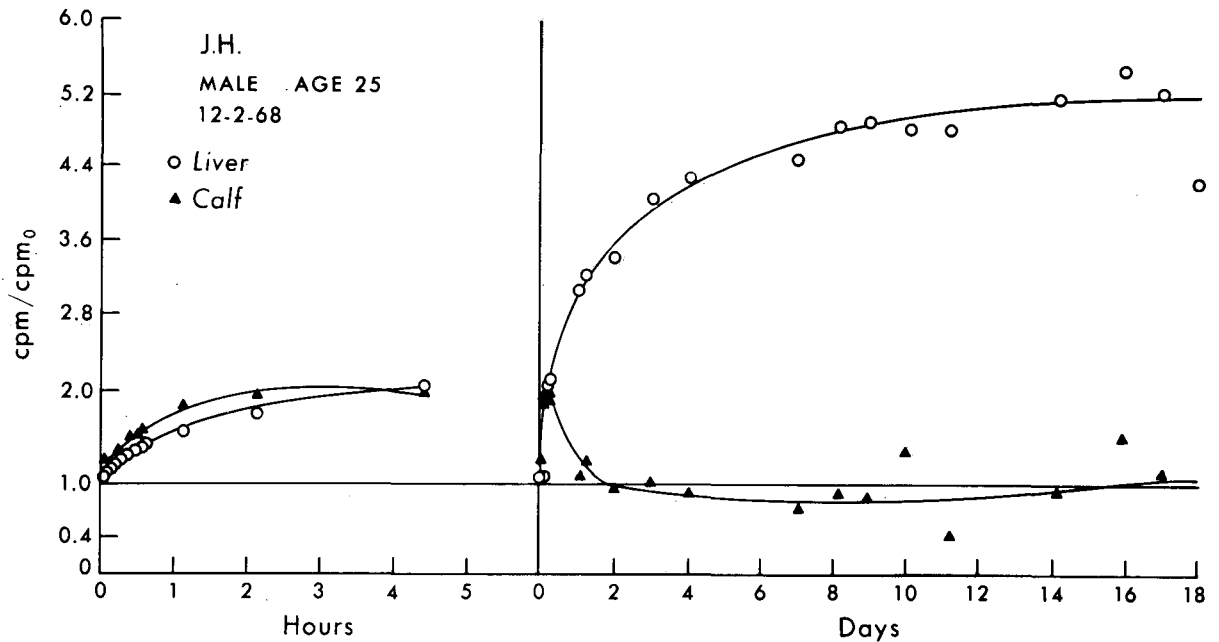


Fig. 5. Liver and thigh muscle net uptake of radiocopper in the Wilsonian homozygote.

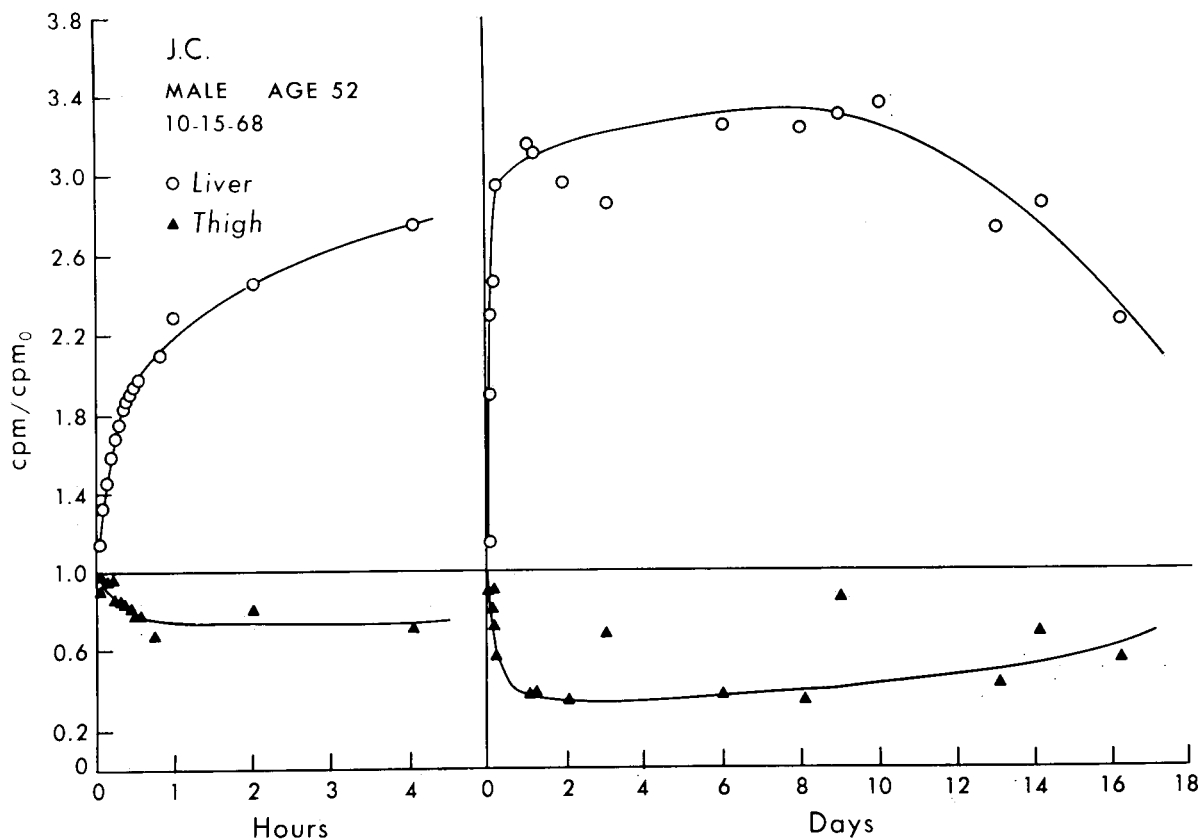


Fig. 6. Liver and thigh muscle net uptake of radiocopper in the heterozygote of Wilson's disease.

subjects studied by us we were able to confirm that finding by intermittent sampling of the duodenal contents by means of a modified intestinal biopsy capsule. The data from these studies are shown in Table 4. They show a considerable reduction in the radiocopper content of the duodenal samples in the Wilsonian subjects compared with the control subjects. Most of this biliary radiocopper is protein-bound, as seen from Table 5.

We believe that it is bound in a copper-protein unique to bile, and we are at present engaged in isolating and purifying it, with the hope of producing specific antibody to it, as well as characterising it physico-chemically. It should be possible then to pursue further our finding of decreased biliary excretion of radiocopper in the Wilsonian subjects, to ascertain whether the protein is deficient, or is defective in some way, so that less copper is excreted in the bile.

Meantime we can conclude with reasonable confidence that, if the usual tests of liver-function are normal, the individuals who are homozygotes or heterozygotes of Wilson's disease can be distinguished from the normal population by means of tracer studies using ⁶⁷copper.

TABLE 4
48-HOUR CUMULATIVE ⁶⁷COPPER IN DUODENAL SAMPLES

Patient	Status	Total volume aspirated (ml)	% dose in total volume	% dose/ml aspirated	% dose/mg bilirubin
<i>T.F.</i>	Normal	92	0.42	0.0046	
<i>H.W.</i>	Neurol. control	54	0.50	0.009	0.13
	Mild cirrh.				
<i>G.B.</i>	Normal	41	0.30	0.007	0.012
<i>C.P.</i>	Normal	30	0.08	0.003	0.086
<i>G.C.</i>	Normal	46	0.14	0.003	0.015
<i>W.B.</i>	Homozygote	108	0.026	0.0002	0.0004
<i>K.C.</i>	Homozygote	104	0.16	0.0015	
<i>J.H.</i>	Homozygote	Study I 69	0.012	0.0002	0.0015
		Study II 35	0.004	0.0001	
<i>J.O. Jr.</i>	Homozygote	52	0.007	0.0001	
<i>R.B.</i>	Homozygote	42	0.003	0.0001	0.00036
<i>A.O.</i>	Heterozygote	63	0.057	0.0009	
<i>J.C. Jr.</i>	Heterozygote	138	0.21	0.0015	0.003
<i>T.C.</i>	Heterozygote	52	0.09	0.0015	0.0049

TABLE 5
RADIOCOPPER PROTEIN-BOUND IN BILE

Subject	Status	Radiocopper (% values)		
		Day 0	Day 1	Day 2
<i>H.W.</i>	Normal	90-97	90-96	88-93
<i>C.P.</i>	Normal	95	88	91
<i>G.B.</i>	Normal	94	88	89
<i>G.C.</i>	Normal	84	95	92
<i>J.O. Jr.</i>	Homozygote	50-90	88-98	
<i>J.H.</i>	Homozygote	94-96	87	81-89
<i>R.B.</i>	Homozygote	91	90	88
<i>K.C.</i>	Homozygote	75-91	78-92	
<i>J.O. Sr.</i>	Heterozygote	80-97	96	
<i>J.C. Jr.</i>	Heterozygote	79-93	64-91	85-88
<i>R.H.</i>	Heterozygote	97-99	92-97	
<i>T.C.</i>	Heterozygote	87	82	89

It is not always possible to distinguish with certainty the heterozygote from the presymptomatic homozygote: in the few borderline cases we have studied so far, however, the additional findings of impaired ceruloplasmin biosynthesis, increased urinary copper, and early deposition of copper in the cornea as detected by slit-lamp microscopy, have served to decide the issue.

Dr. Sean O'Reilly, Department of Neurology, The George Washington University Medical Center, 2150 Pennsylvania Avenue, N.W., Washington, D.C. 20037, USA.