

Disclosure of interest The authors have not supplied their declaration of competing interest.

<http://dx.doi.org/10.1016/j.eurpsy.2017.01.1018>

EV0689

Cerebellar activity in young people with familial risk for psychosis – The Oulu brain and mind study

T. Jukuri^{1,*}, V. Kiviniemi², J. Veijola¹

¹ Research Unit of Clinical Neuroscience, University of Oulu, Psychiatry, Oulu, Finland

² Oulu University Hospital, Diagnostic Radiology, MIPT, Oulu, Finland

* Corresponding author.

Objective The cerebellum plays a critical role in cognition and behavior. Altered function of the cerebellum has been related to schizophrenia and psychosis but it is not known how this applies to spontaneous resting state activity in young people with familial risk for psychosis.

Methods We conducted resting-state functional MRI (R-fMRI) in 72 (29 male) young adults with a history of psychosis in one or both parents (FR) but without their own psychosis, and 72 (29 male) similarly healthy control subjects without parental psychosis. Both groups in the Oulu Brain and Mind Study were drawn from the Northern Finland Birth Cohort 1986. Participants were 20–25 years old. Parental psychosis was established using the Care Register for Health Care. R-fMRI data pre-processing was conducted using independent component analysis with 30 and 70 components. A dual regression technique was used to detect between-group differences in the cerebellum with $p < 0.05$ threshold corrected for multiple comparisons.

Results FR participants demonstrated statistically significantly increased activity compared to control subjects in the anterior lobe of the right cerebellum in the analysis with 70 components. The volume of the increased activity was 73 mm³. There was no difference between the groups in the analysis with 30 components (Fig. 1).

Conclusion The finding suggests that increased activity of the anterior lobe of the right cerebellum may be associated with increased vulnerability to psychosis. The finding is novel, and needs replication to be confirmed.

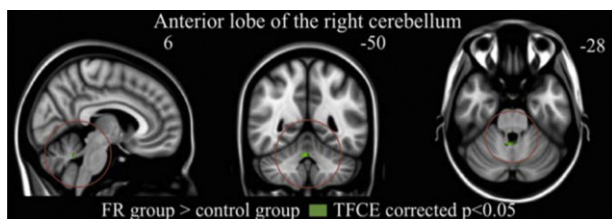


Fig. 1

Disclosure of interest The authors have not supplied their declaration of competing interest.

<http://dx.doi.org/10.1016/j.eurpsy.2017.01.1019>

EV0690

Atypical callosal morphology in developmental language disorder

E. Luders^{1,*}, F. Kurth¹, L. Pigdon², G. Conti-Ramsden³, S. Reilly⁴, A. Morgan²

¹ UCLA School of Medicine, Psychiatry, Los Angeles, USA

² Murdoch Childrens Research Institute, Murdoch Childrens Research Institute, Melbourne, Australia

³ University of Manchester, University of Manchester, Manchester, United Kingdom

⁴ Menzies Health Institute at Griffith University, Gold Coast, Australia

* Corresponding author.

Introduction Developmental language disorder (DLD) is common, yet the neurobiology of DLD is poorly understood. A key hypothesis suggests atypical functional lateralization of language, which might be accompanied structurally by a deficit in inter-hemispheric connectivity of language-related regions. Indeed, aberrations of the corpus callosum have been associated with language deficits in children with frank neurological lesions and/or born pre-term. In contrast, studies examining the corpus callosum in children with DLD remain elusive.

Objective We aimed to expand this largely understudied field by comparing callosal morphology between 17 children with DLD and 17 typically developing children carefully matched for sex and age.

Methods We analyzed high-resolution structural magnetic resonance imaging data applying a well-validated computational approach, which captures the thickness of the corpus callosum with a high regional specificity at 100 equidistant points.

Results As shown in Fig. 1, we observed a significantly thinner corpus callosum, particularly in the splenium, in children with DLD compared to typically developing controls (DLD < CTL).

Conclusions These findings indicating pronounced aberrations in the brain's largest whiter matter tract make an important contribution to an understudied field of research and support the theory that DLD is accompanied by atypical lateralization of language function.

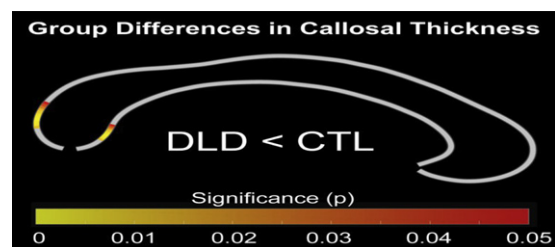


Fig. 1

Disclosure of interest The authors have not supplied their declaration of competing interest.

<http://dx.doi.org/10.1016/j.eurpsy.2017.01.1020>

EV0691

Quantitative EEG may help differentiating bipolar disorder at old age from frontotemporal dementia

S.Z. Metin^{1,*}, B. Metin², B. Kocarlan², C. Salcini³, N. Tarhan¹

¹ Uskudar University, Psychiatry, Istanbul, Turkey

² Uskudar University, Psychology, Istanbul, Turkey

³ Uskudar University, Neurology, Istanbul, Turkey

* Corresponding author.

Introduction Especially the behavioral variant of Frontotemporal Dementia (FTD) may present with impulsivity, social disinhibition or depressive symptoms and these symptoms may create a clinical profile very similar to Bipolar Disorder (BD). In clinical practice, this similarity at symptom level creates substantial diagnostic confusion and often errors. As the treatment approach to the two disorders differ significantly, it is essential to make a reliable differential diagnosis.

Aim In this study we aimed to identify EEG differences between FTD and BD.

Methods For this aim we recruited 22 patients with FTD and 32 patients with BD. Patients in both groups were evaluated with a standardized neuropsychological battery and structural MRI. All patients were evaluated with resting EEG. There were no significant age and gender differences between groups.