

## Main Article

\*These authors contributed equally to this work.

Dr D Zhang takes responsibility for the integrity of the content of the paper

**Cite this article:** Yin S, Huang H, Sun P, Zhang D. Analysis of prognostic factors for vocal fold leukoplakia based on 344 cases at a two-year follow up. *J Laryngol Otol* 2023;**137**:1170–1175. <https://doi.org/10.1017/S0022215123000762>

Accepted: 25 April 2023  
First published online: 17 May 2023

### Keywords:

Lasers; infectious diseases; endoscopy

### Corresponding authors:

Dan Zhang;  
Email: [zhangdanent@126.com](mailto:zhangdanent@126.com)  
Peng Sun;  
Email: [entsunpeng@126.com](mailto:entsunpeng@126.com)

### Abstract

**Objective.** To evaluate risk factors for poor prognosis in vocal fold leukoplakia.

**Methods.** Clinical data were collected for 344 patients with vocal fold leukoplakia who received surgical treatment in our otolaryngology department from October 2010 to June 2019. Univariate and multivariate logistic regression analyses of the relevant factors were conducted.

**Results.** Among the 344 patients, 98 exhibited recurrence and 30 underwent a malignant change. Multivariate logistic regression analysis showed that size of the lesion ( $p = 0.03$ , odds ratio = 2.14), form of the lesion under white light ( $p < 0.001$ ), surgical method ( $p < 0.001$ , odds ratio = 0.28) and pathological type ( $p < 0.001$ ) were independent factors that affected the recurrence of vocal fold leukoplakia. In both univariate and multivariate analyses, the sole independent risk factor for malignant transformation of vocal fold leukoplakia was pathological type ( $p < 0.001$ ).

**Conclusion.** The outlook for vocal fold leukoplakia depends on several clinical factors, especially pathological type. The more severe the pathological type, the more likely it is to recur or become cancerous.

## Introduction

A white spot on the vocal fold mucosa is a common sign of vocal fold leukoplakia. It affects between 1 and 6 per cent of people.<sup>1</sup> The pathological types of vocal fold leukoplakia include hyperplasia, mild dysplasia, moderate dysplasia and severe dysplasia. Surgery is the preferred treatment option. However, post-operative recurrence and malignant transformation require additional attention. According to available data, the recurrence rate of vocal fold leukoplakia ranges between 9.5 and 46.4 per cent.<sup>2,3</sup>

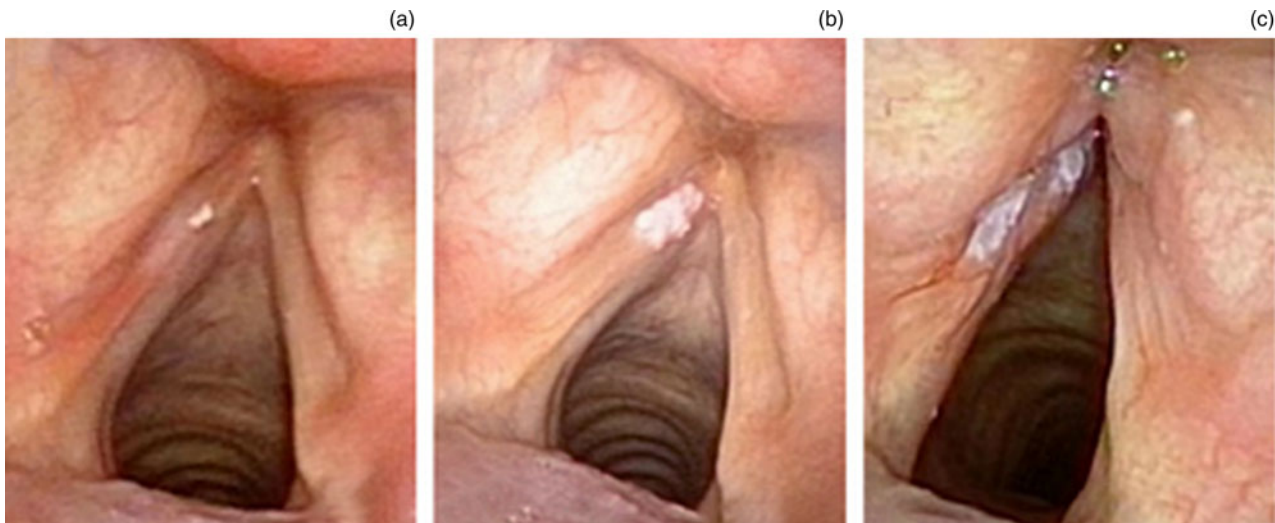
Vocal fold leukoplakia recurrence and malignant transformation risk factors are currently unclear. Some articles have suggested that the recurrence of vocal fold leukoplakia may be linked to sex, smoking and alcohol consumption. According to Fang *et al.*,<sup>4</sup> the number of peripheral inflammatory indicators is closely related to recurrence and malignant transformation of vocal fold leukoplakia. In addition, blood coagulation status is a sign of malignant transformation.<sup>5</sup> However, the impact of the above factors is debatable.

This study aimed to assess the recurrence and malignant transformation rates of vocal fold leukoplakia with a two-year follow up and to evaluate the impact of clinical factors, such as lifestyle, pathological categorisation, surgical techniques and morphological classification, on the outcomes of vocal fold leukoplakia. Thus, we conducted a retrospective analysis of 344 vocal fold leukoplakia patients.

## Materials and methods

We enrolled 344 vocal fold leukoplakia patients who received surgical treatment at The First Affiliated Hospital of Soochow University from October 2010 to June 2019. The selection criteria were as follows: (1) video endoscopic evidence of white mucosal lesions on the vocal folds; and (2) post-operative pathological typing revealing hyperplasia without dysplasia or hyperplasia with mild dysplasia, moderate dysplasia, or severe dysplasia. The following were the criteria for exclusion: (1) pathological typing revealing vocal nodules, polyps of the vocal fold, papillomas, laryngocarcinoma or a specific infection; (2) vocal fold leukoplakia surgical history; and (3) non-adherence to post-operative recommendations, such as quitting harmful behaviours. The ethics committee of The First Affiliated Hospital of Soochow University reviewed and approved this study.

We gathered data on the following variables: age, sex, disease course, smoking history, excessive alcohol use, site of the lesion, size of the lesion, anterior commissure involvement, morphological categorisation, surgical method, pathological type, neutrophil-to-lymphocyte ratio, monocyte-to-lymphocyte ratio and fibrinogen level. The requirements for excessive alcohol intake were 40 g per day for more than four times per week and over six months. Twenty packs per year for more than six months was the smoking criterion.



**Figure 1.** Morphological types of vocal fold leukoplakia according to Chen and colleagues' white-light 2019 classification system: (a) I, smooth and flat; (b) II, smooth and elevated; and (c) III, rough.<sup>7</sup>

The size of lesions was graded, according to Young *et al.*,<sup>6</sup> as either less than 50 per cent (the sum of all leukoplakia is less than half the length of one entire vocal fold) or 50 per cent or more (the sum of all leukoplakia is half or more than half the length of one entire vocal fold).

According to Chen and colleagues' white-light 2019 classification system,<sup>7</sup> there are three morphological types of vocal fold leukoplakia (Figure 1): I, smooth and flat; II, smooth and elevated; and III, rough. All blood samples were obtained 2 days prior to the operation.

Traditionally, lesions are often treated surgically with cold instruments. Recently, carbon dioxide (CO<sub>2</sub>) laser surgical procedures have dominated. Each patient underwent a video endoscopic examination every three months for the first six months and then every six months thereafter. The follow-up period lasted two years. It was recommended that patients abstain from smoking and drinking alcohol after surgery.

We conducted the statistical analysis using the SPSS version 22.0 program. The Kruskal-Wallis test was used to assess the disparities between the three groups. The count data are displayed as percentages, which were validated using Pearson's chi-square test. The skewed measurement data were expressed as median (lower quartile (Q1), upper quartile (Q3)) values, and analysed using the Mann-Whitney U test. Logistic regression analysis was used to evaluate the link between recurrence or malignant transformation and potential clinical variables. A two-sided  $p < 0.05$  was considered statistically significant.

## Results

Our study enrolled 344 individuals, including 334 males and 10 females. The median patient age was  $60 \pm 9.8$  years. The average disease course was  $7.2 \pm 4.9$  months. A total of 202 patients (58.7 per cent) were smokers, and 188 patients (54.7 per cent) consumed alcohol excessively. There were 148 patients (43.0 per cent) with bilateral lesions. Sixty-two patients (18 per cent) exhibited anterior commissure involvement. A total of 106 individuals (30.8 per cent) had a lesion size of 50 per cent or more (the sum of all leukoplakia was half or more than half the length of one entire vocal fold). Ninety-eight individuals exhibited recurrence (28.5 per cent), while 30 patients (8.7 per cent) had squamous cell carcinomas (demonstrating a malignant change). Recurrence was unrelated

to age, disease course, smoking, excessive alcohol consumption, anterior commissure involvement, neutrophil-to-lymphocyte ratio, monocyte-to-lymphocyte ratio or fibrinogen level. Table 1 summarises the clinical features.

The multivariate analysis showed that lesion size was an independent prognostic factor for vocal fold leukoplakia ( $p = 0.03$ , odds ratio = 2.14, 95 per cent confidence interval (CI) = 1.10–4.16; Table 2). Regarding Chen and colleagues' white-light classification, of the 344 patients, 269 were stage I, with 43 having recurrence, 58 were stage II, with 39 having recurrence (compared to stage I,  $p < 0.001$ , odds ratio = 14.15, 95 per cent CI = 6.68–29.94; Table 2), and 17 were stage III, with 16 having recurrence (compared to stage I,  $p < 0.001$ , odds ratio = 63.26, 95 per cent CI = 6.47–618.83; Table 2). Figure 2 shows Chen and colleagues' white-light classification system grading according to recurrence.

A total of 251 patients underwent CO<sub>2</sub> laser surgery, of whom 62 exhibited recurrence. The other 93 patients underwent traditional surgery with cold instruments, of whom 36 exhibited recurrence. In multivariate analysis, the surgical method was an independent prognostic factor for the recurrence of vocal fold leukoplakia ( $p < 0.001$ , odds ratio = 0.28, 95 per cent CI = 0.14–0.57; Table 2).

The pathological type was: hyperplasia without dysplasia in 188 patients, and 30 of these patients had recurrence; mild-moderate dysplasia in 126 patients, 43 of whom had recurrence (compared with the hyperplasia without dysplasia group,  $p < 0.001$ , odds ratio = 3.84, 95 per cent CI = 1.88–7.83; Table 2); and severe dysplasia in 30 patients, 25 of whom had recurrence (compared with the hyperplasia without dysplasia group,  $p < 0.001$ , odds ratio = 30.34, 95 per cent CI = 9.80–103.38; Table 2). The relationship between the pathological type and recurrence is shown in Figure 3. The univariate and multivariate analyses illustrated that pathological type was closely tied to recurrence as an independent risk factor ( $p < 0.001$ ; Tables 1 and 2).

When investigating malignant transformation, 1 patient with hyperplasia without dysplasia, and 12 patients with mild-moderate dysplasia, had malignant transformation (compared with the non-dysplasia group,  $p = 0.007$ , odds ratio = 16.99, 95 per cent CI = 2.16–133.86; Table 3), and 25 patients with severe dysplasia had malignant transformation (compared with the non-dysplasia group,  $p < 0.001$ , odds

**Table 1.** Relationship between clinical factors and poor prognosis of vocal fold leukoplakia

Variables	Value	Recurrence? (n)		p	Malignant transformation? (n)		p
		Yes	No		Yes	No	
Gender (n (%))				0.64			1.0
– Male	334 (97.1)	94	240		29	305	
– Female	10 (2.9)	4	6		1	9	
Age (years) (n (%))				0.11			0.38
– <60	164 (47.7)	40	124		12	152	
– ≥60	180 (52.3)	58	122		18	162	
Disease course (months) (n (%))				0.88			0.33
– ≤6	212 (61.6)	61	151		16	196	
– >6	132 (38.4)	37	95		14	118	
Smoker? (n (%))				0.003			0.004
– Yes	202 (58.7)	70	132		25	177	
– No	142 (41.3)	28	114		5	137	
Excessive consumption of alcohol? (n (%))				0.41			0.20
– Yes	188 (54.7)	57	131		13	175	
– No	156 (45.3)	41	115		17	139	
Side of lesion (n (%))				0.16			0.11
– Unilateral	196 (57.0)	50	146		13	183	
– Bilateral	148 (43.0)	48	100		17	131	
Size of lesion* (n (%))				0.01			0.47
– <50%	238 (69.2)	58	180		19	219	
– ≥50%	106 (30.8)	40	66		11	95	
Anterior commissure involved? (n (%))				<0.001			0.005
– Yes	62 (18.0)	29	33		11	51	
– No	282 (82.0)	69	213		19	263	
Chen <i>et al.</i> white-light classification (n (%))				<0.001			<0.001
– Stage I	269 (78.2)	43	226		17	252	
– Stage II	58 (16.9)	39	19		5	53	
– Stage III	17 (4.9)	16	1		8	9	
Operation type (n (%))				0.01			0.21
– CO <sub>2</sub> laser surgery	251 (73.0)	62	189		19	232	
– Traditional surgery	93 (27.0)	36	57		11	82	
NLR (median (Q1, Q3))	2.67 (1.81, 4.24)	98	246	0.98	30	314	0.90
MLR (median (Q1, Q3))	0.34 (0.23, 0.51)	98	246	0.53	30	314	0.13
Fibrinogen (median (Q1, Q3))	2.96 (2.46, 3.69)	98	246	0.35	30	314	0.95
Pathology (n (%))				<0.001			<0.001
– Hyperplasia with non-dysplasia	188 (54.7)	30	158		1	187	
– Mild–moderate dysplasia	126 (36.6)	43	83		12	114	
– Severe dysplasia	30 (8.7)	25	5		17	13	

\*The size of lesions was graded, according to Young *et al.*,<sup>6</sup> as either less than 50 per cent (the sum of all leukoplakia is less than half the length of one entire vocal fold) or 50 per cent or more (the sum of all leukoplakia is half or more than half the length of one entire vocal fold). CO<sub>2</sub> = carbon dioxide; NLR = neutrophil-to-lymphocyte ratio; Q1 = upper quartile; Q3 = lower quartile; MLR = monocyte-to-lymphocyte ratio

ratio = 160.98, 95 per cent CI = 19.17–1352; Table 3). Figure 4 depicts the pathological type according to malignant transformation. The univariate and multivariate analyses revealed that pathological type was the sole independent risk factor ( $p < 0.001$ ; Tables 1 and 3). Age, sex, disease course, smoking,

excessive alcohol consumption, size and location of the lesion, surgical method, white-light classification, anterior commissure involvement, inflammatory markers and fibrinogen level had no statistically significant association with vocal fold leukoplakia malignant transformation.

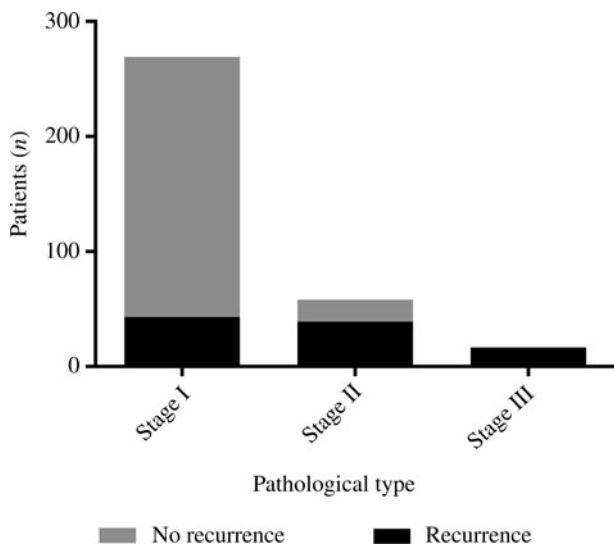
**Table 2.** Multivariate analysis of factors for recurrence of vocal fold leukoplakia

Factor	OR	95% CI	p
<b>Size of lesion*</b>			
- <50%	1		
- ≥50%	2.14	1.10–4.16	0.03
<b>Chen <i>et al.</i> white-light classification</b>			
- Stage I	1		
- Stage II	14.15 <sup>†</sup>	6.68–29.94 <sup>†</sup>	<0.001
- Stage III	63.26 <sup>‡</sup>	6.47–618.83 <sup>‡</sup>	<0.001
<b>Operation type</b>			
- Traditional surgery	1		
- CO <sub>2</sub> laser surgery	0.28	0.14–0.57	<0.001
<b>Pathology</b>			
- Hyperplasia with non-dysplasia	1		
- Mild–moderate dysplasia	3.84 <sup>**</sup>	1.88–7.83 <sup>**</sup>	<0.001
- Severe dysplasia	30.34 <sup>§</sup>	9.80–103.38 <sup>§</sup>	<0.001
<b>Smoker?</b>			
- No	1		
- Yes	1.84	0.95–3.57	0.07
<b>Anterior commissure involved?</b>			
- No	1		
- Yes	0.60	0.27–1.35	0.21

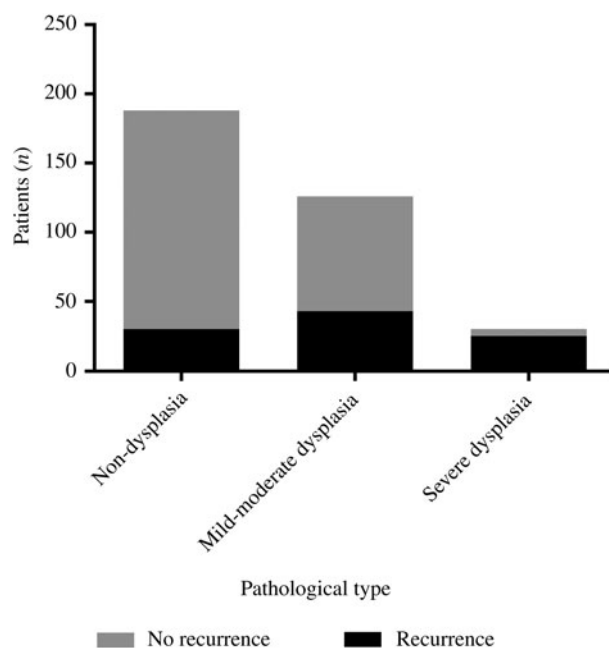
\*The size of lesions was graded, according to Young *et al.*,<sup>6</sup> as either less than 50 per cent (the sum of all leukoplakia is less than half the length of one entire vocal fold) or 50 per cent or more (the sum of all leukoplakia is half or more than half the length of one entire vocal fold). <sup>†</sup>Stage II versus stage I. <sup>‡</sup>Stage III versus stage I. <sup>\*\*</sup>Mild–moderate dysplasia versus hyperplasia with non-dysplasia. <sup>§</sup>Severe dysplasia versus hyperplasia with non-dysplasia. OR = odds ratio; CI = confidence interval; CO<sub>2</sub> = carbon dioxide

**Discussion**

The prognosis of vocal fold leukoplakia after surgery is of great concern. Published studies have focused on the roles of age, sex and lifestyle habits, such as alcohol consumption and smoking, as risk factors for vocal fold leukoplakia



**Figure 2.** White-light classification stage according to recurrence.



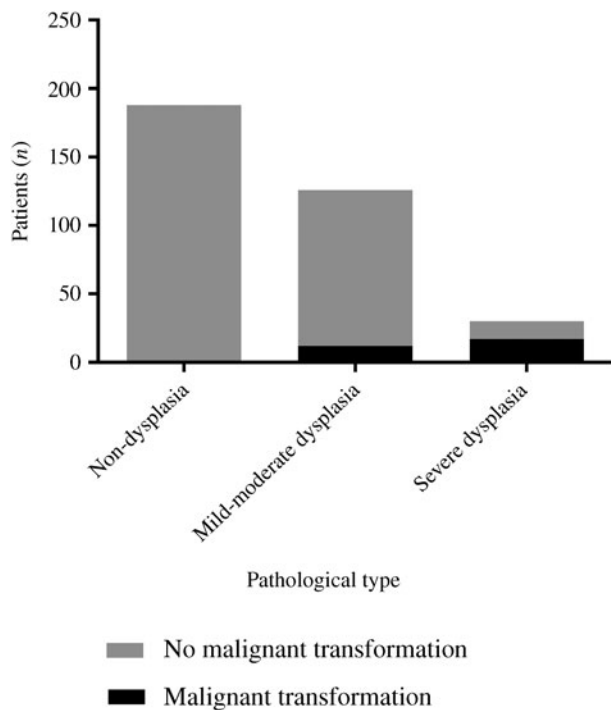
**Figure 3.** Pathological type according to recurrence.

recurrence.<sup>8–10</sup> In our study, sex, age, smoking and alcohol abuse were not associated with recurrence or malignant transformation. The strict control of alcohol and tobacco may have contributed to this result. One article has suggested that anterior commissure involvement increases the possibility of malignant transformation of vocal fold leukoplakia.<sup>11</sup> In contrast, our study found no difference, similar to the study by Fang *et al.*<sup>4</sup> Sufficient exposure and radical resection of the lesion may have contributed to this outcome. An increasing number of reports have indicated that fibrinogen is related to tumour

**Table 3.** Multivariate analysis of factors for malignant transformation of vocal fold leukoplakia

Factor	OR	95% CI	p
<b>Anterior commissure involved?</b>			
- No	1		
- Yes	0.78	0.25–2.43	0.67
<b>Chen <i>et al.</i> white-light classification</b>			
Stage I	1		
Stage II	0.83*	0.25–2.83*	0.77
Stage III	3.50 <sup>†</sup>	0.72–16.95 <sup>†</sup>	0.12
<b>Smoker?</b>			
- No	1		
- Yes	1.91	0.63–5.80	0.26
<b>Pathology</b>			
- Hyperplasia with non-dysplasia	1		
- Mild–moderate dysplasia	16.99 <sup>‡</sup>	2.16–133.86 <sup>‡</sup>	0.007
- Severe dysplasia	160.98 <sup>**</sup>	19.17–1352 <sup>**</sup>	<0.001

\*Stage II versus stage I. <sup>†</sup>Stage III versus stage I. <sup>‡</sup>Mild–moderate dysplasia versus hyperplasia with non-dysplasia. <sup>\*\*</sup>Severe dysplasia versus hyperplasia with non-dysplasia. OR = odds ratio; CI = confidence interval



**Figure 4.** Pathological type according to malignant transformation.

growth and metastasis.<sup>12,13</sup> Vocal fold leukoplakia is considered a pre-cancerous lesion, but in our study there was insufficient evidence to demonstrate this relationship.

Lesion size is a representative clinical characteristic of vocal fold leukoplakia. We found that the size of the lesion correlates with the recurrence of vocal fold leukoplakia. Lesion size graded as 50 per cent or more (whereby the sum of all leukoplakia is half or more than half the length of one entire vocal fold) had a higher recurrence risk than lesions graded as less than 50 per cent (in which the sum of all leukoplakia is less than half the length of one entire vocal fold) ( $p = 0.03$ , odds ratio = 2.14), similar to the findings of Lee *et al.*<sup>14</sup> Consequently, patients with larger lesions should receive greater attention.

Video endoscopy is an essential strategy for diagnosing vocal fold leukoplakia. According to Chen *et al.*,<sup>7</sup> there are three lesion types (I, smooth and flat; II, smooth and elevated; III, rough) that are related to the post-operative pathological type. Our study demonstrated that lesion form under white light is an independent factor influencing the outcome ( $p < 0.001$ ). Extended resection may be the key to reducing recurrence, especially for the rough type (type III). Narrow band imaging can also be used to differentiate between benign and malignant lesions.<sup>15</sup> However, we did not have access to the equipment for conducting narrow band imaging inspections of the patients treated early in this cohort. In a future study, we will combine white light with narrow band imaging to assess the lesions.

Surgery is a common treatment for vocal fold leukoplakia. We revealed that, compared with cold instruments, the CO<sub>2</sub> laser could effectively control the recurrence of vocal fold leukoplakia, in both the univariate analysis ( $p < 0.001$ ) and the multivariate analysis ( $p < 0.001$ , odds ratio = 0.28). The CO<sub>2</sub> laser has various advantages, including high brightness, a high energy conversion rate, less bleeding and greater precision; therefore, CO<sub>2</sub> laser surgery is an effective treatment.<sup>9,15–18</sup>

The pathological type of vocal fold leukoplakia varies from hyperplasia to severe dysplasia. In retrospective research,

Dispenza *et al.*<sup>19</sup> found that the recurrence rate of mild dysplasia treated using surgery with cold instruments was 13 per cent, and that of moderate dysplasia was 29 per cent. Gallo *et al.*<sup>20</sup> found that the recurrence rate after CO<sub>2</sub> surgery increased with increasing pathological heterogeneity, but moderate dysplasia had a higher malignant transformation rate than severe dysplasia (21.42 vs 9.37 per cent). In a meta-analysis, Weller *et al.*<sup>21</sup> observed that the recurrence and malignant transformation probability increased as the histopathological type increased. Consistent with Weller *et al.*,<sup>21</sup> our results revealed that a worse histopathological type was associated with a worse prognosis, including recurrence ( $p < 0.001$ ) and malignant transformation ( $p < 0.001$ ). In addition to resecting the lesion completely, individuals with worse histopathological types should receive greater attention during follow up.

There is a hypothesis that cancer originates from an inflammatory infection area.<sup>22</sup> Fang *et al.*<sup>4</sup> verified that inflammatory markers (neutrophil-to-lymphocyte ratio, monocyte-to-lymphocyte ratio, platelet-to-lymphocyte ratio), particularly neutrophil-to-lymphocyte ratio, are attributed to the development of vocal fold leukoplakia, which contradicts our findings. Notably, there was no multivariate analysis or other correlating variables in that study, which may have contributed to the disparity.

- Vocal fold leukoplakia may recur or become cancerous, but risk factors are currently unclear
- This study, based on both univariate analysis and multivariate analysis, investigated more factors than previous research
- The results show that lesion size, lesion form under white light, surgical method and pathological type are independent factors for vocal fold leukoplakia recurrence
- Pathological type is the sole independent risk factor for malignant transformation of vocal fold leukoplakia
- High-quality prospective studies with longer follow up are needed to further identify suspicious risk factors

The strength of our study is that we considered more factors than other studies. We used both univariate analysis and multivariate analysis to obtain convincing results. However, our study has some limitations, such as the need for geographical factors and the short follow-up period. We need high-quality prospective studies to identify suspicious risk factors in the future.

## Conclusion

This research reveals that the prognosis of vocal fold leukoplakia is closely related to lesion size, operation method, lesion form under white light and pathological type. The severity of the pathology increases the likelihood of recurrence and malignant transformation.

**Acknowledgements.** The work was supported by grants from the Suzhou Science and Technology Project (grant numbers: SKY2022140 and SYS2020116) and the Suzhou Clinical Medicine Center Project (grant number: Szlcyyzx202102).

**Competing interests.** None declared.

## References

- 1 Fang Y, Yang Y, Chen M, Chen J, He P, Cheng L *et al.* Correlating intraepithelial papillary capillary loops of vocal cord leukoplakia with histopathology. *Acta Otolaryngol* 2022;**142**:106–11

- 2 Minni A, Barbaro M, Rispoli G, Diaferia F, Bernardeschi D, Filipo R. Treatment with laser CO<sub>2</sub> cordectomy and clinical implications in management of mild and moderate laryngeal precancerosis. *Eur Arch Otorhinolaryngol* 2008;**265**:189–93
- 3 Sadri M, McMahan J, Parker A. Management of laryngeal dysplasia: a review. *Eur Arch Otorhinolaryngol* 2006;**263**:843–52
- 4 Fang Y, Yang Y, Chen M, He P, Cheng L, Chen J *et al.* Elevated peripheral inflammatory markers are related with the recurrence and canceration of vocal fold leukoplakia. *Eur Arch Otorhinolaryngol* 2019;**276**:2857–64
- 5 Boccaccio C, Medico E. Cancer and blood coagulation. *Cell Mol Life Sci* 2006;**63**:1024–7
- 6 Young CK, Lin WN, Lee LY, Lee LA, Hsin LJ, Liao CT *et al.* Laryngoscopic characteristics in vocal leukoplakia: inter-rater reliability and correlation with histology grading. *Laryngoscope* 2015;**125**:62–6
- 7 Chen M, Li C, Yang Y, Cheng L, Wu H. A morphological classification for vocal fold leukoplakia. *Braz J Otorhinolaryngol* 2019;**85**:588–96
- 8 Hong Y, Miao X, Zhang X, Ding F, Luo A, Guo Y *et al.* The role of P53 and MDM2 polymorphisms in the risk of esophageal squamous cell carcinoma. *Cancer Res* 2005;**65**:9582–7
- 9 Yang SW, Chao WC, Lee YS, Chang LC, Hsieh TY, Chen TA *et al.* Treatment outcome of vocal cord leukoplakia by transoral laser microsurgery. *Lasers Med Sci* 2017;**32**:19–27
- 10 Zhou J, Zhang D, Zhou L, Yang Y, Liu F, Tao L *et al.* Association of the recurrence and canceration rate of vocal leukoplakia with interleukin-10 promoter variants over a 2-year period. *Acta Otolaryngol* 2016;**136**:1147–53
- 11 Klimza H, Pietruszewska W, Rosiak O, Morawska J, Nogal P, Wierzbička M. Leukoplakia: an invasive cancer hidden within the vocal folds. A multivariate analysis of risk factors. *Front Oncol* 2021;**11**:772255
- 12 Wang M, Zhang G, Zhang Y, Cui X, Wang S, Gao S *et al.* Fibrinogen alpha chain knockout promotes tumor growth and metastasis through integrin-AKT signaling pathway in lung cancer. *Mol Cancer Res* 2020;**18**:943–54
- 13 Sharma BK, Mureb D, Murab S, Rosenfeldt L, Francisco B, Cantrell R *et al.* Fibrinogen activates focal adhesion kinase (FAK) promoting colorectal adenocarcinoma growth. *J Thromb Haemost* 2021;**19**:2480–94
- 14 Lee DH, Yoon TM, Lee JK, Lim SC. Predictive factors of recurrence and malignant transformation in vocal cord leukoplakia. *Eur Arch Otorhinolaryngol* 2015;**272**:1719–24
- 15 Zhang BG, Zhu JQ, Zhang W, Su FX, Wang GQ, Ni XG. Effect of a training course on the diagnosis of vocal fold leukoplakia by narrow-band imaging. *J Laryngol Otol* 2020;**134**:899–904
- 16 Zhang Y, Liang G, Sun N, Guan L, Meng Y, Zhao X *et al.* Comparison of CO<sub>2</sub> laser and conventional laryngomicrosurgery treatments of polyp and leukoplakia of the vocal fold. *Int J Clin Exp Med* 2015;**8**:18265–74
- 17 Del Mundo DAA, Morimoto K, Masuda K, Iwaki S, Furukawa T, Teshima M *et al.* Oncologic and functional outcomes of transoral CO<sub>2</sub> laser cordectomy for early glottic cancer. *Auris Nasus Larynx* 2020;**47**:276–81
- 18 Galletti B, Freni F, Cammaroto G, Catalano N, Gangemi G, Galletti F. Vocal outcome after CO<sub>2</sub> laser cordectomy performed on patients affected by early glottic carcinoma. *J Voice* 2012;**26**:801–5
- 19 Dispenza F, De Stefano A, Marchese D, Martines F, Dispenza C. Management of laryngeal precancerous lesions. *Auris Nasus Larynx* 2012;**39**:280–3
- 20 Gallo A, de Vincentiis M, Della Rocca C, Moi R, Simonelli M, Minni A *et al.* Evolution of precancerous laryngeal lesions: a clinicopathologic study with long-term follow-up on 259 patients. *Head Neck* 2001;**23**:42–7
- 21 Weller MD, Nankivell PC, McConkey C, Paleri V, Mehanna HM. The risk and interval to malignancy of patients with laryngeal dysplasia; a systematic review of case series and meta-analysis. *Clin Otolaryngol* 2010;**35**:364–72
- 22 Singh N, Baby D, Rajguru JP, Patil PB, Thakkannavar SS, Pujari VB. Inflammation and cancer. *Ann Afr Med* 2019;**18**:121–6