



Acta Genet Med Gemelloi 36:565-566 (1987)  
© 1987 by The Mendel Institute, Rome

## **Teratomorfism in the Urinary Tract of MZ Twins: Short Case Report**

**L. Gedda<sup>1</sup>, G. Brenci<sup>1</sup>, C. Laurenti<sup>2</sup>, C. De Dominicis<sup>2</sup>, D. Mattioli<sup>2</sup>**

*<sup>1</sup>The Gregor Mendel Institute of Medical Genetics and Twin Studies, Rome; and <sup>2</sup>Chair of Pediatric Urology, First University of Rome, Italy*

A case of 15-years old, Roman male twins affected by balanic hypospadias is reported. Previous corrective surgery had not been satisfactory, leaving both boys with a curvature of the last portion of the penis. Urographic examination, carried out upon presentation, revealed in both patients a mirror renal ectopy with fusion of the two kidneys. In both, the displaced malformed kidney is below the normally situated one. In depth examination shows: 1) that the malformation concerns not only external genitals but also internal urogenital organs because of the monolateral ectopy of the normal kidney and the malformation of the ectopic kidney in both twins; 2) that the twins are MZ and that their teratological specularity is biologically of interest.

Specularity, or mirror imaging, is a well known phenomenon in twins, particularly MZ twins. It may involve slight forms, such as handedness, or rare forms, such as those involving single organs, like the heart, which can be on the left side in one twin and on the right in the MZ cotwin. That must occur in the early embryogenetic stages, and various environmental and genetic factors may be involved. In particular, one can speculate that genetic variations in cell-adhesion molecules (CAM) and/or the late time of splitting of the conceptus to originate the two twins, may all play a role.

**Correspondence:** Prof. L. Gedda, The Mendel Institute, Piazza Galeno 5, 00161 Rome, Italy.

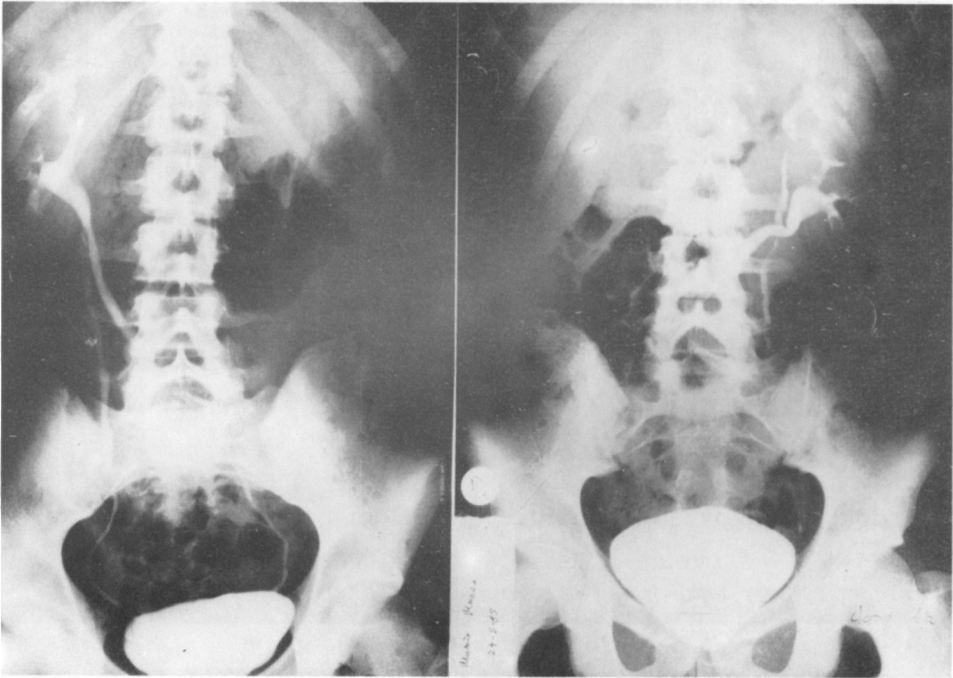


Figure. Monolateral ectopic kidney with mirror imaging in MZ twins.