

## SHORT NOTES

*Note Brevi | Communications Brèves | Kurze Mitteilungen*

---

### PARTIAL DELETION OF 1q, FOLLOWING A PERICENTRIC INVERSION, IN A BOY WITH MULTIPLE MINOR MORPHOLOGIC ANOMALIES AND MENTAL RETARDATION

G. SCHWANITZ, P. SCHMID, CH. HÄGELE, H. W. DAFFNER, K.-P. GROSSE

Department of Human Genetics and Anthropology, and Department of Pediatrics, University of Erlangen-Nürnberg, GFR

*In a 3<sup>3</sup>/<sub>4</sub> year old boy with mental and physical retardation, a chromosome analysis from lymphocyte cultures revealed a partial deletion of chromosome 1q following a pericentric inversion. The chromosomes of the parents were normal. The clinical picture of the patient included the following characteristics: prominent occiput, small chin, deep-seated and dysplastic ears, abnormal vortices of the hair, divided tip of the tongue, high palate, small finger and toe nails, inguinal hernia both sides, undescended but normal sized testes, hypotonic musculature and overextensible joints, retardation of ossification in the left hand by 6-12 months, slight osteoporosis, EQ~0.5.*

In a mentally retarded boy showing multiple minor morphological anomalies, a chromosome analysis from lymphocyte cultures revealed a complex structural abnormality with partial deletion of chromosome 1. Investigation of the parental chromosomes showed that the aberration had newly arisen in the child.

#### CASE REPORT

##### *Case History*

Volker M., born 23.6.72.

Mother aged 22 and father 24 years at the time of birth, the mother having had no previous pregnancies. Examination of the family history (pedigree analysis) revealed no further peculiarities. Delivery was one week before term, cephalic presentation.

Birth weight 3150 g, length 52 cm, head circumference 36 cm.

No special clinical treatment was necessary after birth.

##### *Developmental Anamnesis*

In the first year of life, the patient was strikingly susceptible to infections. The physical and mental development was delayed. He was sitting at 8½ months, walking at 17 months, dry by day from 3 years, and spoke his first word at 1 year 3 months. From 9 months on he received play therapy to encourage the development of fine motor movements.

##### *Clinical Findings at Age 3 Years 9 Months* (Figs. 1, 2)

Length 101.5 cm (50th perc.), weight 15.5 kg (75th perc.), head circumference 46.7 cm (below 3rd perc.). The child presents multiple minor malformations: slightly prominent occiput, small chin, deep-seated

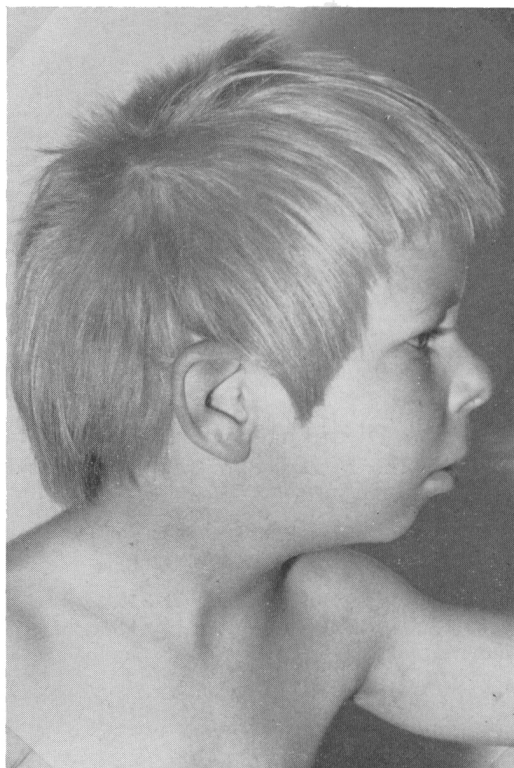
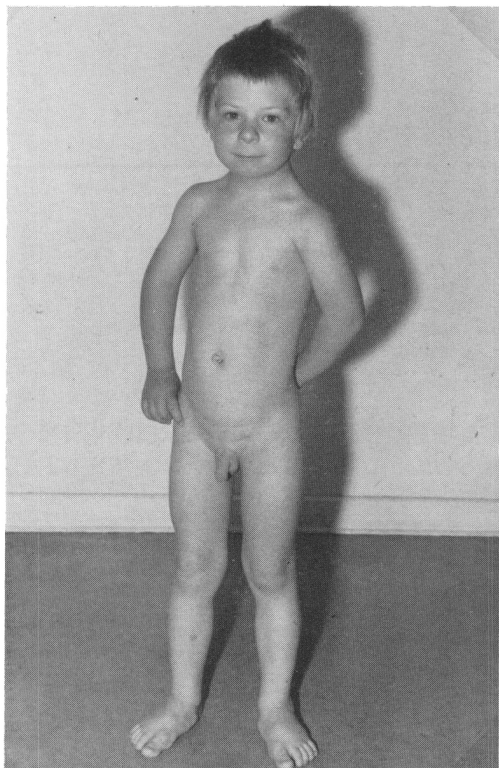

Fig. 1. Patient V. M. at age 3 years 9 months.

and dysplastic ears, abnormal vortices of the hair (see Fig. 2), divided tip of the tongue (frenulum has been earlier severed), high palate, the distal part of the sternum is slightly depressed, anomalous position of the sternum is slightly depressed, anomalous position of the toes (2nd toe crossed over the 3rd on both feet), pes plano valgus (for which the patient receives orthopedic treatment), strikingly small nails. The child recently has had an operation for inguinal hernia on both sides and to bring down the undescended, normal-sized testes. The penis is normal. The muscles are hypotonic, and the joints overextensible. There are no clinical hints for congenital heart disease.

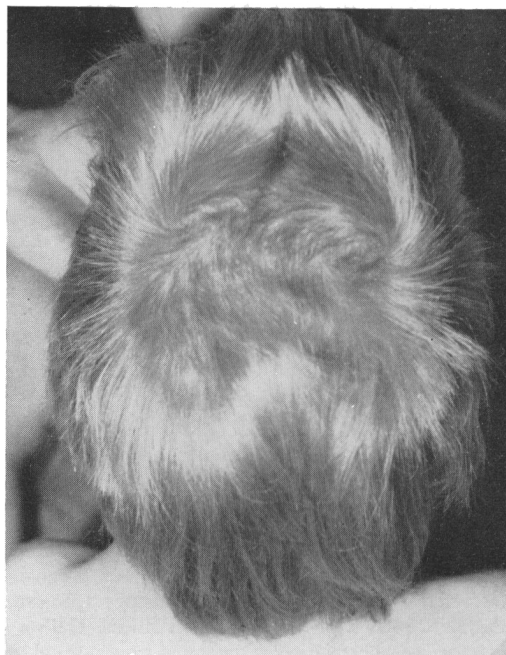*X-ray of thorax:* Heart is of normal size and shape, no skeletal abnormalities.

*X-ray of left hand:* Slight retardation of ossification by 6-12 months, slight osteoporosis.

#### *Development Status at 3 Years 9 Months*

The child can see and hear, says "Mama" and "Papa", but no other words. Development is estimated to be retarded by about  $1\frac{1}{4}$  years. EQ~0.5.

Fig. 2. Hair vortices of V.M.



### Cytogenetic Findings

Chromosome analysis was carried out using a Giemsa-banding technique derived from the method of Schnedl (1971). For one of the chromosomes No. 1, a pericentric inversion with accompanying loss of chromosome material was ascertained. Karyotype: 46,XY, inv. (1)(q25;p13)+del(q22—q25). Both parents showed normal karyotypes by Giemsa structure analysis (Fig. 3).




Fig. 3. Chromosomes No. 1 from different metaphases showing pericentric inversion and partial deletion of 1q.  
(46,XY, inv. (1)(q25;p13)+del(q22—q25).

### Dermatoglyphics

The pattern distribution of the child can be traced back to those of the parents.

### DISCUSSION

Nothing unusual was noticed at the birth of our patient, Volker M. The delay in mental and physical development only became obvious with increasing age. Although the child was continually receiving medical treatment, a diagnosis based on a chromosome analysis was not made until age 4 years, as the morphological symptoms were so inconspicuous. — In the last year

we have noticed this for four other children for whom slight morphological chromosome anomalies were established. For all these children the mental and physical retardation were the most obvious symptoms, and in each case the pediatrician had attempted to stimulate the development of the child by appropriate means.

It is therefore important that children who are mentally and physically retarded and who also present morphological anomalies, should be examined as early as possible to determine whether a chromosome disorder is responsible for the symptoms shown. Morphological anomalies in particular may be due to familial chromosome aberrations (especially reciprocal translocations), and the early diagnosis is therefore extremely important for the proper genetic advice of the affected families.

We have not been able to find in the literature any cases of patients having the same chromosome abnormality as that of Volker M. Turleau et al. (1974) reported a case of partial deletion 1q, where the patient showed major malformations, such as cleft lip and palate, congenital heart disease, anterior luxation of the knees, as well as other minor anomalies. Here, the deletion was larger than for our patient (q24 to q32), only the bands q24 and q25 being common to both deletions, the other missing bands being different. (Turleau C., Roubin M., Chavin-Colin F., Satge M., De Grouchy J. 1974. D el etion intercalaire de novo del(1)(q24q32, 1) chez un enfant malform e. Ann. G en et. 17: 291-294).