

CHAPTER TEN

THE BENNETT'S FRACTURE

OPINIONS vary considerably on the frequency of late symptoms following unsatisfactory reductions of a Bennett's fracture. Casualty officers do not usually find it an easy fracture to reduce, and because it is also quite a common injury, one can presume that numerous cases must be treated inexpertly every year ; but even so, the number of cases presenting themselves with symptoms of traumatic arthritis is remarkably few. However, this is no reason why a high standard of manipulative reduction should not be expected. The reduction of this fracture presents no great mechanical difficulty but it demands from the surgeon a fine sense of touch, and for this reason the injury could well be used as a ' passing-out ' test for the student of closed reduction.

ANATOMY OF THE FRACTURE

As its alternative name implies, the ' stave ' fracture is often sustained in a bout of fisticuffs. An ill-delivered blow transmits force in the line of the thumb while in flexion, thereby shearing off the anterior part of the base of the metacarpal, and so allowing the bone to escape from the joint in a dorsal direction. The volar ligament of the carpo-metacarpal joint remains intact and this is responsible for holding the wedge-shaped fragment of the metacarpal in its normal relation with the articular surface of the trapezium. The essential deformity of this injury is one of angulation with the concave aspect on the volar side ; the intact soft tissues which are to act as the ' hinge ' for the reduction are thus to be found on the volar aspect of the base of the metacarpal.

Mechanics of Reduction and Fixation

It is sometimes stated that unless traction is used the reduction of this fracture cannot be held with any degree of certainty ; according to this teaching, traction is usually applied with skin adhesive attached to an outrigger built into the plaster. But as pointed out on page 50, traction is indicated only in those fractures with no inherent stability against shortening ; the Bennett's fracture, on the contrary, is one which possesses considerable potential stability and, provided that it is treated with the carpo-metacarpal joint in full extension, the reduction can always be rendered stable.

If after the reduction of a Bennett's fracture the metacarpal of the thumb is fully extended so as to tighten the volar ligaments, it becomes impossible for dorsal

displacement to recur. If, now, the thumb in the reduced and extended position is slowly flexed, a critical point is reached beyond which further flexion will lever the base of the bone in a dorsal direction and so out of the joint.

Mechanical Analogy

The action of muscular tone on this reduction can be likened to the action of a crank and connecting-rod. There is a point in the motion of a crank known

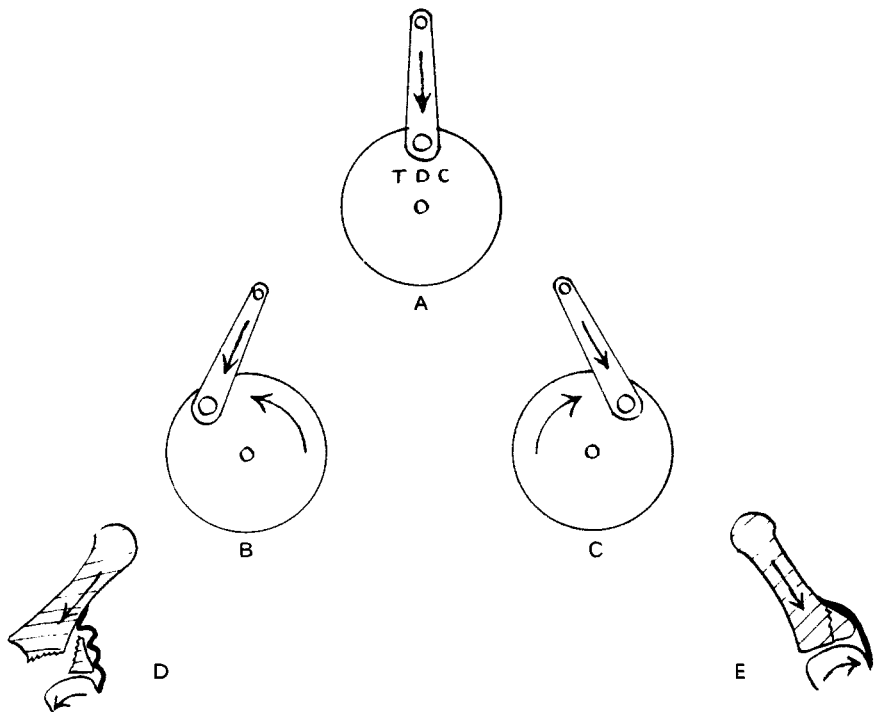


FIG. 115

Mechanical analogy in the reduction and fixation of a Bennett's fracture. The crank at 'top dead centre' A represents the position when the injury is treated by traction—the bone is in a state of uncertain equilibrium and floats without positive control. Without traction, the tone of the muscles can induce complete dislocation if the thumb is allowed to flex, B, D. Without traction, muscular tone will enhance the security of reduction if the thumb metacarpal is placed in full extension, C, E. In full extension muscular tone generates positive pressure against the undisplaced fragment.

as 'top dead centre'; on one side of this centre, pressure from the connecting-rod initiates movement in one direction of rotation (*e.g.*, towards stable reduction), while on the other side of this centre, motion will be initiated in the opposite direction (*e.g.*, towards unstable reduction) (Fig. 115). In the extended position of the metacarpal the tone of the muscles acting on the thumb will increase the stability of the reduction by thrusting the base of the bone deeper into the carpo-metacarpal socket.

THE BENNETT'S FRACTURE

The same mechanical analogy also explains why the use of traction is not an ideal arrangement for holding the reduction of a Bennett's fracture. Traction will merely 'float' the base of the metacarpal in the neutral position of instability (top dead centre), whereas what is desired is the forceful impaction of the metacarpal into its socket in the absence of traction by allowing rotation to occur towards the direction of stability (Fig. 115).

TECHNIQUE

This fracture-dislocation is particularly suited to reduction under local anaesthesia, which also allows the surgeon a second attempt under the same anaesthetic if he is not satisfied with his first.

The reduction of a Bennett's fracture tests the fineness of the surgeon's sense of touch; if approached with a heavy hand expecting a sharp click to indicate a successful reduction, it is probable that failure will result. It is no uncommon sight to see the beginner using violence on the reduction yet being uncertain that he has moved the fracture; this is for the simple reason that a complete reduction was probably produced by the first touch of his hand but, not understanding this, the fracture is enclosed in a defective plaster and when X-rayed is then found to be unreduced.

The sensation of reduction in a Bennett's fracture is sometimes so difficult to detect that **the reduction often demands assistance from the eye to confirm the fact that the base of the thumb is in fact slipping in and out of the metacarpo-carpal joint as the reduction forces are applied and removed.** Quite often the reduction can be done without anaesthesia once the surgeon has acquired the feel of it.

To reduce the injury the metacarpal must be extended by applying pressure to the volar aspect of the *head* of the metacarpal and at the same time pressing on the dorsal surface of the base of the metacarpal. It will be noticed that traction is not an essential part of this reduction though it assists in starting the movement. If the two forces are released and the metacarpal allowed to flex, the base of the thumb will be *seen* to ride up and out of joint. It is important to repeat this movement several times till this delicate sensation is clearly recognised by *touch*, for it is by this sensation alone that reduction can be detected when the plaster has been applied. Extension of the thumb should not be too extreme, because then another mechanism seems to force the dislocation out. The best position is just short of full, forced extension.

A pad of adhesive felt is now stuck over the base of the metacarpal and the sensation of reduction by touch is again rehearsed; the sensation will now be muffled and will need even more concentration to recognise than it did before.

A very wet plaster is now rapidly applied to hand and thumb, without any attempt to hold the reduced position. It is essential that the whole plaster should be completed while still quite soft; if this cannot be done with proprietary quick-setting plasters it is important to use an ordinary slow-setting bandage.

With the plaster soft, wet, and complete, the surgeon now feels again for the

sensation of reduction previously rehearsed ; having again recognised it through wet plaster, he holds on to the position of full extension of the thumb with

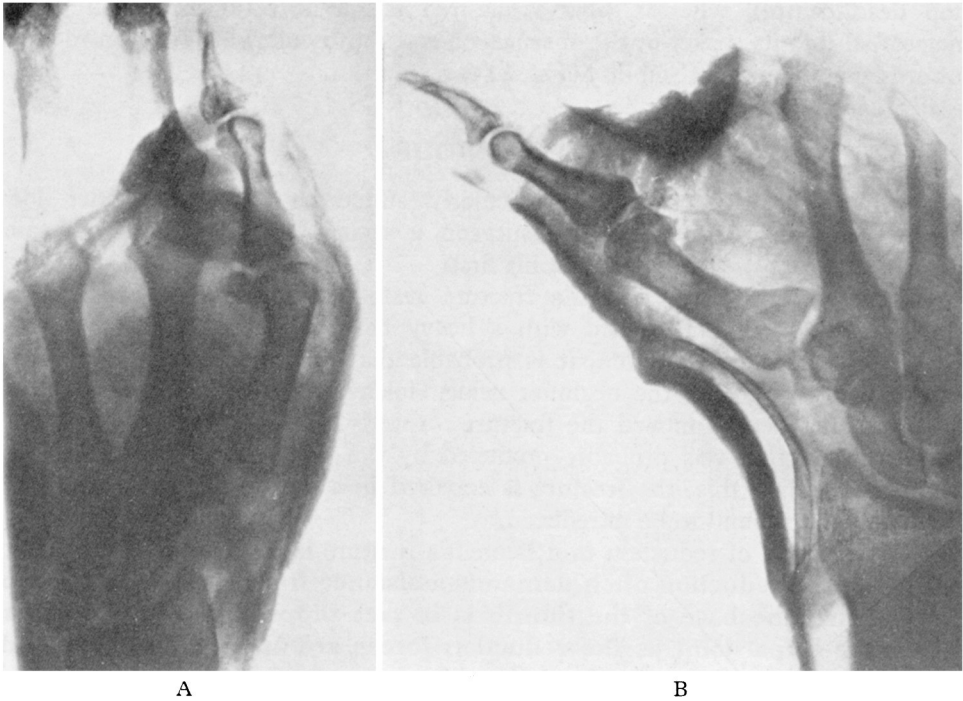


FIG. 116

A, Typical failure to reduce a Bennett's fracture because the thumb metacarpal is not fully extended. B, Complete reduction secured when the metacarpal is fully extended at the carpo-metacarpal joint.

local pressure over the dorsum of the base of the metacarpal until the plaster is firmly set (Fig. 116).

A Common Error

A common error in performing the reduction as described above is to apply force to the volar aspect of the proximal *phalanx* instead of to the volar aspect of the *head* of the metacarpal (Fig. 117, A). **This mistake results in the metacarpophalangeal joint being extended without of necessity extending the thumb metacarpal.** In other words, the distal joints of the thumb need not be extended provided that the metacarpal is fully extended ; in some people with 'double joints' extension of the distal part of the thumb is no indication of the position of the metacarpal (Fig. 118).

For this simple manipulative method to be successful it is essential that the injury should be recent. A delay of four or five days seriously prejudices the ability to hold the reduction and late slipping is very likely, and this is particularly the case if others have failed on previous attempts to reduce it.

THE BENNETT'S FRACTURE

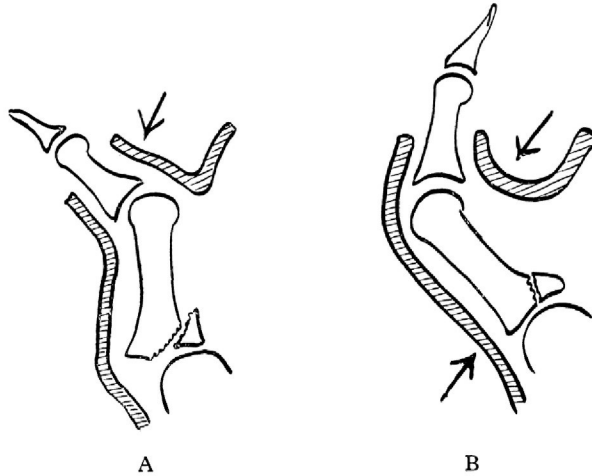
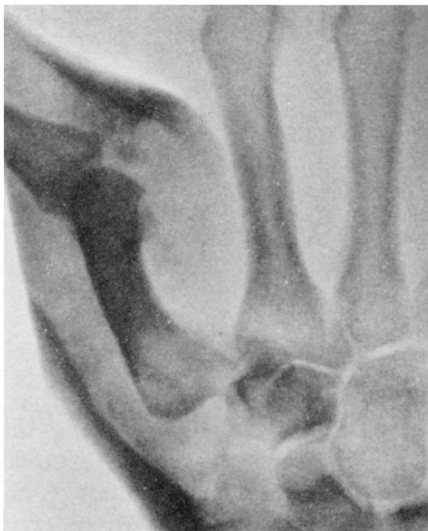
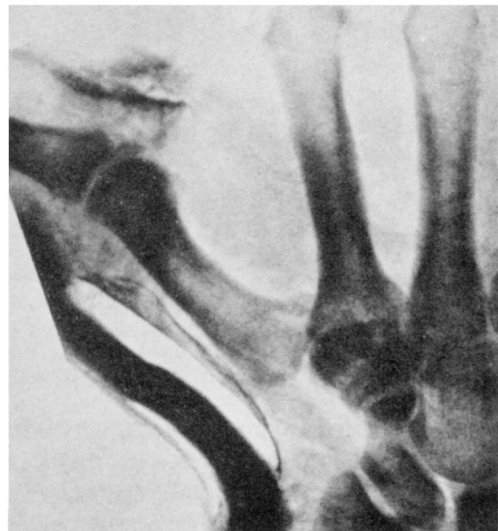
FIG. 117

Diagram illustrating a common error in the treatment of a Bennett's fracture. A, Extension of the metacarpal is not to be mistaken for extension at the metacarpo-phalangeal joint in persons with undue mobility at this site. B, The plaster must be modelled against the palmar aspect of the head of the metacarpal as well as over the dorsal aspect of the base of the metacarpal.



A



B

FIG. 118

- A, Faulty reduction of Bennett's fracture because metacarpal is not abducted though the metacarpo-phalangeal joint is extended.
- B, Reduction secured by abducting the thumb metacarpal (the original films show complete reduction though superficial inspection of this reproduction suggests that it is incomplete).

Though I have emphasised the importance of full extension of the metacarpal joint, there are some cases where extreme extension has the reverse effect. Extreme extension can force the base of the metacarpal into redislocation and a stable position of reduction may be felt just short of full extension.

Post-reduction

It is unnecessary to retain the plaster for more than four weeks. During the post-reduction period complaints of severe pain at the site of pressure over the

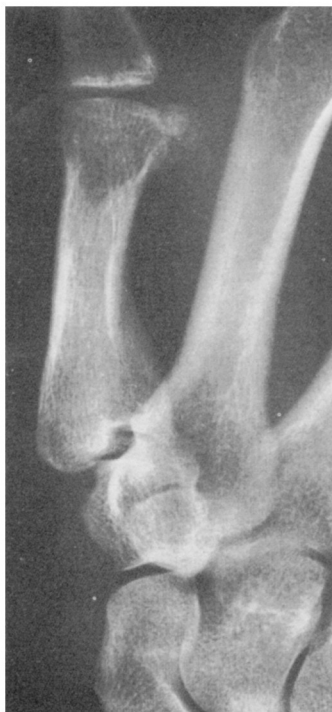

FIG. 119

Old unreduced Bennett's fracture
in labouring man which caused
no symptoms.

base of the thumb may indicate pressure necrosis of the underlying skin ; this symptom should be taken seriously lest the extensor tendon become exposed. It is never necessary to use very great pressure over the base of the thumb ; the **emphasis in the reduction should be in the extension of the carpo-metacarpal joint rather than on the local pressure over the joint.**

Unreduced Bennett's Fracture

If a Bennett's fracture is received late, or if it slips under treatment, there is no need to alarm the patient by a too pessimistic prognosis. All fixation should

THE BENNETT'S FRACTURE

be abolished and active movements and gripping exercises started. A function of 75 to 90 per cent. of normal is to be expected after one or two years. The development of crippling arthritis, though theoretically possible, is not, I believe, common even with gross displacement. Fig. 119 illustrates a case in a manual worker where there was no incapacity.

In patients with osteo-arthritis at the carpo-metacarpal joint of the thumb it is the exception rather than the rule to see a mal-reduced Bennett's fracture as the cause of the arthritis. Most cases of osteo-arthritis of this joint, which is a not uncommon condition, are either cases of primary osteo-arthritis or are of osteo-arthritis superimposed on rheumatoid arthritis, and are most commonly seen in women where the traumatic origin is not likely to be present.