

Review article

Effect of electroconvulsive therapy on hippocampal and amygdala volumes: systematic review and meta-analysis

Akihiro Takamiya, Jun Ku Chung, Kuo-ching Liang, Ariel Graff-Guerrero, Masaru Mimura and Taishiro Kishimoto

Background

Electroconvulsive therapy (ECT) is one of the most effective treatments for depression, although the underlying mechanisms remain unclear. Animal studies have shown that electroconvulsive shock induced neuroplastic changes in the hippocampus.

Aims

To summarise volumetric magnetic resonance imaging studies investigating the effects of ECT on limbic brain structures.

Method

A systematic review and meta-analysis was conducted to assess volumetric changes of each side of the hippocampus and amygdala before and after ECT. Standardised mean difference (SMD) was calculated.

Results

A total of 8 studies ($n = 193$) were selected for our analyses. Both right and left hippocampal and amygdala volumes increased after ECT. Meta-regression analyses revealed that age, percentage of those responding and percentage of those in remission were negatively associated with volume increases in the left hippocampus.

Conclusions

ECT increased brain volume in the limbic structures. The clinical relevance of volume increase needs further investigation.

Declaration of interest

None.

Copyright and usage

© The Royal College of Psychiatrists 2018

Electroconvulsive therapy (ECT) is one of the most effective and rapid antidepressant treatments for severe depression. Several meta-analyses have reported the superiority of ECT compared with pharmacotherapy for depression.^{1,2} In addition, ECT is more effective for patients with severe depressive symptoms resistant to multiple antidepressant medications.³ Clinically important aspects of ECT include more rapid alleviation of depressive symptoms and reduction in suicidality in comparison with pharmacotherapy.^{4–6} Despite the robust clinical efficacy of ECT its mechanisms of action remain elusive. Since the therapy was introduced to clinical practice in the 1930s a wealth of studies have provided several hypotheses, including monoamine neurotransmitter, neuroendocrine and anticonvulsant theories.⁷ In addition to these hypotheses, recent studies have focused on ECT-related neuroplastic effects, especially those occurring in the hippocampus. These effects have been derived from animal models. Particularly, a preclinical study showed that electroconvulsive shock (ECS), an animal model of ECT, induced neurogenesis in the dentate gyrus of the hippocampus.⁸ This finding has been replicated in several studies.^{9,10,11} Recently Nordanskog *et al* reported for the first time an ECT-related increase in hippocampal volume in depressed patients.¹² Furthermore, several magnetic resonance imaging (MRI) studies investigating the effects of ECT on brain structures have been published. However, most of the longitudinal ECT studies had small sample sizes, because patients who need ECT are often severely ill, in need of urgent treatment and have difficulty participating in such studies.¹³ Therefore, it is necessary to conduct systematic review and meta-analysis for ECT-related effects on brain structures. Currently there are several narrative or systematic reviews of neuroimaging studies related to ECT,^{13–16} but only one meta-analysis has been published so far, that by Wilkinson *et al* who reported that ECT increased bilateral hippocampal volume.¹⁷ Unfortunately, they did not include the largest study currently available,¹⁸ and focused only on hippocampal volume. Our aim was to

systematically review the MRI studies investigating structural changes due to ECT in patients with depression (major depression or bipolar affective disorder) and quantitatively analyse whether ECT induces hippocampal and other brain region structural changes, through a meta-analytic approach. An additional aim was to determine the effects of potential moderators, including clinical and demographic factors (e.g. age) and method of ECT (e.g. electrode placement), on the ECT-induced neuroplastic effects.

Method

We followed the Meta-analysis Of Observational Studies in Epidemiology (MOOSE) guidelines.¹⁹ The literature search, decisions on inclusion, data extraction and quality control were performed independently by two of the authors (A.T. and J.C.). Disagreements about study selection were solved by consensus; when this was not possible another author (T.K.) was contacted to resolve the disagreements. The protocol was not preregistered in any database.

Study selection

We searched Medline, EMBASE and PsycINFO (last search 2 July 2017) to identify eligible studies on changes in structural plasticity of hippocampi and other brain regions with ECT. The following keywords were used: (electroconvulsive OR ECT) AND ('magnetic resonance' OR MRI OR volume). In addition, the reference lists of the included articles were reviewed. The inclusion criteria were that studies were published in English, involved clinically depressed patients (with either major depressive disorder or bipolar affective disorder as defined by DSM or ICD criteria), had a longitudinal design with at least two scans (before and after ECT) and evaluated the effects of ECT on brain structures, including at least hippocampi, using MRI.

Data extraction

Changes in left and right hippocampal volume with ECT were designated as primary outcomes, and the secondary outcomes were changes in left and right amygdala volume with ECT. We extracted the means and standard deviations of hippocampal volumes as well as amygdala volumes. We also extracted clinical characteristics of the samples (number of participants, diagnosis, age, gender, medication status, clinical assessment, comparisons), ECT parameters (machine, electrode placement, treatment frequency, anaesthesia), MRI parameters (magnetic field strength, echo time, repetition time) and time from the last ECT to post-ECT assessment. When actual hippocampal volumes were not reported we extracted *t* or *P* values. If the same sample or partially overlapping samples were included in more than one report, data from the study with the largest number of participants were included. Where records did not provide sufficient information, corresponding authors were contacted and the required data were requested. If the authors did not respond or provide information that was essential for the meta-analysis, we excluded the study.

Quality assessment

All articles meeting the eligibility criteria were assessed for their quality by two investigators (A.T. and T.K.) using a modified version of the Newcastle–Ottawa Scale.²⁰ This is a quality assessment scale designed to evaluate and validate the quality of non-randomised studies. Our version of the scale was modified to assess longitudinal studies and to produce a comprehensive score, ranging from 0 (lowest quality) to 17 (highest quality), to be assigned to each included study. Total scores were determined by consensus between the two investigators.

Statistical analysis

The analyses were performed using Comprehensive Meta-Analysis version 3.0. The standardised mean difference (SMD) between pre- and post-ECT hippocampal volumes was calculated with 95% confidence intervals, using random effects models. Heterogeneity was reported using τ^2 , I^2 , *Q* and *P* values. To assess the robustness of the results, and to identify potential methodological biases and subpopulations in which outcomes differed, we also conducted a series of *a priori* defined subgroup/sensitivity and meta-regression analyses. In addition to meta-analysing hippocampal volume change in SMD across studies, we expressed the results in terms of raw volume change from studies that reported actual volume changes. We also conducted subgroup analysis and meta-regression analyses to identify potential treatment effect moderators such as medication status (medicated or unmedicated), age (mean age), gender (proportion of female participants), diagnosis (proportion with bipolar affective disorder), electrode placement (proportion of right unilateral placement) and clinical improvement (percentage reduction in depression severity score, percentage of those responding and percentage of those with remitted disorder). For electrode placement (bilateral or right unilateral) we explored the regional effect of direct electrical stimulation, i.e. whether right unilateral (RUL) electrical stimulation would lead to larger effects on right brain volume compared with effects on left brain volume. For medication status we categorised studies into ‘medicated’ or ‘unmedicated’. If a study included both medicated and unmedicated patients, we labelled the study as ‘medicated’. Egger’s regression test followed by Duval & Tweedie’s trim and fill method were used to assess publication bias.^{21,22}

Results

We identified 1331 research articles after duplicates were removed. Of these, 1253 studies were excluded at title and abstract level and 78 studies were selected as potentially relevant after initial evaluation. Full details of the search results, including the reasons for exclusion, are summarised in online Fig. DS1 available at <https://doi.org/10.1192/bjp.2017.11>. A total of 18 studies met the inclusion criteria for our systematic-review (online Table DS1).^{12,18,23–38} A total of 193 participants from eight independent studies were selected for the meta-analysis. Of these, five independent studies (*n* = 100) reported volume changes in amygdala. Details of the included studies for meta-analysis are presented in Table 1. The results of quality assessments for included studies using a modified Newcastle–Ottawa Scale are presented in online Table DS2.

Primary outcomes: hippocampal volume

There were significant hippocampal volume increases both on the right side (8 studies, *n* = 193, SMD = 0.51, 95% CI 0.27 to 0.76, *P* < 0.001; heterogeneity: τ^2 = 0.10, I^2 = 94%, *Q* = 122, *P* < 0.001) and on the left side (8 studies, *n* = 193, SMD = 0.381, 95% CI 0.18 to 0.58, *P* < 0.001; heterogeneity: τ^2 = 0.07, I^2 = 92%, *Q* = 86, *P* < 0.001) with ECT (Fig. 1). Sensitivity analyses of six studies (*n* = 152) reporting actual hippocampal volume also showed that the right hippocampus (SMD = 0.41, 95% CI 0.15 to 0.68, *P* = 0.002; heterogeneity: τ^2 = 0.10, I^2 = 96%, *Q* = 111, *P* < 0.001; differences in means = 200 mm³, 95% CI 87 to 312, *P* < 0.001; heterogeneity: τ^2 = 17837, I^2 = 94%, *Q* = 87, *P* < 0.001) and the left hippocampus (SMD = 0.30, 95% CI 0.09 to 0.51, *P* = 0.005; heterogeneity: τ^2 = 0.06, I^2 = 93%, *Q* = 75, *P* < 0.001; differences in means = 162 mm³, 95% CI 51 to 273, *P* = 0.004; heterogeneity: τ^2 = 17270, I^2 = 93%, *Q* = 69, *P* < 0.001) increased after ECT (online Fig. DS2).

Secondary outcomes: amygdala volume

There were significant amygdala volume increases both on the right side (5 studies, *n* = 100, SMD = 0.51, 95% CI 0.32 to 0.70, *P* < 0.001; heterogeneity: τ^2 = 0.03, I^2 = 73%, *Q* = 15, *P* = 0.006) and the left side (5 studies, *n* = 100, SMD = 0.54, 95% CI 0.28 to 0.80, *P* < 0.001; heterogeneity: τ^2 = 0.06, I^2 = 86%, *Q* = 28, *P* < 0.001) with ECT (Fig. 2). Sensitivity analyses of three studies (*n* = 59) reporting actual amygdala volume also showed that the right amygdala (SMD = 0.44, 95% CI 0.25 to 0.62, *P* < 0.001; heterogeneity: τ^2 = 0.02, I^2 = 78%, *Q* = 8.9, *P* = 0.012; differences in means = 110 mm³, 95% CI 66 to 156, *P* < 0.001; heterogeneity: τ^2 = 1220, I^2 = 78%, *Q* = 9.1, *P* = 0.011) and the left amygdala (SMD = 0.38, 95% CI 0.12 to 0.65, *P* = 0.005; heterogeneity: τ^2 = 0.05, I^2 = 90%, *Q* = 19, *P* < 0.001; differences in means = 124 mm³, 95% CI 101 to 147, *P* < 0.001; heterogeneity: τ^2 = 39, I^2 = 6.8%, *Q* = 2.2, *P* = 0.34) volumes both increased after ECT (online Fig. DS3).

Subgroup analyses and meta-regression

A subgroup analysis for the left hippocampal volume comparing the unmedicated and medicated cohorts revealed that left hippocampal volume increased in both subgroups (medicated cohort: 6 studies, *n* = 149, 77%, SMD = 0.25, 95% CI 0.09 to 0.41, *Z* = 3.11; unmedicated cohort: 2 studies, *n* = 44, 23%, SMD = 0.58, 95% CI 0.33 to 0.83, *Z* = 4.62); however, the increase was more evident in the unmedicated group (*P* = 0.027) (online Fig. DS4). There was no significant difference in a subgroup analysis for the right hippocampus (*P* = 0.086). In the meta-regression analyses age was shown to have a negative correlation with left hippocampal volume increase after ECT (8 studies, *n* = 193, coefficient = −0.017, 95% CI −0.030 to

Table 1 Overview of studies included in the meta-analysis

Study	Participants							ECT		MRI	
	<i>n</i>	Diagnosis	Age, years: mean (s.d.)	Female <i>n</i> (%)	Medication	Clinical assessment	Comparisons	Electrode placement	No. of sessions mean (s.d.)	Time from last ECT to post-ECT assessment	Analysis
Nordanskog et al (2010, 2014) ^{12,24}	12	6 MDD 6 BPD (4 BPD-II and 2 BPD-I)	40.3 (16.0)	10 (83)	Yes	MADRS 66% reduction 42% remitters, 67% responders	None	10 RUL 2 RUL +BL	10.2	<1 week	ROI manual tracing
Tendolkar et al (2013) ²⁵	15	15 MDD	52.8 (7.6)	8 (53)	No	HRSD 41% reduction 47% remitters, 53% responders	HC (1 scan)	15 BL	18 (median)	<1 week	ROI FreeSurfer
Abbott et al (2014) ²⁷	19 ^a	19 MDD ^a	65.5 (6.7)	10 (67)	Yes	HRSD-24 86% reduction	20 HC (1 scan)	17 RUL 2 BT	11 (2.7)	11 (s.d. = 8.4) days	ROI FreeSurfer
Ota et al (2015) ²⁹	15	15 MDD	52.1 (14.4)	6 (40)	Yes	HRSD-21 57% reduction	None	15 BL	9 (2.3)	9.0 (s.d. = 14.6) days	ROI FreeSurfer
Joshi et al (2016) ³²	43	35 MDD/7 BPD ^b	42 (13)	23 (53)	No	HRSD, MADRS, QIDS 56% (HRSD)/64% (MADRS) reduction 31% remitters, 68% responders	32 HC (2 scans)	32 RUL 2 BT 9 RUL +BL	11.5 (3.2)	<1 week	ROI FreeSurfer
Bouckaert et al (2016) ¹⁸	88	88 MDD	72.6 (8.5)	58 (66)	Yes	MADRS 65% reduction 68% remitters, 80% responders	None	61 RUL 27 RUL +BT	12 (5.6)	1 week	ROI manual tracing
Sartorius et al (2016) ³³	18	18 MDD	52 (14)	9 (50)	Yes	HRSD-21 67% reduction 56% remitters, 83% responders	36 HC (1 scan)	18 RUL	11.3 (4.8)	At least 2 days and <2 weeks after	ROI SPM12
Redlich et al (2016) ³⁴	23	23 MDD	45.7 (9.8)	14 (61)	Yes	HRSD 50% reduction 56% responders	24 patients (no ECT) 21 HC	20 RUL 3 RUL +BL	14.0 (3.8)	4.6 (s.d. = 4.9) days	ROI VBM8

BL, bilateral; BPD, bipolar disorder; BT, bitemporal; ECT, electroconvulsive therapy; HC, healthy control; HRSD, Hamilton Rating Scale for Depression; MADRS, Montgomery-Åsberg Depression Rating Scale; MDD, major depressive disorder; MRI, magnetic resonance imaging; QIDS, Quick Inventory of Depressive Symptomatology; ROI, region of interest; RUL, right unilateral; SPM, statistical parametric mapping; VBM, voxel-based morphometry.
a. Authors analysed only data from 15 responders.
b. Reported in the original article.

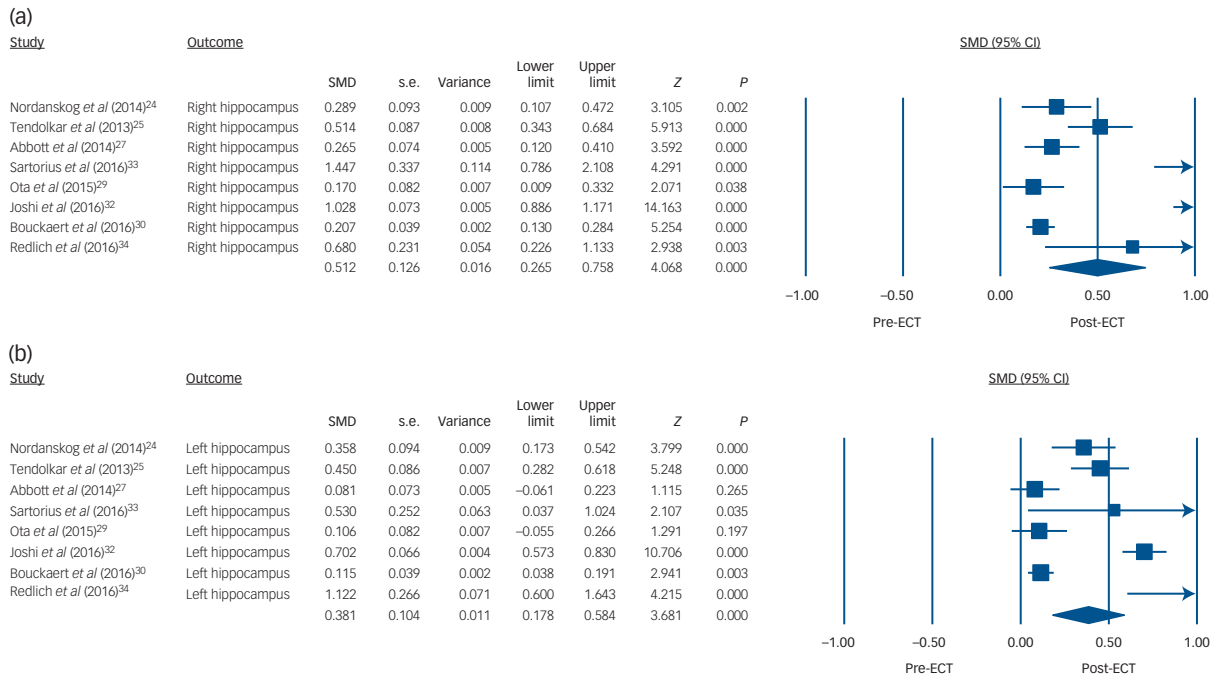


Fig. 1 Volume changes with electroconvulsive therapy (ECT) in (a) the right hippocampus and (b) the left hippocampus.

SMD, standardised mean difference.

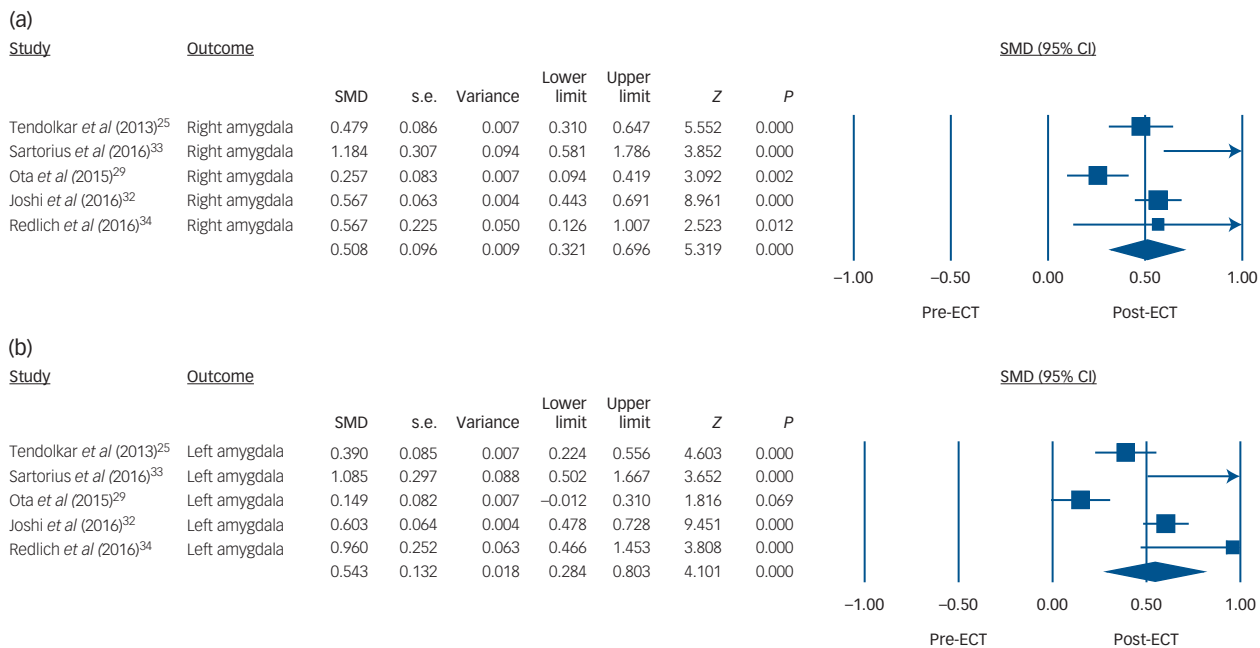


Fig. 2 Volume changes with electroconvulsive therapy (ECT) in (a) the right amygdala and (b) the left amygdala.

SMD, standardised mean difference.

-0.003, $P = 0.01$) (Fig. 3). Besides age, we also found a negative correlation between percentage of those who responded and percentage in remission with left hippocampal volume increase, although the number of studies for each meta-regression was small (7 studies, $n = 178$, coefficient = -0.013, 95% CI -0.025 to -0.0004, $P = 0.04$; 5 studies, $n = 140$, coefficient = -0.015, 95% CI -0.020 to -0.010, $P < 0.01$, respectively) (online Fig. DS5). Proportion of gender ($P = 0.88$), proportion of bipolar disorder ($P = 0.72$), proportion of

RUL electrode placement ($P = 0.50$) and percentage reduction in depression severity score ($P = 0.18$) did not correlate with left hippocampal volume increase. In the meta-regression analyses of right hippocampal volume, age ($P = 0.15$), gender proportion ($P = 0.42$), proportion with bipolar disorder ($P = 0.88$), proportion of RUL electrode placement ($P = 0.32$), percentage reduction in depression severity score ($P = 0.63$), percentage responding ($P = 0.62$) and percentage in remission ($P = 0.25$) did not correlate.

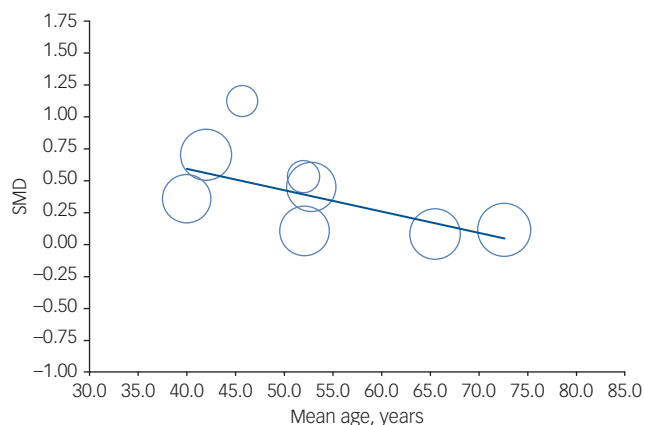


Fig. 3 Meta-regression result showing an association between age and volume changes with electroconvulsive therapy in the left hippocampus. Each study is represented as a circle, with larger circles symbolising greater sample sizes. The regression line is presented as a straight line. Note that studies including younger patients reported larger volume changes ($P = 0.01$).

SMD, standardised mean difference.

Publication bias

The funnel plots to assess publication bias were asymmetrical (online Fig. DS6). Subsequently we used the trim and fill method to adjust for potential publication bias; imputing missing studies did not change the result.

Discussion

To the best of our knowledge this is the most up-to-date and largest meta-analysis investigating ECT-related brain structural changes. The main results of our study indicate that ECT is associated with increased bilateral hippocampal and amygdala volumes in depressed patients; volume increase in hippocampi was more evident in the younger cohort. Moreover, hippocampal volume changes were shown to be negatively associated with clinical improvement. Our meta-analysis incorporated the largest study published on this topic,¹⁸ which had not been included in the earlier meta-analysis.¹⁷ Moreover, our meta-analysis further advanced the previous report by considering the amygdala in addition to the hippocampus, and analysed actual volume changes after obtaining data through contacting the authors. The question arises as to what underlying biological mechanisms account for hippocampal and amygdala volume changes with ECT. Although one might contend that volume changes with ECT are due to alterations in water content, there are several MRI and diffusion tensor imaging studies suggesting that oedema is unlikely to be the primary cause of the observed hippocampal volume changes with ECT.^{12,28,39,40} On the other hand, reported volume changes from T_1 -weighted imaging might be related to changes in blood flow because the T_1 relaxation times for arterial blood and grey matter are not clearly distinguishable.⁴¹ Neuroimaging measures themselves are difficult to relate to underlying biology, and animal studies at the cellular and molecular level can be more informative for explaining neuroimaging observations,⁴² as discussed below.

Hippocampal volume

One possible explanation for hippocampal volume increase with ECT is neurogenesis in the hippocampus. According to previous preclinical studies, ECS increased the number of neurons in the

rat dentate gyrus,^{8,9} and the increase was sustained for at least 3 months.⁸ Not only was ECS-induced neurogenesis observed in the dentate gyrus of monkey hippocampus, but it was also more substantial than in rodents.¹⁰ Interestingly, antidepressant medication also increased hippocampal neurons in both mice and non-human primates,^{43,44} and selective disruption of neurogenesis in the dentate gyrus by irradiation blocked the behavioural effects of chronic administration of antidepressants.^{43,44} Electroconvulsive shock is a more potent and faster stimulator of neurogenesis than antidepressants, and increases cell proliferation 2.5–4-fold compared with 1.5-fold by antidepressants;⁹ furthermore, it can start neurogenic action within 3 days compared with 2–3 weeks with antidepressants.¹¹ This evidence seems to be consistent with the clinical facts that ECT is a more potent and faster antidepressant treatment than medication. Hippocampal neurogenesis has also been observed in adult humans.^{45,46} Hence, increased neurogenesis in the dentate gyrus might contribute to the hippocampal volume increases with ECT.

Along with neurogenesis, gliogenesis has been considered to be an important factor in the pathophysiology of depression and the effects of antidepressant treatment, including ECT. Electroconvulsive shock induces a proliferation of glial progenitor cells (NG2-positive cells),^{47,48} increases the number of glial cells,⁴⁹ and changes the morphology and activation of glial cells.⁵⁰ Since NG2-positive cells can have an important role in regulating synaptic plasticity and function,⁵¹ ECS may cause changes in synaptic structures and functions. In addition to elevating synaptic proteins,⁵² ECS also increases the total synapse number and volume of the dentate gyrus,⁵³ and has promoted the maturation of dendritic spines.⁵⁴ These changes seem to be important not only for volume changes in the hippocampus but also for the remodelling of the neural circuit that mediates the therapeutic effect of ECT. Additionally, angiogenesis can be an alternative explanation for volume increase: ECS increased endothelial cell numbers by up to 30% and vessel length by 16% in the molecular layer of the dentate gyrus.⁵⁵ *In vivo* human positron emission tomography (PET) and single photon emission computed tomography (SPECT) studies have also revealed increased perfusion and metabolism in the medial temporal lobe including the parahippocampal gyrus and hippocampus after ECT,^{56–59} which may reflect angiogenesis.

Amygdala volume

We found that ECT increased bilateral amygdala volume. Human post-mortem studies have revealed reduction in the density of total glia and oligodendrocytes in the amygdala in patients with major depressive disorder.^{60,61} According to an animal study, ECS increased the number of glial cells (oligodendrocytes, and microglia in non-activated state) in rat amygdala.⁶² Histological studies also showed a reduction in glial cells in patients with depression in the subgenual cingulate cortex,⁶³ an area in which two studies in our systematic review reported volume increases with ECT.^{26,29} Although speculative, based on this evidence ECT seems able to reverse pathological changes in glial cells in patients with depression, and this may account for volume increase in the amygdala with ECT.

Age and hippocampal volume changes

Our meta-regression analysis showed that ECT-induced hippocampal volume changes were age-dependent; the volume increase was more prominent in younger patients than in older ones, although this was observed only in the left hippocampus. This finding may be underpinned by findings from the following studies. Animal studies showed that old mice expressed markers for neither neural stem cells nor neuronal progenitors;⁶⁴ ECS increased the volume of dentate gyrus in younger mice but did not significantly increase

its volume in 20-month-old mice.⁶⁴ In human studies, older adults showed low cell proliferation rate in dentate gyrus.⁶⁵ The reason why the age effect was only observed on the left side might be the sensitivity of left hemisphere to age-related volume changes.⁶⁶

Medication and volume changes

Our subgroup analysis revealed that unmedicated patients had greater hippocampal volume increases than medicated patients. Previous preclinical,^{43,44} post-mortem,⁶⁷ and human cross-sectional and longitudinal studies,^{68,69} have consistently reported that antidepressant usage was associated with increased hippocampal volume. Additionally, a recent well-designed longitudinal study confirmed antidepressant-induced hippocampal volume increase.⁷⁰ In addition, aripiprazole and lithium, which are used for augmentation therapy in depressed patients, increase hippocampal volume.^{71–73} Hence, it is plausible that the medicated patients had a larger hippocampal volume than the unmedicated group at baseline (pre-ECT) so the changes of hippocampal volume with ECT were relatively small.

Electrode placement

Based on our meta-regression analysis, bilateral and unilateral stimulation equally increased hippocampal volume. One may speculate that generalised seizure, not electrical stimulation, might be a major contributor to volume changes with ECT. In contrast, studies using RUL placement and studies analysing whole-brain samples have consistently reported that volume increases were restricted to the right side.^{26,30,33,34} We did not include data from these whole-brain analyses because our meta-analysis focused only on hippocampus and amygdala volumes.

Clinical relevance of hippocampal changes

We found a negative correlation between age and the left hippocampal volume increase. Moreover, we found a negative correlation between the percentages of those responding and those in remission with left hippocampal volume increase. However, it seems that the age effect is stronger than that of the responder and remission groups, as the correlation coefficient was numerically the highest for age among these factors. Clinical studies have shown that elderly depressed patients respond to ECT better and faster than younger patients.^{74–77} However, our results suggest that volume increase is smaller in older patient populations, who are more likely to have better response to ECT. The ECT-induced hippocampal volume changes were not associated with nor negatively correlated with clinical improvement. Therefore, the clinical relevance of hippocampal volume increase after ECT is still elusive. One possible explanation for the lack of association between hippocampal volume increase and clinical improvement could be that the brain's volume changes could be a byproduct of ECT treatment, and those not responding to ECT could show changes in hippocampal volume similar to those in the responder group.^{18,24,25,28} Another is that cognitive changes after ECT might be related to hippocampal volume changes. Unfortunately, we could not conduct a meta-regression to address the influence of cognition because only one study reported the relationship between hippocampal volume changes and changes in cognitive function.²⁴ In order to better describe the moderators for brain volume increase, large studies including a wide range of patient ages and/or clinical improvements are needed. In addition, our results seem to be inconsistent with previous studies showing that hippocampal volume was associated with clinical response to antidepressant medications.^{78,79} This inconsistency may lead to the notion that the hippocampal volume can be a biomarker for antidepressant medications but

not for ECT. Future studies should investigate not only hippocampal volume changes but also other brain regional changes with ECT.

Limitations

Several limitations of this study should be noted. First, the number of studies in the meta-analysis was relatively small, and we excluded about half of the studies from systematic review owing to a lack of statistical values, which may have caused bias. Second, significant heterogeneity was found. However, the results of all studies were similar (i.e. volume increase) and the trim and fill method showed that the results did not change even if there were unpublished negative studies. In addition, there was variability across studies in how to conduct ECT (electrode placement), how to assess depression severity and how to assess volume (manual tracing and automated segmentation). These heterogeneities might limit our meta-regression analyses. A global research collaboration collecting data from each individual patient and conducting mega-analyses could overcome these limitations.⁸⁰

Further research

Electroconvulsive therapy increased hippocampal and amygdala volumes. Hippocampal volume changes were negatively associated with age and clinical improvement. However, the clinical relevance of hippocampal volume increase with ECT needs further investigation using larger studies.

Akihiro Takamiya, MD, Department of Neuropsychiatry, Keio University School of Medicine and Komagino Hospital, Tokyo, Japan; **Jun Ku Chung**, HBSc, Institute of Medical Science, Faculty of Medicine, University of Toronto, and Multimodal Imaging Group Research Imaging Centre, Centre for Addiction and Mental Health, Toronto, Canada; **Kuo-ching Liang**, PhD, Department of Neuropsychiatry, Keio University School of Medicine, Tokyo, Japan; **Ariel Graff-Guerrero**, MD, PhD, Institute of Medical Science, Faculty of Medicine, University of Toronto, Multimodal Imaging Group Research Imaging Centre, Centre for Addiction and Mental Health, Toronto, Department of Psychiatry, University of Toronto, and Geriatric Mental Health Division, Centre for Addiction and Mental Health, Toronto, Canada; **Masaru Mimura**, MD, PhD, Department of Neuropsychiatry, Keio University School of Medicine, Tokyo, Japan; **Taishiro Kishimoto**, MD, PhD, Department of Neuropsychiatry, Keio University School of Medicine, Tokyo, Japan, and Hofstra Northwell School of Medicine, Hempstead, New York, USA

Correspondence: Dr Taishiro Kishimoto, Keio University School of Medicine, Department of Neuropsychiatry, 35 Shinanomachi, Shinjuku-ku, Tokyo 160-8582, Japan. Email: tkishimoto@keio.jp

First Received 6 July 2017, final revision 8 August 2017, accepted 17 August 2017

Supplementary material

Supplementary material is available online at <https://doi.org/10.1192/bjp.2017.11>

References

1. Carney S, Cowen P, Geddes J, Goodwin G, Rogers R, Dearnley K, et al. Efficacy and safety of electroconvulsive therapy in depressive disorders: a systematic review and meta-analysis. *Lancet* 2003; **361**: 799–808.
2. Pagnin D, de Queiroz V, Pini S, Cassano GB. Efficacy of ECT in depression: a meta-analytic review. *J ECT* 2004; **20**: 13–20.
3. Kellner CH, Kaicher DC, Banerjee H, Knapp RG, Shapiro RJ, Briggs MC, et al. Depression severity in electroconvulsive therapy (ECT) versus pharmacotherapy trials. *J ECT* 2015; **31**: 31–3.
4. Husain MM, Rush AJ, Fink M, Knapp R, Petrides G, Rummans T, et al. Speed of response and remission in major depressive disorder with acute electroconvulsive therapy (ECT): a consortium for research in ECT (CORE) report. *J Clin Psychiatry* 2004; **65**: 485–91.
5. Spaans HP, Sienaert P, Bouckaert F, van den Berg JF, Verwijk E, Kho KH, et al. Speed of remission in elderly patients with depression: electroconvulsive therapy v. medication. *Br J Psychiatry* 2015; **206**: 67–71.

6. Kellner CH, Fink M, Knapp R, Petrides G, Husain M, Rummanns T, et al. Relief of expressed suicidal intent by ECT: a consortium for research in ECT study. *Am J Psychiatry* 2005; **162**: 977–82.
7. Kellner CH, Greenberg RM, Murrrough JW, Bryson EO, Briggs MC, Pasculli RM. ECT in treatment-resistant depression. *Am J Psychiatry* 2012; **169**: 1238–44.
8. Madsen TM, Treschow A, Bengzon J, Bolwig TG, Lindvall O, Tingstrom A. Increased neurogenesis in a model of electroconvulsive therapy. *Biol Psychiatry* 2000; **47**: 1043–9.
9. Malberg JE, Eisch AJ, Nestler EJ, Duman RS. Chronic antidepressant treatment increases neurogenesis in adult rat hippocampus. *J Neurosci* 2000; **20**: 9104–10.
10. Perera TD, Coplan JD, Lisanby SH, Lipira CM, Arif M, Carpio C, et al. Antidepressant-induced neurogenesis in the hippocampus of adult nonhuman primates. *J Neurosci* 2007; **27**: 4894–901.
11. Warner-Schmidt JL, Duman RS. VEGF is an essential mediator of the neurogenic and behavioral actions of antidepressants. *Proc Natl Acad Sci USA* 2007; **104**: 4647–52.
12. Nordanskog P, Dahlstrand U, Larsson MR, Larsson EM, Knutsson L, Johanson A. Increase in hippocampal volume after electroconvulsive therapy in patients with depression: a volumetric magnetic resonance imaging study. *J ECT* 2010; **26**: 62–67.
13. Abbott CC, Gallegos P, Rediske N, Lemke NT, Quinn DK. A review of longitudinal electroconvulsive therapy: neuroimaging investigations. *J Geriatr Psychiatry Neurol* 2014; **27**: 33–46.
14. Bolwig TG. Neuroimaging and electroconvulsive therapy: a review. *J ECT* 2014; **30**: 138–42.
15. Zhuo C, Yu C. Functional neuroimaging changes subsequent to electroconvulsive therapy in unipolar depression: a review of the literature. *J ECT* 2014; **30**: 265–74.
16. Yronidi A, Peran P, Sauvaget A, Schmitt L, Arbus C. Structural–functional brain changes in depressed patients during and after electroconvulsive therapy. *Acta Neuropsychiatr* 2016; **23**: 1–12.
17. Wilkinson ST, Sanacora G, Bloch MH. Hippocampal volume changes following electroconvulsive therapy: a systematic review and meta-analysis. *Biol Psychiatry Cogn Neurosci Neuroimaging* 2017; **2**: 327–35.
18. Bouckaert F, Dols A, Emsell L, De Winter FL, Vansteelandt K, Claes L, et al. Relationship between hippocampal volume, serum BDNF and depression severity following electroconvulsive therapy in late-life depression. *Neuropsychopharmacol* 2016; **41**: 2741–8.
19. Stroup DF, Berlin JA, Morton SC, Olkin I, Williamson GD, Rennie D, et al. Meta-analysis of observational studies in epidemiology: a proposal for reporting. Meta-analysis Of Observational Studies in Epidemiology (MOOSE) group. *JAMA* 2000; **283**: 2008–12.
20. Wells G, Shea B, O'Connell D, Peterson J, Welch V, Losos M, et al. *The Newcastle-Ottawa Scale (NOS) for Assessing the Quality of Non-randomised Studies in Meta-analysis*. Ottawa Health Research Institute, 2004.
21. Egger M, Davey Smith G, Schneider M, Minder C. Bias in meta-analysis detected by a simple, graphical test. *BMJ* 1997; **315**: 629–34.
22. Duval S, Tweedie R. A nonparametric 'trim and fill' method of accounting for publication bias in meta-analysis. *J Am Stat Assoc* 2000; **95**: 89–98.
23. Coffey CE, Weiner RD, Djang WT, Figiel GS, Soady SAR, Patterson LJ, et al. Brain anatomic effects of electroconvulsive therapy. *Arch Gen Psychiatry* 1991; **48**: 1013–21.
24. Nordanskog P, Larsson MR, Larsson EM, Johanson A. Hippocampal volume in relation to clinical and cognitive outcome after electroconvulsive therapy in depression. *Acta Psychiatr Scand* 2014; **129**: 303–11.
25. Tendolkar I, van Beek M, van Oostrom I, Mulder M, Janzing J, Voshaar RO, et al. Electroconvulsive therapy increases hippocampal and amygdala volume in therapy refractory depression: a longitudinal pilot study. *Psychiatry Res Neuroimaging* 2013; **214**: 197–203.
26. Dukart J, Regen F, Kherif F, Colla M, Bajbouj M, Heuser I, et al. Electroconvulsive therapy-induced brain plasticity determines therapeutic outcome in mood disorders. *Proc Natl Acad Sci USA* 2014; **111**: 1156–61.
27. Abbott CC, Jones T, Lemke NT, Gallegos P, McClintock SM, Mayer AR, et al. Hippocampal structural and functional changes associated with electroconvulsive therapy response. *Transl Psychiatry* 2014; **4**: e483.
28. Jorgensen A, Magnusson P, Hanson LG, Kirkegaard T, Benveniste H, Lee H, et al. Regional brain volumes, diffusivity, and metabolite changes after electroconvulsive therapy for severe depression. *Acta Psychiatr Scand* 2016; **133**: 154–64.
29. Ota M, Noda T, Sato N, Okazaki M, Ishikawa M, Hattori K, et al. Effect of electroconvulsive therapy on gray matter volume in major depressive disorder. *J Affect Disord* 2015; **186**: 186–91.
30. Bouckaert F, De Winter FL, Emsell L, Dols A, Rhebergen D, Wampers M, et al. Grey matter volume increase following electroconvulsive therapy in patients with late life depression: a longitudinal MRI study. *J Psychiatry Neurosci* 2016; **41**: 105–14.
31. Nickl-Jockschat T, Palomero Gallagher N, Kumar V, Hoffstaedter F, Brugmann E, Habel U, et al. Are morphological changes necessary to mediate the therapeutic effects of electroconvulsive therapy? *Eur Arch Psychiatry Clin Neurosci* 2016; **266**: 261–7.
32. Joshi SH, Espinoza RT, Pirmia T, Shi J, Wang Y, Ayers B, et al. Structural plasticity of the hippocampus and amygdala induced by electroconvulsive therapy in major depression. *Biol Psychiatry* 2016; **79**: 282–92.
33. Sartorius A, Demirakca T, Bohringer A, Clemm von Hohenberg C, Aksay SS, Bumb JM, et al. Electroconvulsive therapy increases temporal gray matter volume and cortical thickness. *Eur Neuropsychopharmacol* 2016; **26**: 506–17.
34. Redlich R, Opel N, Grotegerd D, Dohm K, Zaremba D, Burger C, et al. Prediction of individual response to electroconvulsive therapy via machine learning on structural magnetic resonance imaging data. *JAMA Psychiatry* 2016; **73**: 557–64.
35. Wolf RC, Nolte HM, Hirjak D, Hofer S, Seidl U, Depping MS, et al. Structural network changes in patients with major depression and schizophrenia treated with electroconvulsive therapy. *Eur Neuropsychopharmacol* 2016; **26**: 1465–74.
36. Qiu H, Li X, Zhao W, Du L, Huang P, Fu Y, et al. Electroconvulsive therapy-induced brain structural and functional changes in major depressive disorders: a longitudinal study. *Med Sci Monit* 2016; **22**: 4577–86.
37. Thomann PA, Wolf RC, Nolte HM, Hirjak D, Hofer S, Seidl U, et al. Neuromodulation in response to electroconvulsive therapy in schizophrenia and major depression. *Brain Stimul* 2017; **10**: 637–44.
38. Cano M, Martinez-Zalacain I, Bernabeu-Sanz A, Contreras-Rodriguez O, Hernandez-Ribas R, Via E, et al. Brain volumetric and metabolic correlates of electroconvulsive therapy for treatment-resistant depression: a longitudinal neuroimaging study. *Transl Psychiatry* 2017; **7**: e1023.
39. Kunigiri G, Jayakumar PN, Janakiramaiah N, Gangadhar BN. MRI (2) relaxometry of brain regions and cognitive dysfunction following electroconvulsive therapy. *Indian J Psychiatry* 2007; **49**: 195–199.
40. Szabo K, Hirsch JG, Krause M, Ende G, Henn FA, Sartorius A, et al. Diffusion weighted MRI in the early phase after electroconvulsive therapy. *Neuro Res* 2007; **29**: 256–9.
41. Franklin TR, Wang Z, Shin J, Jagannathan K, Suh JJ, Detre JA, et al. A VBM study demonstrating 'apparent' effects of a single dose of medication on T1-weighted MRIs. *Brain Struct Funct* 2013; **218**: 97–104.
42. Zatorre RJ, Fields RD, Johansen-Berg H. Plasticity in gray and white: neuroimaging changes in brain structure during learning. *Nat Neurosci* 2012; **15**: 528–36.
43. Santarelli L, Saxe M, Gross C, Surget A, Battaglia F, Dulawa S, et al. Requirement of hippocampal effects of antidepressants. *Science* 2011; **305**: 805–9.
44. Perera TD, Dwork AJ, Keegan KA, Thirumangalakudi L, Lipira CM, Joyce N, et al. Necessity of hippocampal neurogenesis for the therapeutic action of antidepressants in adult nonhuman primates. *PLoS One* 2011; **6**: e176000.
45. Eriksson PS, Perfilieva E, Bjork Eriksson T, Alborn AM, Nordborg C, Peterson DA, et al. Neurogenesis in the adult human hippocampus. *Nat Med* 1998; **4**: 1313–7.
46. Spalding KL, Bergmann O, Alkass K, Bernard S, Salehpour M, Huttner HB, et al. Dynamics of hippocampal neurogenesis in adult humans. *Cell* 2013; **153**: 1219–27.
47. Wennstrom M, Hellsten J, Ekdahl CT, Tingstrom A. Electroconvulsive seizures induce proliferation of NG2-expressing glial cells in adult rat hippocampus. *Biol Psychiatry* 2003; **54**: 1015–24.
48. Wennstrom M, Hellsten J, Ekstrand J, Lindgren H, Tingstrom A. Corticosterone-induced inhibition of gliogenesis in rat hippocampus is counteracted by electroconvulsive seizures. *Biol Psychiatry* 2006; **59**: 178–86.
49. Kaae SS, Chen F, Wegener G, Madsen TM, Nyengaard JR. Quantitative hippocampal structural changes following electroconvulsive seizure treatment in a rat model of depression. *Synapse* 2012; **66**: 667–76.
50. Jansson L, Wennstrom M, Johanson A, Tingstrom A. Glial cell activation in response to electroconvulsive seizures. *Prog Neuropsychopharmacol Biol Psychiatry* 2009; **33**: 1119–28.
51. Dou CL, Levine JM. Inhibition of neurite growth by the NG2 chondroitin sulfate proteoglycan. *J Neurosci* 1994; **14**: 7616–28.
52. Bolwig TG, Jorgen OS. Synaptic proteins after electroconvulsive stimulation: reversibility and regional differences in the brain. *Acta Psychiatr Scand* 1980; **62**: 486–93.
53. Chen F, Madsen TM, Wegener G, Nyengaard JR. Repeated electroconvulsive seizures increase the total number of synapses in adult male rat hippocampus. *Eur Neuropsychopharmacol* 2009; **19**: 329–38.
54. Zhao C, Warner-Schmidt J, Duman RS, Gage FH. Electroconvulsive seizure promotes spine maturation in newborn dentate granule cells in adult rat. *Dev Neurobiol* 2012; **72**: 937–42.

55. Hellsten J, West MJ, Arvidsson A, Ekstrand J, Jansson L, Wennstrom M, et al. Electroconvulsive seizures induce angiogenesis in adult rat hippocampus. *Biol Psychiatry* 2005; **58**: 871–8.
56. Takano H, Motohashi N, Uema T, Ogawa K, Ohnishi T, Nishikawa M, et al. Changes in regional cerebral blood flow during acute electroconvulsive therapy in patients with depression: positron emission tomographic study. *Br J Psychiatry* 2007; **190**: 63–8.
57. McCormick LM, Boles Ponto LL, Pierson RK, Johnson HJ, Magnotta V, Brumm MC. Metabolic correlates of antidepressant and antipsychotic response in patients with psychotic depression undergoing electroconvulsive therapy. *J ECT* 2007; **23**: 265–73.
58. Suwa T, Namiki C, Takaya S, Oshita A, Ishizu K, Fukuyama H, et al. Corticolimbic balance shift of regional glucose metabolism in depressed patients treated with ECT. *J Affect Disord* 2012; **136**: 1039–46.
59. Reininghaus EZ, Reininghaus B, Ille R, Fitz W, Lassnig RM, Ebner C, et al. Clinical effects of electroconvulsive therapy in severe depression and concomitant changes in cerebral glucose metabolism – an exploratory study. *J Affect Disord* 2012; **146**: 290–4.
60. Bowley MP, Drevets WC, Ongur D, Price JL. Low glial numbers in the amygdala in major depressive disorder. *Biol Psychiatry* 2002; **52**: 404–12.
61. Hamidi M, Drevets WC, Price JL. Glial reduction in amygdala in major depressive disorder is due to oligodendrocytes. *Biol Psychiatry* 2004; **55**: 563–9.
62. Wennström M, Hellsten J, Tingstrom A. Electroconvulsive seizures induce proliferation of NG2-expressing glial cells in adult rat amygdala. *Biol Psychiatry* 2004; **55**: 464–71.
63. Ongur D, Drevets WC, Price JL. Glial reduction in the subgenual prefrontal cortex in mood disorders. *Proc Natl Acad Sci USA* 1998; **95**: 13290–5.
64. Rotheneichner P, Lange S, O'Sullivan A, Marschallinger J, Zaunmair P, Geretsegger C, et al. Hippocampal neurogenesis and antidepressive therapy: shocking relations. *Neural Plast* 2014; **2014**: 723915.
65. Czeh B, Lucassen PJ. What causes the hippocampal volume decrease in depression? Are neurogenesis, glial changes and apoptosis implicated? *Eur Arch Psychiatry Clin Neurosci* 2007; **257**: 250–60.
66. Shan ZY, Liu JZ, Sahgal V, Wang B, Yue GH. Selective atrophy of left hemisphere and frontal lobe of the brain in old men. *J Gerontol A Biol Sci Med Sci* 2005; **60**: 165–74.
67. Boldrini M, Santiago AN, Hen R, Dwork AJ, Rosoklija GB, Tamir H, et al. Hippocampal granule neuron number and dentate gyrus volume in antidepressant-treated and untreated major depression. *Neuropsychopharmacology* 2013; **38**: 1068–77.
68. Malykhin NV, Carter R, Seres P, Coupland NJ. Structural changes in the hippocampus in major depressive disorder: contributions of disease and treatment. *J Psychiatry Neurosci* 2010; **35**: 337–43.
69. Frodl T, Jager M, Smajstrlova I, Born C, Bottlender R, Palladino T, et al. Effect of hippocampal and amygdala volumes on clinical outcomes in major depression: a 3-year prospective magnetic resonance imaging study. *J Psychiatry Neurosci* 2008; **33**: 423–30.
70. Arnone D, McKie S, Elliott R, Juhasz G, Thomas EJ, Downey D, et al. State-dependent changes in hippocampal grey matter in depression. *Mol Psychiatry* 2013; **18**: 1265–72.
71. Bodnar M, Malla AK, Makowski C, Chakravarty MM, Joober R, Lepage M. The effect of second-generation antipsychotics on hippocampal volume in first episode of psychosis: longitudinal study. *BJPsych Open* 2016; **2**: 139–46.
72. Germana C, Kempton MJ, Sarnicola A, Christodoulou T, Haldane M, Hadjulis M, et al. The effects of lithium and anticonvulsants on brain structure in bipolar disorder. *Acta Psychiatr Scand* 2010; **122**: 481–7.
73. Hajek T, Kopecek M, Hoschl C, Alda M. Smaller hippocampal volumes in patients with bipolar disorder are masked by exposure to lithium: a meta-analysis. *J Psychiatry Neurosci* 2012; **37**: 333–43.
74. O'Connor MK, Knapp R, Husain M, Rummans T, Petrides G, Smith G, et al. The influence of age on the response of major depression to electroconvulsive therapy: a C.O.R.E. Report. *Am J Geriatr Psychiatry* 2001; **9**: 382–90.
75. Nordenskjold A, von Knorring L, Engstrom I. Predictors of the short-term responder rate of electroconvulsive therapy in depressive disorders – a population based study. *BMC Psychiatry* 2012; **12**: 115.
76. Rhebergen D, Huisman A, Bouckaert F, Kho K, Kok R, Sienaert P, et al. Older age is associated with rapid remission of depression after electroconvulsive therapy: a latent class growth analysis. *Am J Geriatr Psychiatry* 2015; **23**: 274–82.
77. Kellner CH, Husain MM, Knapp RG, McCall WV, Petrides G, Rudorfer MV, et al. Right unilateral ultrabrief pulse ECT in geriatric depression: Phase 1 of the PRIDE study. *Am J Psychiatry* 2016; **173**: 1101–9.
78. Phillips JL, Batten LA, Tremblay P, Aldosary F, Blier P. A prospective, longitudinal study of the effect of remission on cortical thickness and hippocampal volume in patients with treatment-resistant depression. *Int J Neuropsychopharmacol* 2015; **18**: 1–9.
79. Colle R, Cury C, Chupin M, Deflesselle E, Hardy P, Nasser G, et al. Hippocampal volume predicts antidepressant efficacy in depressed patients without incomplete hippocampal inversion. *Neuroimage Clin* 2016; **12**: 949–55.
80. Oltedal L, Bartsch H, Sorhaug OJE, Kessler U, Abbott C, Dols A, et al. The Global ECT-MRI Research Collaboration (GEMRIC): establishing a multi-site investigation of the neural mechanisms underlying response to electroconvulsive therapy. *Neuroimage Clin* 2017; **14**: 422–32.

