

Fukuyama Type Congenital Muscular Dystrophy in a Turkish Child

Haluk Topaloğlu, Yavuz Renda, Safiye Gögüs, Sibel Benli, Gülay Nurlu and Mustafa Yildirim

ABSTRACT: Congenital muscular dystrophy (CMD) is a heterogeneous group of disorders which is associated with more or less degrees of cerebral involvement. There are four separate entities within CMD nosology. Among these Fukuyama's CMD (FCMD) is highly prevalent in Japan, whereas the classic form with normal or subnormal intelligence, also known as the occidental type, covers the vast majority of cases in the West. We report a case of FCMD seen in a Turkish child.

RÉSUMÉ: *Dystrophie musculaire congénitale de type Fukuyama chez un enfant Turque* La dystrophie musculaire congénitale (DMC) est un groupe hétérogène de maladies qui sont associées à différents degrés d'atteinte cérébrale. La DMC en tant qu'entité nosologique comprend quatre entités séparées. Parmi celles-ci, la DMC de Fukuyama (DMCF) a une prévalence élevée au Japon, alors que la forme classique avec une intelligence normale ou subnormale, aussi connue comme étant la forme occidentale, couvre la grande majorité des cas identifiés dans l'hémisphère ouest. Nous rapportons un cas de DMCF observée chez un enfant turque.

Can. J. Neurol. Sci. 1990; 17:149-150

Congenital muscular dystrophy (CMD) is a unique type of muscular disorder characterized by probable autosomal recessive inheritance, early onset hypotonia, involvement of facial muscles, joint contracture and slowly progressive course. Mentality may or may not be involved. Clinical presentations are rather heterogeneous and several types of CMD have been described. Basically there are four major sub-groups within CMD nosology: classic occidental type CMD with normal or subnormal intelligence; Fukuyama's CMD (FCMD); the cerebro-ocular dysplasia-muscular dystrophy syndrome (COD-MD); and some forms which do not fit in any category.¹⁻⁵ Among these FCMD is distinguished by developmental central nervous system (CNS) abnormalities, severe mental retardation and related symptomatology.⁶ In Japan this seems to be one of the frequent causes of the floppy infant syndrome, whereas outside Japan the association of CMD with CNS involvement is very rare, and only a few cases have been reported.^{7,8} We report a case of FCMD observed in a 27 month old Turkish child.

CASE REPORT

A 27 month old female child coming from the northern part of Turkey was referred to our clinic for evaluation of floppiness and developmental delay since birth. She was born of non-consanguineous parents as the second child. An 8 year old male sibling is normal. There was no family history of muscle disease or mental retardation. Fetal movements were noted to be decreased in utero, but pregnancy was uneventful otherwise. Delivery was at term and was spontaneous vaginal. The birth weight was 3.1 kg. The neonatal period was complicated with some feeding difficulties. Apparent floppiness was noted in the nursery. Her developmental milestones were delayed; she held her head

up at 20 months, sat without support at 26 months, smiled and knew her mother at 10 months, and barely uttered single phrases at 26 months. She had experienced two generalized afebrile seizures at 8 and 10 months.

Physical examination on admission showed evidence of undernourishment and marked hypotonia. Her head circumference, length and weight were below the third percentile. There were no dysmorphic features. Her facial appearance was mask like. Ocular movements were full and fundi were normal. Findings from examination of the chest and abdomen were unremarkable. Her EKG and cardiac echogram were normal. An EEG recording had scattered sharp transients from both hemispheres and diffusely slow background activity. EMG showed generalized low voltages without denervation. A CT scan of the head revealed cortical atrophy and white matter hyperlucency around the frontal and occipital ventricular horns (Figure 1). Biopsy from the gastrocnemius showed variation in fibre size and moderate fibrous tissue infiltration along with mild fat replacement and scattered fibre necrosis (Figure 2). There was no evidence of type grouping. On the basis of these findings we made a diagnosis of FCMD.

DISCUSSION

The etiology of FCMD remains unclear. A genetic factor may be important,⁹ but some authors have suggested an infectious etiology.^{10,11} FCMD has even been reported in Japanese infants conceived and born outside Japan.¹² The major changes in the CNS represent an arrest in the migration and differentiation of neurons early in the course of fetal development. This defect is expressed as microcephaly, polymicrogyria, pachygyria and heterotopias.¹³ Other abnormalities include fusion of the frontal lobes, hydrocephalus, periventricular cysts, optic nerve atrophy, hypoplasia of pyramidal tracts, reduction in anterior

From the Departments of Pediatric Neurology and Pathology, Hacettepe University Children's Hospital, Ankara, Turkey

Received July 6, 1989. Accepted in final form December 11, 1989

Reprint requests to: Dr. Haluk Topaloglu, Department of Pediatric Neurology, Hacettepe Children's Hospital, Ankara, Turkey

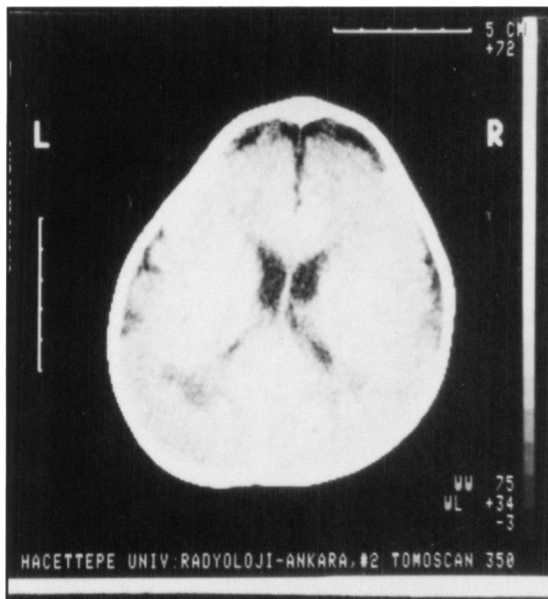


Figure 1 — CT scan. Cortical atrophy, mild white matter hyperlucency around frontal and occipital ventricular horns.

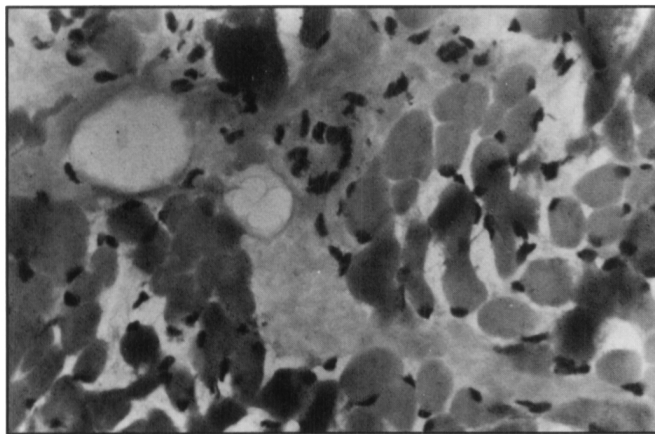


Figure 2 — Muscle biopsy. Variation in fibre size, moderate fibrosis, mild adiposis, scattered degenerating fibres. HE X 400.

horn cell in numbers and inflammatory changes in the leptomeninges.⁶ The important hallmarks in FCMD are early onset hypotonia, facial muscle involvement, severe mental retardation along with congenital degenerative changes in muscle and highly elevated CK levels. Our case fits into this group with its unique features, though we lack radio-anatomical correlation of the CNS.

The most striking CT changes, i.e. prominent white matter hyperlucency, is usually seen around one year of age in FCMD. As the child grows older, hyperlucency diminishes, and is replaced by normalization.¹⁴ Delayed myelination processing is thought to be the responsible mechanism. CT findings in our patient reveal only a limited extent of hypodensity in the white matter; this is probably because she has already passed one year of age.

The abundance of FCMD cases in Japan is not known and it is uncertain whether this is due to a definite varying incidence

of CMD in different geographic areas, or merely to authors' interests. The existence of various forms of CMD is very likely associated with more or less marked disorders in cerebral organogenesis.^{15,16} Efforts should be made to routinely screen CMD patients regardless of mental status and autopsy studies wherever possible should be performed, to recognize more aspects of this heterogeneous disease.

REFERENCES

1. McMenamin JB, Becker LE, Murphy EG. Congenital muscular dystrophy: a clinico-pathological report of 24 cases. *J Pediatr* 1982; 100: 692-697.
2. Donner M, Rapola J, Somer H. Congenital muscular dystrophy. A clinico-pathological and follow up study of 15 patients. *Neuropediatric* 1975; 6: 239-258.
3. Echenne B, Arthuis M, Billard J, et al. Congenital muscular dystrophy and cerebral CT scan anomalies. Results of a collaborative study of the Societe de Neurologie Infantile. *J Neurol Sci* 1986; 75: 7-21.
4. Goebel HH, Fidzianska A, Lenard HG, et al. A morphological study of non-Japanese congenital muscular dystrophy associated with cerebral lesions. *Brain Dev* 1983; 5: 292-301.
5. Damska M, Wisniewski K, Sher J. Cerebro-oculo-muscular syndrome: a variant of Fukuyama congenital muscular dystrophy. *Clin Neuropathol* 1982; 25: 93-98.
6. Fukuyama Y, Osawa M, Suzuki H. Congenital progressive dystrophy of the Fukuyama type. Clinical, genetic and pathological considerations. *Brain Dev* 1981; 3: 1-29.
7. Martinelli P, Gabellini AS, Ciucci G, et al. Congenital muscular dystrophy with central nervous system involvement: case report. *Eur Neurol* 1987; 26: 17-22.
8. Krijgsman JB, Barth PG, Stam FC, et al. Congenital muscular dystrophy and cerebral dysgenesis in a Dutch family. *Neuropediatric* 1980; 11: 108-120.
9. Fukuyama Y, Osawa M. A genetic study of the Fukuyama type congenital muscular dystrophy. *Brain Dev* 1984; 6: 373-390.
10. Misugi N. Light and electron microscopic studies of congenital muscular dystrophy. *Brain Dev* 1980; 2: 191-199.
11. Olney R, Miller R. Inflammatory infiltration in Fukuyama type congenital muscular dystrophy. *Muscle Nerve* 1983; 6: 75-76.
12. McMenamin JB, Becker LE, Murphy EG. Fukuyama-type congenital muscular dystrophy. *J Pediatr* 1982; 101: 580-582.
13. Kamoshita S, Konishi Y, Segawa M, et al. Congenital muscular dystrophy as a disease of the central nervous system. *Arch Neurol* 1976; 33: 513-516.
14. Yoshioka M, Saiwai S. Congenital muscular dystrophy (Fukuyama type) — changes in the white matter low density on CT. *Brain Dev* 1988; 10: 41-44.
15. Sarnat HB. Le cerveau influence-t'il le développement musculaire du fœtus humain? *Can J Neurol Sci* 1985; 12: 111-120.
16. Sarnat HB. Cerebral dysgenesis and their influence on fetal muscle development. *Brain Dev* 1986; 8: 494-499.