

Relationship between white matter integrity and serum cortisol levels in drug-naive patients with major depressive disorder: diffusion tensor imaging study using tract-based spatial statistics

Xiaodan Liu, Keita Watanabe, Shingo Kakeda, Reiji Yoshimura, Osamu Abe, Satoru Ide, Kenji Hayashi, Asuka Katsuki, Wakako Umene-Nakano, Rieko Watanabe, Issei Ueda, Jun Nakamura and Yukunori Korogi

Background

Higher daytime cortisol levels because of a hyperactive hypothalamic–pituitary–adrenal axis have been reported in patients with major depressive disorder (MDD). The elevated glucocorticoids inhibit the proliferation of the oligodendrocytes that are responsible for myelinating the axons of white matter fibre tracts.

Aims

To evaluate the relationship between white matter integrity and serum cortisol levels during a first depressive episode in drug-naive patients with MDD (MDD group) using a tract-based spatial statistics (TBSS) method.

Method

The MDD group ($n=29$) and a healthy control group ($n=47$) underwent diffusion tensor imaging (DTI) scans and an analysis was conducted using TBSS. Morning blood samples were obtained from both groups for cortisol measurement.

Results

Compared with the controls, the MDD group had significantly

reduced fractional anisotropy values ($P<0.05$, family-wise error (FWE)-corrected) in the inferior fronto-occipital fasciculus, uncinate fasciculus and anterior thalamic radiation. The fractional anisotropy values of the inferior fronto-occipital fasciculus, uncinate fasciculus and anterior thalamic radiation had significantly negative correlations with the serum cortisol levels in the MDD group ($P<0.05$, FWE-corrected).

Conclusions

Our findings indicate that the elevated cortisol levels in the MDD group may injure the white matter integrity in the frontal–subcortical and frontal–limbic circuits.

Declaration of interest

None.

Copyright and usage

© The Royal College of Psychiatrists 2016.

White matter abnormalities constitute one element of the pathogenesis of major depressive disorder (MDD).^{1,2} Diffusion tensor imaging (DTI) is a reliable magnetic resonance technique for examining white matter microstructure *in vivo* and has provided information that can estimate the integrity of pathways within relevant neural networks. A commonly used DTI-based quantitative measure is the fractional anisotropy value, which estimates the degree to which tissue organisation limits diffusion of water molecules in white matter fibre tracts. For example, the fractional anisotropy value is thought to provide a useful marker of white matter fibre tract integrity, with high values of fractional anisotropy indicating intact healthy neurons. Recently, tract-based spatial statistics (TBSS), a novel voxel-wise approach, was introduced.³ This method has superior objectivity and interpretability of DTI analyses than the regions of interest method. In addition, TBSS can analyse the entire brain for group differences or correlations, so it is not restricted to specific brain areas. Previous DTI studies using TBSS methods have found abnormalities (i.e. reduced fractional anisotropy) of various white matter fibre tracts in people with MDD, which include the anterior thalamic radiation,^{4,5} inferior fronto-occipital fasciculi,^{4,5} uncinate fasciculi,^{4–6} sagittal stratum,^{7,8} cingulum,^{4,7,9} longitudinal fasciculi,^{4,6,10,11} internal and external capsule,^{4,7,12} corpus callosum,^{4,8,10,12} and corona radiata.^{4,5,7,10–12} Since these fibre

tracts form the important anatomical connectivity or circuits, they may be directly relevant to the pathophysiology of MDD.¹³

Many theories exist regarding the pathophysiological basis of MDD; genes, the environment and endocrine dysfunction are all considered to be factors influencing MDD.¹⁴ A previous study provided evidence of a hyperactive hypothalamic–pituitary–adrenal (HPA) axis in people with MDD and elevated cortisol levels have been observed in most patients with MDD.¹⁵ Thus, deregulation of the HPA axis is thought to play a role in the aetiology of MDD.¹⁵ Several magnetic resonance studies demonstrated a negative correlation between the hippocampus and anterior cingulate cortex volume and cortisol levels in people with MDD.^{16–18} However, there have been no imaging studies that have evaluated the relationship between high levels of cortisol and white matter damage. We hypothesised that a prolonged exposure to glucocorticoids might have an impact not only on the hippocampus and anterior cingulate cortex,^{16–18} but also extend into the white matter of other regions in people with MDD. This may be supported by an animal study, in which the authors demonstrated that elevated glucocorticoids inhibited the proliferation of astrocytes and oligodendrocytes, which are responsible for myelinating the axons of white matter fibre tracts.¹⁹ Therefore the purpose of the current study was to evaluate the relationship between white matter abnormalities

and serum cortisol levels in the first depressive episode of patients with MDD who are drug-naive using TBSS.

Method

Participants

In total, 29 right-handed, drug-naive individuals with MDD in their first depressive episode were recruited (the MDD group). A psychiatrist (K.H., with 7 years of experience in psychiatry) who did not know the serum cortisol levels or imaging data for the patients, diagnosed them as having MDD using a structured clinical interview according to the DSM-IV-TR criteria.²⁰ The severity of depression was evaluated using the 17-item Hamilton Rating Scale for Depression (HRSD-17).²¹ Only those with a HRSD-17 score ≥ 14 were eligible for the study. The exclusion criteria included any history of neurological diseases or other physical diseases, and the presence of other disorders (i.e. the participants had no evidence of schizoaffective disorder, bipolar disorder, Axis II personality disorder or intellectual disability). The age of the participants in the MDD group ranged from 22 to 67 years (mean = 45.7, s.d. = 12.5), and 17 were men and 12 women.

In addition, 47 right-handed, healthy participants (the control group) were recruited via an interview conducted by the same psychiatrist using the Structured Clinical Interview for the DSM-IV-TR, non-patient edition (SCID-I-NP).²² None of them had a history of serious medical or neuropsychiatric illness or a family history of major psychiatric or neurological illness among their first-degree relatives, and all were matched with the patients in terms of age and gender. The age of the control group ranged from 20 to 65 years (mean = 41.8, s.d. = 11.0), 37 were men and 10 women. This study was approved by our institutional review board. Written informed consent was obtained from each participant after they had been given a detailed description of the study.

Serum cortisol evaluation

Morning (09.00–10.00 h) blood samples were obtained from all participants in both groups for cortisol measurement. All the blood samples were immediately centrifuged, and the serum was stored at -20°C until it was assayed. The precipitation of proteins with ethanol was followed by a direct radioimmunoassay using a highly specific antibody.²³

MRI acquisition

Magnetic resonance imaging (MRI) scans were performed on the same day as cortisol measurement (09.00–17.00 h). All magnetic resonance examinations were performed using a 3T MR system (Signa EXCITE 3T; GE Healthcare, Waukesha, Wisconsin, USA) with an eight-channel brain-phased-array coil. DTIs were acquired by a single-shot, spin-echo planar sequence with the following parameters: repetition time (TR)/echo time (TE) = 12000/83.3 ms; 4 mm slice thickness; no gap; field of view (FOV) = 26 cm; number of excitations 1 and spatial resolution $1.02 \times 1.02 \times 4$ mm. Diffusion gradients (b -value of 1000 s/mm^2) were always applied for each of the three axes simultaneously around the 180° pulse. The diffusion properties were measured in 25 non-collinear directions.

Image processing

The structural distortion of the diffusion-weighted magnetic resonance images was corrected based on each T_2 -weighted echo-planar image ($b = 0 \text{ s/mm}^2$) by using eddy current correction

in the FMRIB Diffusion Toolbox software program (parts of the FMRIB Software Library; FSL v5.0.4). Non-brain tissue of each magnetic resonance image was deleted by using the brain extraction tool. The voxel-wise statistical analysis of the DTI data was performed by using the TBSS version 1.1 software program. The fractional anisotropy volumes were aligned to a target image as follows: (a) apply non-linear registration of each participant's fractional anisotropy into the FMRIB58_FA_1 mm standard-space image as the target image; (b) the target image was affine transformed to $1 \times 1 \times 1$ mm MNI 152 (Montreal Neurologic Institute, Montreal, Canada) space. A mean fractional anisotropy image was created by averaging the aligned individual fractional anisotropy images, and was then thinned to create a fractional anisotropy skeleton representing white matter tracts common to all participants.³ The fractional anisotropy skeleton was thresholded at 0.2 to exclude voxels with low fractional anisotropy values, which are likely to include grey matter or cerebrospinal fluid. Individual fractional anisotropy data and voxel-wise statistical results were projected onto this fractional anisotropy skeleton. Subsequently, the axial diffusivity and radial diffusivity were projected onto the mean fractional anisotropy skeleton and also compared between groups in the same spatial location.

Statistical analysis

For the analysis of the demographic and clinical characteristics of the participants, two-tailed t -tests and the χ^2 -test were performed to compare the differences in the serum cortisol levels, age and gender between the MDD group and control group using the SPSS v16.0 software program. The voxel-wise statistical analysis was performed using a permutation-based inference tool. The comparisons of the fractional anisotropy, axial diffusivity and radial diffusivity values between the two groups were performed using a two-sample t -test. The correlations between the serum cortisol levels and fractional anisotropy values were analysed using a single-group average with additional covariates. Age and gender were included as covariates of no interest to control for confounding variables. The number of permutations in all voxel-wise analyses was set at 5000. Values of $P < 0.05$ and > 50 voxels were considered to indicate a statistically significant difference and a correlation after family-wise error (FWE)-correction for multiple comparisons at the cluster level, using the threshold-free cluster enhancement option. The anatomical location of significant clusters was detected using the Johns Hopkins University white matter tractography atlas and the International Consortium of Brain Mapping (ICBM)-DTI-81 white matter labels atlas.

Results

Participants

Demographic and clinical information is shown in Table 1. Compared with the control group, significantly higher cortisol levels were found in the MDD group ($P < 0.05$). There were no significant differences in terms of age and gender in the groups.

Comparison between the two groups

Significant fractional anisotropy differences were observed between the two groups. Online Fig. DS1 shows the spatial distribution of the brain regions, indicating a reduction of fractional anisotropy values in the MDD group compared with the control group. The MDD group had significantly reduced fractional anisotropy values ($P < 0.05$, FWE-corrected) in the bilateral corticospinal tracts, left inferior fronto-occipital fasciculus, left uncinate fasciculus, left anterior thalamic radiation, left external capsule and right superior corona radiata (Fig. DS1).

Table 1 Demographic information and serum cortisol data

	Control group (n = 47)	Major depressive disorder group (n = 29)	P
Age, years: mean (s.d.)	41.8 (11.0)	45.7 (12.5)	0.16
Women, n	10	12	0.60
Hamilton Rating Scale for Depression-17 score, mean (s.d.)		21.4 (5.2)	
Serum cortisol, nmol/l: mean (s.d.)	9.3 (3.4)	12.4 (5.1)	<0.01

No significant differences were found in axial diffusivity and radial diffusivity.

Correlations between fractional anisotropy values and serum cortisol levels

A significant negative correlation of the fractional anisotropy values with the serum cortisol levels was observed in the MDD group. There were no regions that showed a positive correlation between the fractional anisotropy values and serum cortisol levels. For the control group, we found no regions that showed a significant correlation between the fractional anisotropy values and the serum cortisol levels.

Online Fig. DS2 shows the areas in which the fractional anisotropy values were associated with the cortisol levels in the MDD group. The fractional anisotropy values of the bilateral inferior fronto-occipital fasciculus, bilateral anterior thalamic radiation, left uncinate fasciculus, left cingulum, left anterior corona radiata and right external capsule had significantly negative correlations with the cortisol levels ($P < 0.05$; FWE-corrected). Therefore, the fractional anisotropy values of the left inferior fronto-occipital fasciculus, anterior thalamic radiation and uncinate fasciculus in the MDD group were significantly decreased compared with those in the control group, and also had a significant inverse correlation with the cortisol levels ($P < 0.05$; FWE-corrected). The cluster voxel size and significant MNI coordinates are presented in Table 2.

Discussion

Main findings and comparison with other studies

Hyperactivity of the HPA axis and elevated cortisol levels are considered to be characteristics of the pathophysiology of

MDD.^{24–26} We also found significantly higher serum cortisol levels in the MDD group compared with the control group. In the current study, the fractional anisotropy values of the left inferior fronto-occipital fasciculus, anterior thalamic radiation and uncinate fasciculus in the MDD group were significantly decreased compared with those in the control group, and also had a significant inverse correlation with the cortisol levels.

Our findings may be supported by the results of several DTI studies that demonstrated the presence of white matter abnormalities in the inferior fronto-occipital fasciculus, uncinate fasciculus and anterior thalamic radiation in people with MDD.^{8,27–29} Several studies reported decreased fractional anisotropy values in the inferior fronto-occipital fasciculus in MDD.^{4,5,30} The inferior fronto-occipital fasciculus are considered to be involved in reading, attention and visual processing.^{31,32} Zhang *et al* found decreased fractional anisotropy values and an increased radial diffusivity of the right uncinate fasciculus in mid-life patients with MDD, and concluded that this reflected the demyelination of the right uncinate fasciculus, which interrupted the functional connectivity of the frontal–limbic circuits.³³ Cullen *et al* also found lower fractional anisotropy values in the bilateral uncinate fasciculus in adolescents with MDD.²⁹

Interpretation of our findings

The inferior fronto-occipital fasciculus, uncinate fasciculus and anterior thalamic radiation are considered to play key roles in the frontal–subcortical circuits and frontal–limbic circuits. The frontal–subcortical circuits contains five discrete parallel loops that connect specific areas of the frontal cortex (motor area, supplementary motor area, dorsolateral prefrontal cortex, anterior

Table 2 The results of the image analyses

Anatomical region	Cluster size	P ^a	MNI coordinates, mm		
			x	y	z
Fractional anisotropy values, between-group comparison (control group > MDD group) ^b					
Right corticospinal tract	53	0.049	70	109	119
Right superior corona radiata		0.049	70	105	112
Left inferior fronto-occipital fasciculus	283	0.039	114	147	72
Left uncinate fasciculus		0.042	115	144	71
Left external capsule		0.049	119	140	69
Left corticospinal tract	1221	0.036	111	106	111
Left anterior thalamic radiation		0.040	111	104	116
Negative correlation with the cortisol levels in MDD group ^c					
Right inferior fronto-occipital fasciculus	96	0.047	56	113	73
Right external capsule		0.049	58	103	75
Left anterior thalamic radiation	706	0.044	112	156	88
Left uncinate fasciculus		0.045	111	169	88
Left inferior fronto-occipital fasciculus		0.047	113	151	90
Left cingulum	1036	0.031	107	144	100
Left anterior corona radiata		0.037	106	155	97
Right anterior thalamic radiation	3921	0.031	65	161	78

MNI, Montreal Neurologic Institute, MDD, major depressive disorder.
a. Family-wise error-corrected.
b. See online Fig. DS1.
c. See online Fig. DS2.

cingulate cortex and orbitofrontal cortex) through the striatum (caudate nucleus, putamen, ventral striatum), globus pallidus, substantia nigra and thalamus, back to the frontal cortex (Fig. 1).³⁴ Anatomically, the inferior fronto-occipital fasciculus, uncinata fasciculus and anterior thalamic radiation have a projection into the frontal cortex from the thalamus. A 'disconnection' of the frontal-subcortical circuit was proposed as one of the pathogenic elements associated with MDD.¹³ The frontal-limbic circuits are 'open' loops incorporated into the functional connectivity between frontal areas (anterior cingulate cortex and orbitofrontal cortex) and other cortex, thalamus and limbic system areas (amygdala and hippocampus) (Fig. 2).³⁵ Anatomically, the uncinata fasciculus has a projection into the anterior cingulate cortex and orbitofrontal cortex from limbic system areas. An association between dysregulation of the frontal-limbic circuits and MDD has been postulated based on functional imaging studies.^{1,36,37}

Therefore, in the current study, the observation of fractional anisotropy reductions in the inferior fronto-occipital fasciculus, uncinata fasciculus and anterior thalamic radiation may support the theory that the disconnection in the frontal-subcortical circuits and/or frontal-limbic circuits is one of the pivotal issues associated with the pathogenesis of MDD. Furthermore, our results suggest that the high levels of cortisol in people with MDD might injure the microstructures in these specific white matter circuits.

Reduced fractional anisotropy values are thought to reflect reduced organisation of the white matter, reduced axonal density and/or reduced myelination.^{38,39} Although the exact cause of the fractional anisotropy reduction in the cortisol-associated regions (i.e. inferior fronto-occipital fasciculus, uncinata fasciculus and anterior thalamic radiation) remains unclear, we speculate that there may be two possible mechanisms: (a) direct damage to the white matter caused by the high levels of cortisol; (b) a secondary effect on the white matter mediated by grey matter damage because of the high levels of cortisol.

With regard to the direct damage, an animal study demonstrated that elevated glucocorticoid levels inhibited astrocyte and oligodendrocyte proliferation.¹⁹ Because white matter fibre tracts are myelinated by oligodendrocytes our results might indicate that high levels of cortisol can alter the myelination of the white matter fibre tracts in people with MDD. In the current study, there were no significant differences in the fractional anisotropy values in other regions that showed significantly negative correlations with the cortisol levels (the right external capsule, left cingulum and left

anterior corona radiata, between the MDD and control groups. In other words, our findings suggest that the integrity of the white matter in the left anterior thalamic radiation, inferior fronto-occipital fasciculus and uncinata fasciculus might be more sensitive to hypercortisolism than other regions, and the microstructural changes in these white matter tracts might occur even in the early stages of MDD.

In terms of grey matter damage because of the high levels of cortisol, previous animal studies have demonstrated that the hippocampus, anterior cingulate cortex and frontoparietal cortex (sensory and motor) contained high concentrations of glucocorticoid receptors and were vulnerable to the noxious effects of glucocorticoids, consequently impairing neuronal plasticity and neurogenesis.^{17,40} Preclinical studies revealed that exposure to high levels of cortisol was associated with brain atrophy of the hippocampus¹⁶ and the medial prefrontal cortex in patients with MDD.⁴¹ In another study, patients with MDD showed a decreased rostral anterior cingulate cortex volume compared with controls, and the anterior cingulate cortex volume reduction was inversely correlated with the cortisol levels.¹⁸ Since the inferior fronto-occipital fasciculus, uncinata fasciculus and anterior thalamic radiation are all connected to the anterior cingulate cortex or the hippocampus (Figs 1 and 2), our observation of fractional anisotropy reduction in the cortisol-associated regions could be the result of secondary damage because of the grey matter abnormalities.

Although, in the current study, the MDD group had significantly reduced fractional anisotropy values in the bilateral corticospinal tracts, left external capsule and right superior corona radiata, the fractional anisotropy values of these regions had no correlation with the cortisol levels. Many investigators have found a reduced fractional anisotropy value in these regions using TBSS.^{11,42,43} Therefore, just like the effects of the high levels of cortisol, several other factors such as genotype, stress adverse developmental environment and biochemistry may also be linked to white matter microstructural abnormalities of tract fibres detected in this study.¹⁴ A previous study reported that white matter microstructural abnormalities in superior corona radiata were associated with the brain-derived neurotrophic factor val66met polymorphism in remission of geriatric depression.⁴⁴

Limitations

Our study is associated with some limitations that should be kept in mind when interpreting the results. The first limitation was the relatively small size of the MDD group, which might have affected our results. Second, in this study, the mechanism underlying how the elevated cortisol levels altered the myelination of the white matter fibre tract has not been elaborated. The relationship

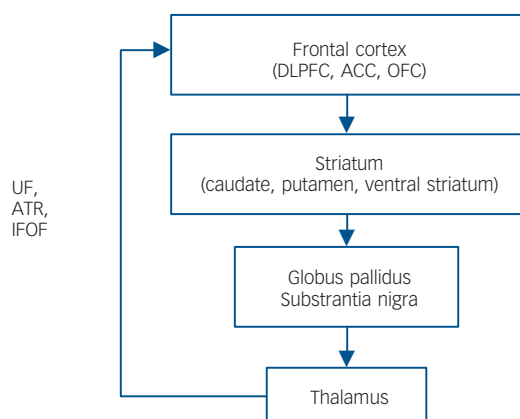


Fig. 1 General organisation of the frontal-subcortical circuits.

Inferior fronto-occipital fasciculus (IFOF), uncinata fasciculus (UF) and anterior thalamic radiation (ATR) have a projection into the frontal cortex from the thalamus. DLPFC, dorsolateral prefrontal cortex; ACC, anterior cingulate cortex; OFC, orbitofrontal cortex.

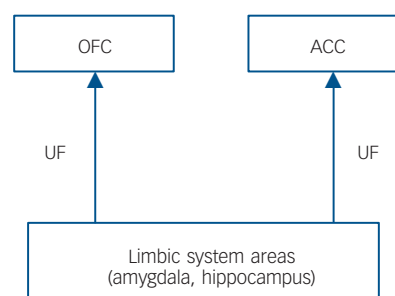


Fig. 2 General organisation of the frontal-limbic circuits.

Uncinata fasciculus (UF) has a projection into the anterior cingulate cortex (ACC) and orbitofrontal cortex (OFC) from limbic system areas.

between the HPA axis and frontal–subcortical circuits and frontal–limbic circuits might be an interesting topic for further studies.

Implications

In conclusion, in patients with early-stage MDD, the fractional anisotropy values of the inferior fronto-occipital fasciculus, uncinate fasciculus and anterior thalamic radiation were significantly decreased compared with those in a control group, and also showed significant inverse correlations with the cortisol levels. Since the inferior fronto-occipital fasciculus, uncinate fasciculus and anterior thalamic radiation are essential elements of the frontal–subcortical circuits and frontal–limbic circuits, the high levels of cortisol in people with MDD might injure the microstructures in these specific white matter circuits. Furthermore, our findings also support the theory that the ‘disconnection’ of the frontal–subcortical and frontal–limbic circuits is one of the elements associated with the pathophysiology of MDD.

Xiaodan Liu, MD, Department of Radiology, University of Occupational and Environmental Health, Fukuoka, Japan, and Medical Imaging Center, 1st Affiliated Hospital of Jinan University, Guangzhou, China; **Keita Watanabe**, MD, **Shingo Kakeda**, MD, PhD, Department of Radiology, University of Occupational and Environmental Health, Fukuoka, Japan; **Reiji Yoshimura**, MD, PhD, Department of Psychiatry, University of Occupational and Environmental Health, Fukuoka, Japan; **Osamu Abe**, MD, PhD, Department of Radiology, Nihon University School of Medicine, Tokyo, Japan; **Satoru Ide**, MD, Department of Radiology, University of Occupational and Environmental Health, Fukuoka, Japan; **Kenji Hayashi**, MD, **Asuka Katsuki**, MD, **Wakako Umene-Nakano**, MD, PhD, Department of Psychiatry, University of Occupational and Environmental Health, Fukuoka, Japan; **Rieko Watanabe**, MD, **Issei Ueda**, MD, Department of Radiology, University of Occupational and Environmental Health, Fukuoka, Japan; **Jun Nakamura**, MD, PhD, Department of Psychiatry, University of Occupational and Environmental Health, Fukuoka, Japan; **Yukunori Korogi**, MD, PhD, Department of Radiology, University of Occupational and Environmental Health, Fukuoka, Japan

Correspondence: Shingo Kakeda, Department of Radiology, University of Occupational and Environmental Health, Fukuoka, 807-8555, Japan. Email: kakeda@med.uoeh-u.ac.jp

First received 14 Mar 2014, final revision 30 Jan 2015, accepted 27 May 2015

Funding

This work was supported by a Grant-in-Aid for Scientific Research on Innovative Areas (Comprehensive Brain Science Network) from the Ministry of Education, Science, Sports and Culture of Japan.

References

- Drevets WC, Price JL, Furey ML. Brain structural and functional abnormalities in mood disorders: implications for neurocircuitry models of depression. *Brain Struct Funct* 2008; **213**: 93–118.
- Taylor WD, Hsu E, Krishnan KR, MacFall JR. Diffusion tensor imaging: background, potential, and utility in psychiatric research. *Biol Psychiatry* 2004; **55**: 201–7.
- Smith SM, Jenkinson M, Johansen-Berg H, Rueckert D, Nichols TE, Mackay CE, et al. Tract-based spatial statistics: voxelwise analysis of multi-subject diffusion data. *Neuroimage* 2006; **31**: 1487–505.
- Bessette KL, Nave AM, Caprihan A, Stevens MC. White matter abnormalities in adolescents with major depressive disorder. *Brain Imaging Behav* 2014; **8**: 531–41.
- Lagopoulos J, Hermens DF, Hatton SN, Battisti RA, Tobias-Webb J, White D, et al. Microstructural white matter changes are correlated with the stage of psychiatric illness. *Transl Psychiatry* 2013; **3**: e248.
- Zuo N, Fang J, Lv X, Zhou Y, Hong Y, Li T, et al. White matter abnormalities in major depression: a tract-based spatial statistics and rumination study. *PLoS One* 2012; **7**: e37561.
- Korgaonkar MS, Grieve SM, Koslow SH, Gabrieli JD, Gordon E, Williams LM. Loss of white matter integrity in major depressive disorder: evidence using tract-based spatial statistical analysis of diffusion tensor imaging. *Hum Brain Mapp* 2011; **32**: 2161–71.
- Kieseppa T, Eerola M, Mantyla R, Neuvonen T, Poutanen VP, Luoma K, et al. Major depressive disorder and white matter abnormalities: a diffusion tensor imaging study with tract-based spatial statistics. *J Affect Disord* 2010; **120**: 240–4.
- Henderson SE, Johnson AR, Vallejo AI, Katz L, Wong E, Gabbay V. A preliminary study of white matter in adolescent depression: relationships with illness severity, anhedonia, and irritability. *Front Psychiatry* 2013; **4**: 152.
- Cole J, Chaddock CA, Farmer AE, Aitchison KJ, Simmons A, McGuffin P, et al. White matter abnormalities and illness severity in major depressive disorder. *Br J Psychiatry* 2012; **201**: 33–9.
- Versace A, Almeida JR, Quevedo K, Thompson WK, Terwilliger RA, Hassel S, et al. Right orbitofrontal corticolimbic and left corticocortical white matter connectivity differentiate bipolar and unipolar depression. *Biol Psychiatry* 2010; **68**: 560–7.
- Guo WB, Liu F, Xue ZM, Gao K, Wu RR, Ma CQ, et al. Altered white matter integrity in young adults with first-episode, treatment-naive, and treatment-responsive depression. *Neurosci Lett* 2012; **522**: 139–44.
- Sexton CE, Mackay CE, Ebmeier KP. A systematic review of diffusion tensor imaging studies in affective disorders. *Biol Psychiatry* 2009; **66**: 814–23.
- Northoff G. Gene, brains, and environment-genetic neuroimaging of depression. *Curr Opin Neurobiol* 2013; **23**: 133–42.
- Vreeburg SA, Hoogendijk WJ, van Pelt J, Derijk RH, Verhagen JC, van Dyck R, et al. Major depressive disorder and hypothalamic-pituitary-adrenal axis activity: results from a large cohort study. *Arch Gen Psychiatry* 2009; **66**: 617–26.
- Sapolsky RM. Glucocorticoids and hippocampal atrophy in neuropsychiatric disorders. *Arch Gen Psychiatry* 2000; **57**: 925–35.
- Sapolsky RM. The possibility of neurotoxicity in the hippocampus in major depression: a primer on neuron death. *Biol Psychiatry* 2000; **48**: 755–65.
- Treadway MT, Grant MM, Ding Z, Hollon SD, Gore JC, Shelton RC. Early adverse events, HPA activity and rostral anterior cingulate volume in MDD. *PLoS One* 2009; **4**: e4887.
- Rajkowska G, Miguel-Hidalgo JJ. Gliogenesis and glial pathology in depression. *CNS Neurol Disord Drug Targets* 2007; **6**: 219–33.
- American Psychiatric Association. *Diagnostic and Statistical Manual of Mental Disorders (4th edn, text revision) (DSM-IV-TR)*. APA, 2000.
- Hamilton M. A rating scale for depression. *J Neurol Neurosurg Psychiatry* 1960; **23**: 56–62.
- First MB, Spitzer RL, Gibbon M, Williams JBW. *Structured Clinical Interview for DSM-IV-TR Axis I Disorders, Research Version, Non-patient Edition (SCID-I/NP)*. Biometrics Research, New York State Psychiatric Institute, 2002.
- Heckmann M, Wudy SA, Haack D, Pohlandt F. Reference range for serum cortisol in well preterm infants. *Arch Dis Child* 1999; **81**: F171–4.
- Carroll, Curtis GC, Mendels J. Neuroendocrine regulation in depression. I. Limbic system-adrenocortical dysfunction. *Arch Gen Psychiatry* 1976; **33**: 1039–44.
- Gold PW, Licinio J, Wong ML, Chrousos GP. Corticotropin releasing hormone in the pathophysiology of melancholic and atypical depression and in the mechanism of action of antidepressant drugs. *Ann N Y Acad Sci* 1995; **771**: 716–29.
- Pfohl B, Sherman B, Schlechte J, Winokur G. Differences in plasma ACTH and cortisol between depressed patients and normal controls. *Biol Psychiatry* 1985; **20**: 1055–72.
- Zhu X, Wang X, Xiao J, Zhong M, Liao J, Yao S. Altered white matter integrity in first-episode, treatment-naive young adults with major depressive disorder: a tract-based spatial statistics study. *Brain Res* 2011; **1369**: 223–9.
- Frodl T, Carballedo A, Fagan AJ, Liseicka D, Ferguson Y, Meaney JF. Effects of early-life adversity on white matter diffusivity changes in patients at risk for major depression. *J Psychiatry Neurosci* 2012; **37**: 37–45.
- Cullen KR, Klimes-Dougan B, Muetzel R, Mueller BA, Camchong J, Hourai A, et al. Altered white matter microstructure in adolescents with major depression: a preliminary study. *J Am Acad Child Adolesc Psychiatry* 2010; **49**: 173–83.
- Liao Y, Huang X, Wu Q, Yang C, Kuang W, Du M, et al. Is depression a disconnection syndrome? Meta-analysis of diffusion tensor imaging studies in patients with MDD. *J Psychiatry Neurosci* 2013; **38**: 49–56.
- Fox CJ, Iaria G, Barton JJS. Disconnection in prosopagnosia and face processing. *Cortex* 2008; **44**: 996–1009.
- Catani M, Mesulam M. The arcuate fasciculus and the disconnection theme in language and aphasia: history and current state. *Cortex* 2008; **44**: 953–61.
- Zhang A, Leow A, Ajilore O, Lamar M, Yang S, Joseph J, et al. Quantitative tract-specific measures of uncinate and cingulum in major depression using diffusion tensor imaging. *Neuropsychopharmacology* 2012; **37**: 959–67.

- 34 Tekin S, Cummings JL. Frontal-subcortical neuronal circuits and clinical neuropsychiatry: an update. *J Psychosom Res* 2002; **53**: 647–54.
- 35 Bonelli RM, Cummings JL. Frontal-subcortical circuitry and behavior. *Dialogues Clin Neurosci* 2007; **9**: 141–51.
- 36 Drevets WC. Functional anatomical abnormalities in limbic and prefrontal cortical structures in major depression. *Prog Brain Res* 2000; **126**: 413–31.
- 37 Wakana S, Jiang H, Nagae-Poetscher LM, van Zijl PC, Mori S. Fiber tract-based atlas of human white matter anatomy. *Radiology* 2004; **230**: 77–87.
- 38 Basser PJ, Pierpaoli C. Microstructural and physiological features of tissues elucidated by quantitative-diffusion-tensor MRI. *J Magn Reson* 1996; **111**: 209–19.
- 39 Beaulieu C. The basis of anisotropic water diffusion in the nervous system – a technical review. *NMR Biomed* 2002; **15**: 435–55.
- 40 Ahima RS, Harlan RE. Charting of type II glucocorticoid receptor-like immunoreactivity in the rat central nervous system. *Neurosci* 1990; **39**: 579–604.
- 41 Diorio D, Viau V, Meaney MJ. The role of the medial prefrontal cortex (cingulate gyrus) in the regulation of hypothalamic-pituitary-adrenal responses to stress. *J Neurosci* 1993; **13**: 3839–47.
- 42 Song YJ, Korgaonkar MS, Armstrong LV, Eagles S, Williams LM, Grieve SM. Tractography of the brainstem in major depressive disorder using diffusion tensor imaging. *PLoS One* 2014; **9**: e84825.
- 43 Benedetti F, Yeh PH, Bellani M, Radaelli D, Nicoletti MA, Poletti S, et al. Disruption of white matter integrity in bipolar depression as a possible structural marker of illness. *Biol Psychiatry* 2011; **69**: 309–17.
- 44 Alexopoulos GS, Glatt CE, Hoptman MJ, Kanellopoulos D, Murphy CF, Kelly Jr RE, et al. BDNF val66met polymorphism, white matter abnormalities and remission of geriatric depression. *J Affect Disord* 2010; **125**: 262–8.



psychiatry in history

Antoni Kępiński (1918–1972), pioneer of post-traumatic stress disorder


Maximilian Schochow and Florian Steger

Antoni Ignacy Tadeusz Kępiński was born on 16 November 1918 in Dolyna (Ukraine). He studied human medicine at the Jagiellonian University in Kraków, Poland, but took a break from his studies in 1939 to enlist as a volunteer in the Polish Army. In 1940 he was imprisoned in a concentration camp. After his liberation in 1945 Kępiński continued his studies in Edinburgh, and after obtaining a PhD in Kraków completed his psychiatric education in 1959 at the London Institute of Psychiatry (Maudsley Hospital).

His experience as a prisoner in a concentration camp heavily influenced Kępiński's work. Together with the former Auschwitz prisoner Stanisław Kodziński (1918–1990), Kępiński engaged in hundreds of discussions with one-time concentration camp prisoners. Drawing from his scientific work with these survivors he developed his theories on psychological disorders (Auschwitz syndrome) and his model of the psyche (information metabolism). In doing so he formulated two basic assumptions. The first assumption implies that the structural organisation of cells is similar to the human psyche. In his view, it has cell-like properties: borders, a control centre, a system for the distribution and processing of information as well as an energy source. The second assumption starts from the premise that there is a connection between the surroundings and psyche. Therefore, the psyche functions like a permeable system that interacts with its environment.

For Kępiński, an individual hierarchy of values controls information selection. This hierarchy comprises three levels: biological, emotional and socio-cultural. The first two levels happen automatically and affect decisions unconsciously, but the socio-cultural level belongs, in contrast, to human consciousness. Thus, behaviour is controlled to a certain extent by the individual's will. While processing the information that the psyche receives from either the body or the external world, preservation of the individual value system remains central. If the hierarchy of values loses its equilibrium, then this can lead to psychological disorders. This disturbed relationship between the individual and their surroundings ultimately leads to psychopathologies. In this Kępiński sees the roots of the various types of psychological and physical suffering experienced by former Auschwitz prisoners, which he summarises as the Auschwitz syndrome. He described the basic characteristics and symptoms of what DSM-5 now refers to as 'trauma- and stressor-related disorders'.

Kępiński died in 1972 in Kraków. In his lifetime, his scientific work was barely recognised on an international level because of Poland's isolation until 1989/1990.



Photograph of Antoni Kępiński from the personal archive of Prof. Zdzisław Ryn. Reproduced with permission.