

Presidential Address: XVII Canadian Congress of Neurological Sciences

Cushing's Disease: 50 Years Later

JULES HARDY, M.D., F.R.C.S. (c), F.A.C.S.

SUMMARY: *The recent improvements in transsphenoidal microsurgery have once again placed the emphasis on the basophilic adenoma of the pituitary as the etiology of the disease originally described by Harvey Cushing fifty years ago.*

In 75 operated cases, tumors were found in 60 cases: 52 were microadenomas, 4 were larger adenomas and 4 were invasive. In 15 cases, no tumor was found at surgery; a selective partial central hypophysectomy was performed in 11 cases and a total hypophysectomy in 4. Among the latter, 3

additional microadenomas were found at pathology. The majority of the microadenomas were located in the center of the gland most often near or within the neural lobe.

In 59 patients with a non invasive tumor, initial cure was obtained in 52 (88%); only 1 of the 4 patients with an invasive tumor was cured.

In the 12 cases without surgical or pathological tumor, partial or total hypophysectomy resulted in 10 cures (83%).

RÉSUMÉ: *Les développements récents de la microchirurgie transsphénoïdale ont de nouveau attiré l'attention sur l'adénome hypophysaire basophile comme étiologie de la maladie décrite pour la première fois par Harvey Cushing il y a cinquante ans.*

Dans 75 cas opérés, une tumeur a été trouvée dans 60 cas: 52 étaient des microadénomes, 4 étaient des adénomes plus gros et 4 étaient envahissants. Dans 15 cas, aucune tumeur n'a été trouvée à la chirurgie; une hypophysectomie sélective centrale fut pratiquée dans 11 cas et une hypophysectomie totale dans 4. Parmi ces

derniers, 3 autres microadénomes ont été trouvés à la pathologie. La majorité des microadénomes étaient localisés dans le centre de la glande le plus souvent près ou dans le lobe nerveux.

Chez 59 patients avec un adénome non envahissant, la guérison initiale a été obtenue dans 52 cas (88%). Seulement 1 patient avec une tumeur envahissante a été guéri. Chez le 12 cas sans tumeur vérifiée à la chirurgie ou à la pathologie, l'hypophysectomie partielle ou totale a produit 10 guérisons (83%).

Fifty years ago, in 1932, when Harvey Cushing described the clinical picture of the disease which bears his name, he first attributed its etiology to a pituitary disorder, more precisely to pituitary basophilism. In the series of sixteen cases which he collected from various sources, three of which were of his own observation, proven *basophilic* adenomas were encountered in six out of the ten fatal cases with autopsy (table I) and "In two instances, the adenoma remains undifferentiated; in two others, the gland was said to be normal, and the possibility of verification unfortunately is now excluded."

Among the eight cases with complete postmortem examination, the supra-renal gland showed: bilateral enlargement in two, unilateral hypertrophy or hyperplasia in two, an adenoma with bilateral enlargement in one, and normal adrenal glands in three. Radiological studies of the sella turcica were available in ten of the sixteen cases and showed an enlarged sella in only one (no. 10); the others were reported as having normal sized sellae. In one autopsy case (no. 12) with a large tumor of 3 x 2 x 2.5 cm, the sella was reported normal.

It is therefore on that historical background of observations that pituitary basophilism was eventually termed "Cushing's Disease". As Cushing concluded with a very keen insight in his classical paper: "However this may be, the establishment of a clinical syndrome and its cause must usually precede effective treatment, and in my belief that the disorder is an expression of pituitary basophilism should be substantiated by further studies elsewhere, the most effective treatment for the condition can be left for further experience".

Professor and Chairman, Division of Neurosurgery, Faculty of Medicine, University of Montreal.

Requests for Reprints to: Dr. Jules Hardy, 1386 Sherbrooke E., Montreal, P.Q., Canada H2L 1M4.

CUSHING'S SERIES (1932)

CASE NO./NAME	SEX/AGE	OBSERVED AND/OR REPORTED BY: IN		SELLA X-RAY	AUTOPSY		REMARKS			
					PITUITARY	ADRENALS				
1	MINNIE G.	F	23	CUSHING (J. HOPKINS H.) #27140	1912	N	-	-	STILL ALIVE 1932 (45 y.o.)	
2	Miss. A.O.	F	20	TURNEY, H.G. PARKES-WEBER (LONDON)	1913 1914		PARTIAL ABSORPTION OF POSTERIOR CLINOID PROCESS (N. SIZE)	N	ENLARGED LEFT SUPRARENAL.	UNQUESTIONABLE PRIMARY ADRENAL DISORDER PARKES-WEBER
3	-	F	23	ANDERSON (GLASGOW)	1915	-	-	BASOPHIL. AD. 5 MM	13 MM TUMOR IN ONE ADRENAL. BOTH ADRENALS SLIGHTLY ENLARGED.	-
4	-	F	24	ZONDEK (BERLIN)	1923	-	-	OBSCURE LESION FIBROUS TISSUE ADENOMATOUS LIKE STRUCTURE	-	-
5	S.G.	F	12	OPPENHEIMER-FISHER (NEW YORK)	1924	-	-	-	-	NO AUTOPSY CHARACTERISTIC OF SUPRARENAL HYPERPLASIA CLIN.
6	E.B.	F	28	PARKES-WEBER-TURNBULL (LONDON)	1926	N	-	BASOPHIL. AD. 3 x 4.5 MM	"EXCESS MEDULLA"	-
7	-	F	20	TEEL (CLEVELAND)	1931	-	-	BASOPHIL. AD. 2.5 MM	"ENLARGEMENT" NO HISTOLOGICAL CHANGE IN STRUCTURE.	-
8	E.C.	M	19	FRIEDMAN (NEW YORK)	1921	-	-	-	"ATROPHIC" THIN BONE OF SELLA & SPHENOID (N. SIZE)	-
9	-	M	27	MOOSER (ZURICH)	1921	-	-	N	"POROUS BONE" NOT ENLARGED. (N. SIZE)	-
10	K.W.	M	31	RAAB-KRAUSS (PRAGUE)	1924	-	ENLARGED	BASOPHIL. AD. INFILTRATING THE POSTERIOR LOBE. 5 x 9 MM	N	-
11	E.G.F.	M	30	CUSHING (P.B.B.H.) #37076	1930	N	-	-	-	RADIATION ON PITUITARY IMPROVED NO FOLLOW UP
12	-	M	24	WIETH-PEDERSEN (COPENHAGUE)	1931	N	-	3 x 2 x 2.5 CM NO BASOPHILIC	LEFT ADRENAL HYPERPLASIC	-
ADDENDUM*										
13	-	F	36	BAUER-STERNBERG (VIENNA)	1930	-	-	BASOPHIL. AD. MINUTE PAPILLARY. 1 MM	N	-
14	-	F	44	MOEHLIG (DETROIT)	1931	N	-	BASOPHIL. AD. WHITISH GREY. 2 MM	-	-
15	ALICE D.	F	15	CUSHING (P.B.B.H.) #40886	1932	N	-	-	-	RADIATION ON PITUITARY SOME IMPROVEMENT NO FOLLOW UP
16	-	F	12	ELLIS (LONDON)	1932	N	-	-	-	LAPAROTOMY: NO TUMOR FOUND NO FOLLOW UP.

* THIS TABLE WAS MADE FROM THE ANALYSIS OF THE WHOLE SERIES OF 16 CASES PUBLISHED WITH THE ADDENDUM IN: CUSHING, H. - PAPERS RELATING TO THE PITUITARY BODY, HYPOTHALAMUS AND PARASYMPATHETIC NERVOUS SYSTEM. CHAPTER III - "THE BASOPHIL ADENOMAS OF THE PITUITARY BODY AND THEIR CLINICAL MANIFESTATIONS ("PITUITARY BASOPHILISM)". C.C. THOMAS, ED., 113-174, 1932.

N: normal
-: no information

Table 1 — Cushing's series, 1932.

In the absence of radiological evidence of a pituitary adenoma in the majority of cases and despite the laboratory demonstration of hypercortisolism secondary to ACTH pituitary oversecretion, the standard treatment until recent years has been the removal of the target organ, i.e. adrenalectomy (Melby, 1971). However, in the various series reported, from 10 to 20% of the patients developed secondary hyperpigmentation with growth of the pituitary tumor resulting in Nelson's syndrome (Salassa et al, 1959; Hopwood and Kenny, 1975).

Although Cushing pioneered the extracranial transsphenoidal approach, he had not had the opportunity to operate on a patient. The modern revival of the transsphenoidal surgical approach has benefited from the introduction of the combined use of televised radiofluoroscopic control, optical magnification with the surgical microscope and development of microsurgical techniques of dissection (Hardy, 1969, 1971). These refinements in technique have allowed for the distinction between normal and pathological pituitary tissues thus opening the field of histological functional microsurgery. The identification of a microadenoma measuring a few mm became feasible. Selective microadenectomy without permanent pituitary failure has become the ideal treatment of Cushing's disease (Gold, 1979). Within the last decade, pituitary microsurgical exploration has been advocated and has emerged as the primary treatment despite a radiographi-

cally normal sella turcica (Hardy, 1973, 1975; Bigos et al, 1977, 1980; Salassa et al, 1978; Tyrell et al, 1978).

In our series of over 900 cases of surgically treated pituitary disorders, more than 80% were hypersecreting. This presentation is a summary of our experience in the treatment of Cushing's disease and a reappraisal attempt fifty years after its original description in 1932.

MATERIAL AND METHODS

Between 1963 and 1982, 87 patients suffering from Cushing's disease, including 12 cases of Nelson's syndrome, underwent a transsphenoidal pituitary exploration. There were 22 males and 65 females. The patients' age ranged from 9 to 64 years. Twenty were under 20, fifty-six between 20-50 and eleven over 50 years. Because of their special nature, the twelve cases of Nelson's syndrome will not be considered.

In the 75 cases of Cushing's disease, five patients had been previously treated elsewhere: one by pituitary radiation, three by a unilateral adrenalectomy and radiation on the pituitary, and one by a previous transsphenoidal incomplete tumor excision.

The biological diagnosis of Cushing's disease was established on the basis of elevated levels of twenty-four hour urinary 17-OHCS or free cortisol, the absence of diurnal variations of serum cortisol and the results of pituitary adrenal suppression tests by dexamethasone. The cure of Cushing's disease was confirmed by the reversal of the clinical manifesta-

tions and by the fall to normal or below normal values of plasma cortisol and urinary 24 hour 17-OHCS or free cortisol. Non-corticotroph anterior pituitary functions were evaluated by TRH, LH-RH and insulin-induced hypoglycemia tests. Cortisol in serum and urine was determined by specific protein binding techniques. Plasma TRH, FSH, LH, prolactin and A.C.T.H. were measured by specific double antibody radioimmunoassay methods.

According to our radiological classification (Hardy, 1973), 49 patients had no radiological anomalies of the sella (grade 0). 18 patients had focal thinning or blistering of the sella floor on polytomography (grade I). 4 patients had an intact enlarged sella (grade II). 3 had a localized erosion of the sella floor (grade III) and 1 had a diffuse destruction of the sellar contour (grade IV). The latest generation EMI-7070 scanner was available in the last 6 cases and permitted the detection of hypodense lesions as small as 2 mm, five of which were located in the central portion of the gland.

SURGICAL TREATMENT

All cases were operated on by the transsphenoidal approach as previously described (Hardy, 1971). In the 4 cases with an invasive tumor, an extensive resection with total sellar clean out was attempted. In the 4 cases with an enclosed tumor in an enlarged sella grade II, a selective microsurgical adenectomy was performed. In the 18 cases with a grade I sella, a

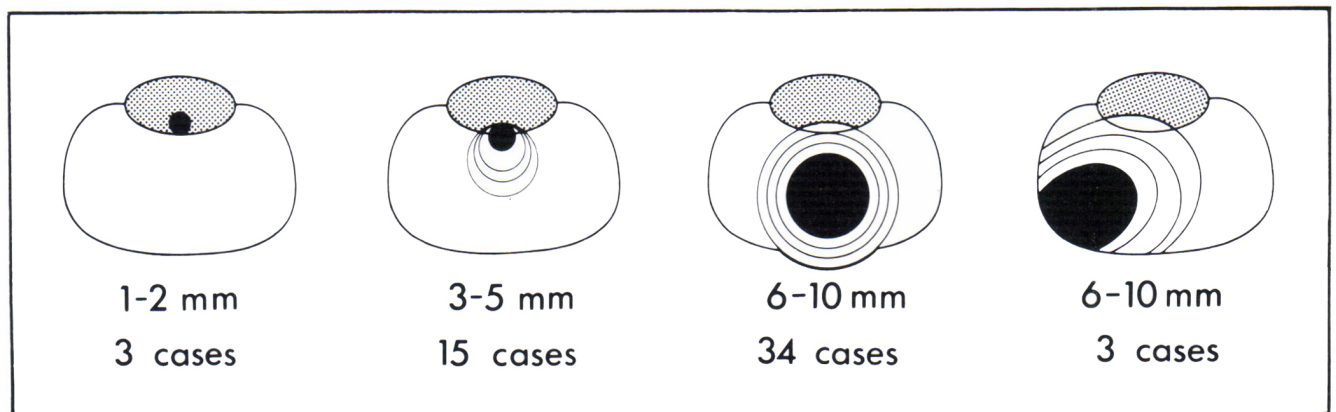


Figure 1 — Topographical distribution of 55 microadenomas according to size and localization. Horizontal section of the pituitary gland. Dotted area represents the posterior lobe.

microadenoma was found in all cases. In the 49 cases with a normal sella, a microadenoma was visible in 34 cases.

In 15 cases, no tumor was detected after careful exploration within the gland through several vertical and horizontal incisions. In 4 cases with the patient's preoperative consent, the procedure was terminated by total hypophysectomy. Most interestingly, in 2 of these cases, a microadenoma measuring approximately 1 mm in diameter was identified at histology and both were located in the neural lobe. Finally, in the 11 cases where no tumor was seen, repeated biopsies of the adenohypophysis extending to the posterior lobe resulted in a selective hypophysectomy of the central mucoid zone containing most of the ACTH cells. In only 1 of the latter cases was a 3 mm microadenoma identified histologically.

The topographical distribution of the 52 surgically visible microadenomas is illustrated in figure 1. 34 were located in the central core of the gland, just near or within the posterior lobe, 3 were excentric, extending from the midline to the lateral part of the gland. In these 37 cases, the lesions measured

from 6 to 10 mm and were bulging at the surface of the gland. In 15 cases, lesions measuring less than 6 mm in diameter were found inside the parenchyma deep posteriorly and inferiorly abutted to or embedded within the posterior lobe. The 3 tumors that were not seen by the surgeon but found by the pathologist were located in the posterior lobe.

The pathological study obtained in all tumors showed that they consisted of basophilic cells containing PAS positive granules. Immunochemical studies in 13 cases revealed that the granules stained positively with antiserum to ACTH or to β -LPH with the peroxidase anti-peroxidase complex. Electron microscopic study of the tumors showed typical ACTH tumor cells as previously reported (Robert, et al., 1978). In the 12 cases without tumor, the tissue specimens showed normal anterior pituitary cells with many Crooke's changes in the basophils and normal neural lobe tissue.

Two patients died as a direct consequence of surgery. The patient with a grade IV lesion had invasion of the cavernous sinus and the internal carotid

artery and died after ten days from subarachnoid hemorrhage. Another patient, after a third operation to achieve total sellar clean out, died of adrenal insufficiency from neglecting to take cortisone. Diabetes insipidus was transient in five cases and permanent in one case.

RESULTS

The results are summarized in Table 2. In the 4 cases with an invasive lesion, in whom a total sellar clean out was attempted, correction of hypercortisolism was obtained in only 1 patient. The 4 cases with an enclosed lesion grade II had a selective adenomectomy and all 4 were biologically cured without deficit. In the 18 cases with a grade I sella, who had a selective removal of a microadenoma, 15 patients were cured without deficit (83%).

In the 49 cases with a radiologically normal sella (grade 0), a microadenoma was found at surgery in 34 and at pathology in an additional 3 (the latter among 15 cases who had a partial or total hypophysectomy). 33 of these 37 patients with a microadenoma were biologically cured

CUSHING'S DISEASE (75 cases)






SELLA TURCICA RADIOLOGICAL CLASSIFICATION		NO. OF CASES	SURGICAL AND/OR PATHOLOGICAL FINDINGS	CURED	%	
Gr 0 (Normal)		49	NO Lesion	12	10	83%
			Microadenoma	37		
Gr I		18	Microadenoma	18	15	88%
Gr II		4	Adenoma	4	4	
Gr III		3	Invasive adenoma	3	1	25%
Gr IV		1	Invasive adenoma	1	0	

Table 2 — Results of transsphenoidal microsurgery in 75 cases of Cushing's disease in relation to the radiological classification of the sella turcica.

(89%). In the remaining 12 cases without a detectable tumor, who had a selective partial central hypophysectomy (10 cases) and total hypophysectomy (2 cases), hypercortisolism was corrected in 10 cases (83%).

In summary, in 59 patients with a non-invasive tumor, initial cure was obtained in 52 cases (88%). In the total series of 75 cases, hypercortisolism was corrected in 63 cases (84%). Two patients with initial cure had a recurrence respectively ten and thirty months later. One was finally cured by total hypophysectomy and the other by radiation therapy.

All patients, following successful selective adenectomy, developed transient hypocortisolism requiring initial replacement by a maintenance dose of cortisone with a tapering program for withdrawal, followed by gradual recovery of normal ACTH-cortisol relationships within three to twelve months. Five patients have been on cortisone replacement for more than one year. Nine patients with a long term follow up of five to eight years are known to remain cured without replacement therapy.

Deficit of other pituitary functions have been minimal. In the group of partial central hypophysectomy, TSH deficit was found in 6 cases, GH in 3, LH in 1, FSH in 1 and permanent ADH in 1.

On the other hand, recovery of previous deficits was achieved in 22 cases: return of circadian rhythm was demonstrated in 7 cases, sexual impotence was corrected in 2 cases, amenorrhea in 10 cases and galactorrhea in 3 cases. 2 female patients became pregnant. The average follow up time of all patients cured is 21 ± 6 months and the longest follow up is 17 years in 1 patient who still remains cured.

DISCUSSION

The pathogenesis of Cushing's disease remains controversial. The first hypothesis is that a primary pituitary adenoma arises "de novo". The hypothalamic disturbance of ACTH regulation resulting in the loss of circadian rhythm would be a consequence of hypercortisolism. This hypothesis is

supported in our group of 52 cured patients who had a non-invasive adenoma since, after the source of ACTH had been removed, there was a stage of ACTH deficiency and secondary hypocortisolism, with gradual recovery and return of a circadian rhythm. The smaller microadenomas, frequently found near or within the neural posterior lobe, could perhaps represent intermediate lobe tumors (Lamberts et al., 1982).

The second hypothesis is a functional disorder of ACTH cells secondary to a hypothalamic or supra-hypothalamic neuroendocrine dysfunction of the CRF-secretion. Whether this hypothalamic disturbance is capable of inducing pathological changes in the pituitary such as hyperplasia and tumor formation, is entirely speculative.

In our series of negative sellar explorations, the 10 cases who have been cured by selective partial hypophysectomy of the ACTH cells zone could represent a "hypothalamic Cushing's syndrome" at a stage of pre-adenomatous formation. These cases would be similar to the 4 in whom Dr. Cushing did not find a basophilic adenoma at autopsy. This could represent a new etiology for Cushing's disease as opposed to the classical syndrome associated with a basophilic adenoma.

CONCLUSION

The most recent advance in the treatment of Cushing's disease is the transsphenoidal microsurgical exploration of the pituitary. We advocate this procedure because of the high probability of finding a microadenoma and the high rate of cure by selective microadenectomy with preservation of pituitary functions.

In the event that no tumor is found, we recommend a selective partial hypophysectomy of the central zone rich in ACTH cells, thus removing the source of ACTH hypersecretion.

This modern therapeutic approach, now adopted by many others, is presented as a tribute to the prophetic views of Harvey Cushing who, 50 years ago, did anticipate the future development of surgical management of pituitary basophilism.

ACKNOWLEDGEMENT

The author is indebted to the many collaborators who contributed to the clinical endocrinological, radiological and pathological study of the cases herewith reported, Drs. H. Beauregard, E. Bolte, M. Chretien, F. Robert, M. Somma, M. Verdy and J.L. Vezina of the Notre-Dame Hospital and Hotel-Dieu, University of Montreal, and to Drs. R.J. Gardiner, R. Finlayson, S. Marcovitz and R. Wee of the Montreal General Hospital, McGill University.

REFERENCES

- BIGOS, S.T., ROBERT, F., PELLETIER, G., HARDY, J. (1977). Cure of Cushing's Disease by Transsphenoidal Removal of a Microadenoma from a Pituitary Gland Despite a Radiographically Normal Sella Turcica. *J. Clin. Endocrinol. Metab.*, 45, 1251-1260.
- BIGOS, S.J., SOMMA, M., RASIO, E., EASTMAN, R.C., LANTHIER, A., JOHNSTON, H.H. and HARDY, J. (1980). Cushing's Disease: Management by Transsphenoidal Pituitary Microsurgery. *J. Clin. Endocrinol. Metab.*, 50, 348-354.
- CUSHING, H. (1932). The Basophil Adenomas of the Pituitary Body and their Clinical Manifestations (pituitary basophilism). *Bull. Johns Hopkins Hosp.*, 50, 137-195.
- GOLD, E. (1979). The Cushing Syndromes: Changing Views of Diagnosis and Treatment. *Ann. Intern. Med.*, 90, 829-844.
- HARDY, J. (1969). Transsphenoidal Microsurgery of the Normal and Pathological Pituitary. *Clin. Neurosurg.*, 16, 185-217.
- HARDY, J. (1971). Transsphenoidal Hypophysectomy. *Neurosurgical Techniques. J. Neurosurg.*, 34, 581-594.
- HARDY, J. (1973). Transsphenoidal Surgery of Hypersecreting Pituitary Tumors. In: Kohler, P.O. and Ross, G.T. (eds) *Diagnosis and Treatment of Pituitary Tumors*, New York, Elsevier, 179-194.
- HARDY, J. (1975). Transsphenoidal Microsurgical Removal of Pituitary Microadenoma. *Prog. Neurol. Surg.*, 6, 200-216.
- HOPWOOD, N., KENNY, F. (1975). Increased Incidence of Post-Adrenalectomy Nelson's Syndrome in Pediatric vs Adult Cushing's disease: A Nationwide Study (abstract). *Pediatric Res.*, 9, 290.

- LAMBERTS, S.W.J., DE LANGE, S.A. and STEFANKO, S.Z. (1982). Adrenocorticotropin-Secreting Pituitary Adenomas Originate from the Anterior or the Intermediate Lobe in Cushing's Disease: Differences in the Regulation of Hormone Secretion. *J. Clin. Endocrinol. Metab.*, 54, 286-291.
- MELBY, J.C. (1971). Therapeutic Possibilities in Cushing's Syndrome (editorial). *N. Engl. J. Med.*, 285, 288-289.
- ROBERT, F., PELLETIER, G. and HARDY, J. (1978). Pituitary Adenomas in Cushing's Disease. *Arch. Pathol. Lab. Med.*, 102, 448-455.
- SALASSA, R.M., KEARNS, T.P., KERNOHAN, J.W., SPRAGUE, R.G., MAC CARTY, C.S. (1959). Pituitary Tumors in Patients with Cushing's Syndrome. *J. Clin. Endocrinol. Metab.*, 19, 1523-1539.
- SALASSA, R.M., LAWS, E.R. Jr, CARPENTER, P.C. and NORTHCUTT, R.C. (1978). Transsphenoidal Removal of Pituitary Microadenoma in Cushing's Disease. *Mayo Clin. Proc.*, 53, 24-28.
- TYRELL, J.B., BROOKS, R.M., FITZGERALD, P.A., COFOID, P.B., FORSHAM, P.H. and WILSON, C.B. (1978). Cushing's Disease: Selective Transsphenoidal Resection of Pituitary Microadenomas. *N. Engl. J. Med.*, 298, 753-758.