

Original Article

†Yingting Zhang and Xiaozhen Liu are both the first authors.

**Cite this article:** Zhang Y, Liu X, Lin C, Lee SWY, Tam S-y, Wu WVC. (2018) Pattern of geometric changes of parotid gland in conventional and intensity-modulated radiotherapy in nasopharyngeal cancer patients. *Journal of Radiotherapy in Practice* 17: 274–278. doi: 10.1017/S1460396918000043

Received: 19 January 2018

Revised: 12 February 2018

Accepted: 14 February 2018

First published online: 16 May 2018

**Key words:**

conventional radiotherapy; intensity-modulated radiotherapy; nasopharyngeal carcinoma; parotid gland; volumetric and geometric changes

**Author for correspondence:**

Vincent W. C. Wu, Department of Health Technology and Informatics, Hong Kong Polytechnic University, Hung Hom, Kowloon 852, Hong Kong SAR. Tel: 852 34008567. Fax: 852 2365 4362. E-mail: htvinwu@polyu.edu.hk

# Pattern of geometric changes of parotid gland in conventional and intensity-modulated radiotherapy in nasopharyngeal cancer patients

Yingting Zhang<sup>1,†</sup>, Xiaozhen Liu<sup>2,†</sup>, Chengguang Lin<sup>1</sup>, Shara W. Y. Lee<sup>3</sup>, Shing-yau Tam<sup>3</sup> and Vincent W. C. Wu<sup>3</sup>

<sup>1</sup>State Key Laboratory of Oncology in South China, Sun Yat-sen University Cancer Center, Guangzhou, China, <sup>2</sup>Guangdong Hospital of Traditional Chinese Medicine, Guangzhou, China and <sup>3</sup>Department of Health Technology and Informatics, Hong Kong Polytechnic University, Kowloon, Hong Kong SAR

## Abstract

**Introduction:** This study compared the pattern of radiation induced parotid changes between conventional (ConRT) and intensity modulated radiotherapy (IMRT) in nasopharyngeal carcinoma patients. **Methods:** 56 adult NPC patients treated with IMRT (n=28) and conventional radiotherapy (n=28) were recruited. CT scans were acquired before radiotherapy, at 10<sup>th</sup>, 20<sup>th</sup> and 30<sup>th</sup> fractions, and 3 months after treatment. Parotid gland was delineated in the corresponding CT slices and its mean dose was calculated. The volumetric and geometric changes of the parotid gland at various time intervals were compared against the pre-treatment structure set. The pattern of changes was compared between the two techniques. **Results:** The mean parotid dose of IMRT (37.5 ± 9.5 Gy) was significantly lower than ConRT (49.1 ± 7.4 Gy). The parotid gland volume, DICE similarity coefficient and lateral dimension of patient head gradually decreased during the radiotherapy course and partially recovered in 3 months post-treatment. The differences between two groups were not significant until at 3 month after treatment, where IMRT showed significantly better volume recovery. **Conclusion:** Similar parotid gland size and location changes were observed during the treatment course in both ConRT and IMRT. However IMRT demonstrated better parotid volume recovery after treatment.

## Introduction

Radiotherapy is the primary treatment modality of nasopharyngeal carcinoma (NPC) mainly due to its deep-seated anatomical location and relatively high radiosensitivity. Conventional radiotherapy (ConRT), which employs coplanar or non-coplanar stationary beams with fixed aperture, has been used to treat NPC for decades. These techniques treat patients in phases and deliver total doses of about 66 and 60 Gy to the primary NP tumour and cervical lymphatics, respectively.<sup>1,2</sup> Despite the local control rate remaining satisfactory for early diseases, radiation-induced complications such as xerostomia, oral mucositis and hypothyroidism have been reported.<sup>3,4</sup> Recently, ConRT has been gradually replaced by the more advanced intensity-modulated radiotherapy (IMRT), which uses dynamic multi-leaf collimator (MLC) to create intensity modulated beams. IMRT usually employs seven to nine beams and delivered target doses of 70–72 Gy and 60–66 Gy to NP and cervical nodal regions, respectively. Because IMRT is able to produce more conformal high dose distribution to the targets that offers a better sparing of organs at risk, relatively higher target dose can be prescribed.<sup>5,6</sup> Nevertheless, as the NP is anatomically surrounded by many critical normal structures, post-radiotherapy (post-RT) complications are still common regardless of the radiotherapy techniques.

The parotid gland, which is situated laterally to the NP, is one of the organs at risk (OARs) and is often inadvertently irradiated during radiotherapy.<sup>7,8</sup> Radiation-induced xerostomia has been reported in patients treated by both ConRT and IMRT,<sup>9,10</sup> although the latter presented with a lower incidence. Xerostomia usually starts from the mid-stage of radiotherapy course and persists after the treatment, and its severity is dose dependent.<sup>5,9</sup> Although saliva flow may slowly recover after radiotherapy, full recovery is unlikely and xerostomia can develop into a life-long problem.<sup>11,12</sup>

Although IMRT has been reported with reduced severity of xerostomia in NPC patients relative to ConRT due to relatively lower mean dose to the parotid gland,<sup>6,12,13</sup> the pattern of radiation induced geometric changes of the parotid gland, which is associated with the parotid gland function,<sup>10</sup> has not been fully studied. Therefore, the aim of this study was to investigate the differences in the pattern of parotid gland radiologically determined geometric changes during and shortly after radiotherapy between ConRT and IMRT, which was related to the difference in total dose delivered to the parotid gland.

© Cambridge University Press 2018. This is an Open Access article, distributed under the terms of the Creative Commons Attribution licence (<http://creativecommons.org/licenses/by/4.0/>), which permits unrestricted re-use, distribution, and reproduction in any medium, provided the original work is properly cited.

## Methods

This was a retrospective study. A total of 56 adult NPC patients, half of them treated by ConRT ( $n=28$ ) and the other half by IMRT ( $n=28$ ) between 2011 and 2013 in an oncology department, were randomly retrieved from the patient database. The choice of the radiotherapy techniques was mainly based on the oncologists' preference and the financial condition of the patients. For the ConRT group, the patients were either treated with three to five coplanar or non-coplanar beams to the NP region, and an anterior cervical beam was used to cover the neck lymphatics. The radiation beams were stationary with fixed apertures using 6 MV photons. The treatment was delivered in two phases in which the second phase treated the clinical target volume with a reduced margin. Prescribed doses of 66–68 Gy and 60–66 Gy in 30–33 fractions were given to the NP and cervical nodal targets, respectively. For the IMRT group, inverse planning was used in which the patients were treated with seven to nine coplanar beams to the facio-cervical region using 6 MV photons. Dynamic MLC were used to generate intensity modulated beams. The clinical target volumes and planning target volumes of both primary tumour and neck lymphatics were treated by simultaneous integrated boost; 70–72 Gy and 60–66 Gy to the clinical target volumes of NP and neck lymphatics, respectively, in 32–35 fractions were prescribed. Both groups of patients were treated in supine head straight position and immobilised with the thermo-plastic shell and head rest.

For each patient, planning computed tomography (CT) scan of the head and neck region in the treatment position were performed in the CT-simulator before radiotherapy. Four repeated kilovoltage CT scans were carried out at intervals around 10<sup>th</sup>, 20<sup>th</sup> and 30<sup>th</sup> fractions, and at 3 months after completion of treatment with the patients in the treatment position. After obtaining the CT images, the parotid glands of each patient in the planning CT were contoured in the Eclipse treatment planning system (Version 11; Varian Medical Systems, Palo Alto, CA, USA) for the generation of treatment plan. For the contouring of the parotid glands in the second to last CT sets, deformable registration between the planning CT and subsequent CTs (intervals at 10<sup>th</sup>, 20<sup>th</sup> and 30<sup>th</sup> fractions, and 3 months after radiotherapy) was carried out using MIM software (Version 6.3.4; MIM Software Inc., Cleveland, OH, USA). All the contouring was performed by the same operator who had been trained to conduct parotid gland delineation using CT images. The total mean dose delivered to the parotid glands for each patient was calculated from their respective treatment plans using the treatment planning system.

For the assessment of parotid gland changes, percentage change of volume ( $\Delta\%V$ ) and dice similarity coefficient (DSC) were obtained. DSC, which indicated the spatial overlap between two volumes,<sup>14</sup> was defined by  $(V_o, V_s) = 2|V_o \cap V_s| / (|V_o| + |V_s|)$ , where  $V_o$  and  $V_s$  were the volumes of original parotid gland and subsequent parotid gland at various time intervals, respectively, and  $\cap$  was the intersection. A value of 1.0 would indicate perfect volume match between the two volumes, whereas 0 would imply no overlapping of volume. Translational displacements in  $x$ ,  $y$  and  $z$  axes and total vector displacement (TVD), which was the three-dimensional displacement of the centroid, were obtained by comparing the parotid gland in each subsequent CT with that of the original planning CT using the MIM software. In addition to the parotid gland measurement, the change in lateral dimension of the patient's head ( $\Delta D_L$ ) was also measured which was an indication of the patient's size. The lateral dimension of the patient's

head was defined as the width of the line perpendicular to the mid-line in the CT slice at level of the superior tip of the odontoid process (Figure 1).<sup>15</sup> The average values of each measured parameter for the ConRT and IMRT groups were calculated and compared. Normality test was conducted in each set of data. Independent  $t$ -test or Mann–Whitney test was conducted dependent on the normality of the data. All statistical tests were performed using Statistical Package for Social Science version 22 (IBM).

## Results

### Patient characteristics

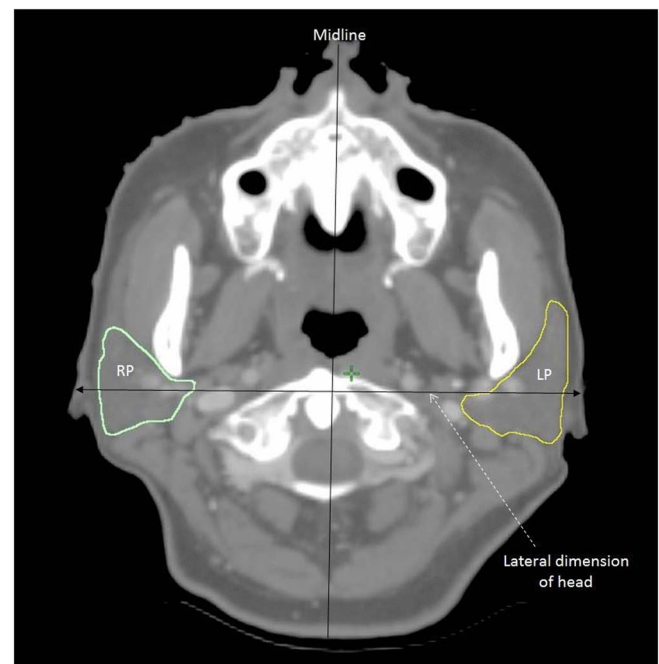
The age range and gender proportion of the two study groups were similar (Table 1). Over 75% of the patients belong to Stage III and IV (AJCC 2010 system) in both groups. The baseline mean parotid gland volume in the IMRT group was similar to that of the ConRT group (Table 2). The mean parotid gland doses in the ConRT and IMRT groups were  $49.1 \pm 7.4$  Gy and  $37.5 \pm 9.5$  Gy, respectively. The difference in mean parotid gland dose between the two groups was statistically significant ( $p < 0.001$ ).

### Lateral head dimension

For both ConRT and IMRT groups, the mean lateral head dimension decreased continuously during the radiotherapy course and reached a minimum at 30<sup>th</sup> fraction interval (Figure 2). Their differences between the ConRT and IMRT group were not significant until at 3 months after radiotherapy where the IMRT group demonstrated smaller  $\Delta D_L$  value than the ConRT group ( $p = 0.017$ ).

### Percentage parotid volume change

The mean parotid volume in both groups decreased with a maximum reduction of 35% at the 30<sup>th</sup> fraction (Figure 3). There were no significant differences between the ConRT and IMRT groups from 10<sup>th</sup> to 30<sup>th</sup> fractions. Volume recovery was observed



**Figure 1.** A transverse computed tomographic (CT) slice at the level of the tip of odontoid process showing the measurement of lateral dimension of the head.

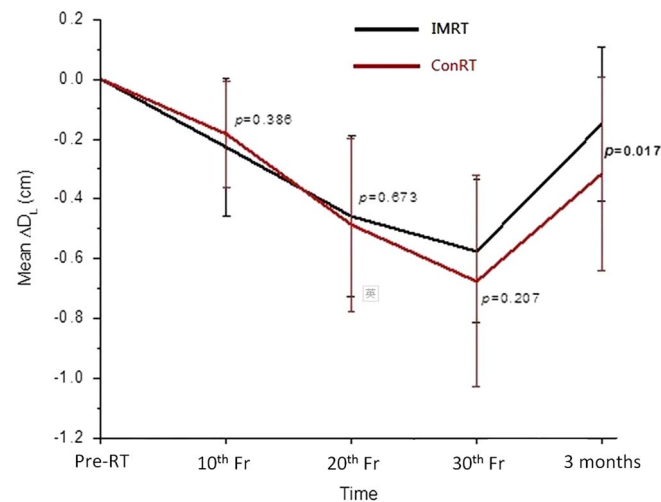
**Table 1.** Patient characteristics

	ConRT (n = 28)	IMRT (n = 28)
Age (years)	47.2 ± 9.6	50.8 ± 11.5
Gender		
Male	19 (67.9%)	20 (71.4%)
Female	9 (32.1%)	8 (28.6%)
Stage (AJCC 2010)		
I	0 (0%)	2 (7.14%)
II	4 (14.3%)	5 (17.9%)
III	16 (57.1%)	9 (32.1%)
IV	8 (28.6%)	12 (42.9%)

Abbreviations: ConRT, conventional radiotherapy; IMRT, intensity-modulated radiotherapy; AJCC, American Joint Committee on Cancer 2010 staging system.

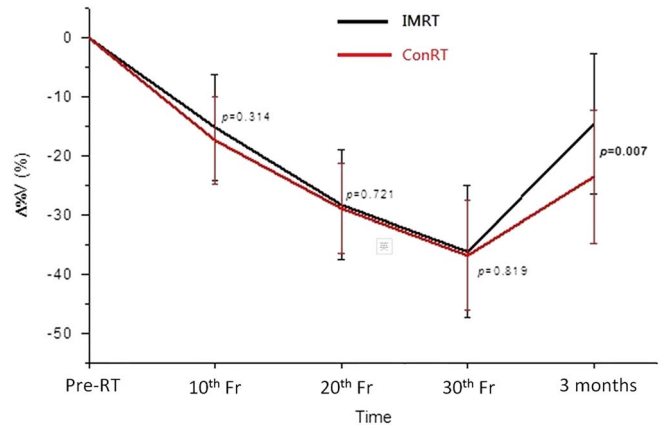
**Table 2.** Comparison of the baseline (Pre-RT) parotid gland volume between the conventional radiotherapy (ConRT) and intensity-modulated radiotherapy (IMRT) groups

	Parotid gland volume (cm <sup>3</sup> )		p value
	ConRT (n = 28)	IMRT (n = 28)	
	Mean ± SD	Mean ± SD	
Left	23.0 ± 6.4	24.6 ± 7.5	0.394
Right	23.3 ± 7.0	25.5 ± 8.7	0.302
Overall	23.1 ± 6.6	25.1 ± 8.1	0.316

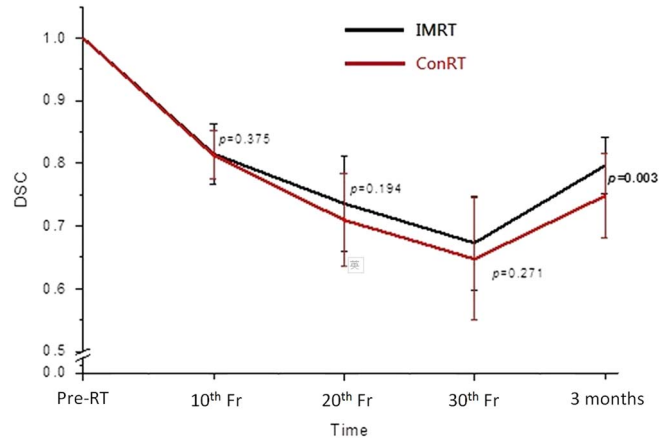


**Figure 2.** Comparison of the mean change of lateral dimension of head between conventional radiotherapy (ConRT) and intensity-modulated radiotherapy (IMRT) plans over the radiotherapy course up to 3 months post-treatment. Note: The horizontal lines indicate the error bars.

in both groups at 3 months following RT with significantly greater recovery in the IMRT group ( $p = 0.007$ ). The trend of DSC was similar to that of the volume change. It decreased from pre-treatment to 30<sup>th</sup> fraction and partially recovered at 3 months after treatment (Figure 4). Significant difference between ConRT and IMRT was only noted at the 3 months post-RT interval with



**Figure 3.** Comparison of the mean percentage change of volumes of parotid glands between conventional radiotherapy (ConRT) and intensity-modulated radiotherapy (IMRT) plans over the radiotherapy course up to 3 months after treatment. Note: The horizontal lines indicate the error bars.



**Figure 4.** Comparison of the mean dice similarity coefficients (DSC) of parotid glands between conventional radiotherapy (ConRT) and intensity-modulated radiotherapy (IMRT) plans over the radiotherapy course up to 3 months after treatment. Note: The horizontal lines indicate the error bars.

the IMRT group demonstrating a better restoration of the original shape ( $p = 0.003$ ).

### Displacement of parotid gland

The centroid of the parotid gland demonstrated movement during the treatment course, in which the displacement in *x*- (medio-lateral) direction was the greatest followed by the *z*- (supero-inferior) and *y*- (antero-posterior) directions (Table 3). At 30<sup>th</sup> fraction, the centroid had moved medially, superiorly and posteriorly from the original position. This pattern was demonstrated by both ConRT and IMRT groups, and there were no significant differences in displacement between the two groups. For both groups, the TVD of the centroid demonstrated an increasing deviation during the treatment course, and then moved back to some extent at 3 months after treatment (Figure 5). The ConRT group showed greater TVD than the IMRT group, but their differences did not reach statistical significance except at 3 months post-RT interval ( $p < 0.001$ ).

### Discussion

With regard to the geometric changes of the parotid gland during radiotherapy, our study demonstrated that there were no significant differences between patients treated by ConRT and

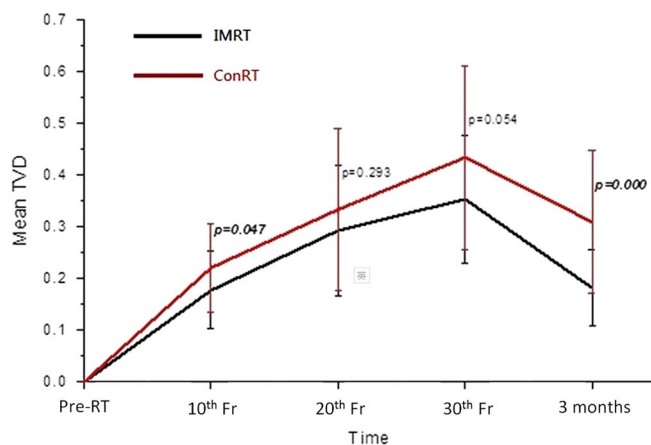
**Table 3.** Displacement of the centroid of the parotid gland along the x, y and z axes at 30<sup>th</sup> fraction for the conventional radiotherapy (ConRT) and intensity-modulated radiotherapy (IMRT) groups

	ConRT (n = 28)	IMRT (n = 28)	p value
	Mean ± SD	Mean ± SD	
Δx (cm)	-0.31 ± 0.19	-0.25 ± 0.17	0.218
Δy (cm)	-0.10 ± 0.09	-0.09 ± 0.08	0.662
Δz (cm)	0.18 ± 0.15	0.20 ± 0.18	0.653

Notes: Δx = deviation along the x-direction (medio-lateral): -ve = towards mid-line; +ve = away from mid-line.

Δy = deviation along the y-direction (antero-posterior): -ve = towards posterior; +ve = towards anterior.

Δz = deviation along the z-direction (supero-inferior): -ve = towards inferior; +ve = towards superior.



**Figure 5.** Comparison of the mean total vector displacement (TVD) of centroid of parotid glands between the conventional radiotherapy (ConRT) and intensity-modulated radiotherapy (IMRT) plans over the radiotherapy course up to 3 months after treatment. Note: The horizontal lines indicate the error bars.

IMRT. For both groups of patients, the parotid gland demonstrated continuous shrinkage and medial migration during the treatment course. They were reflected by the increase of Δ%V, DSC and TVD from pre-treatment to 30<sup>th</sup> fraction, respectively. The shrinkage of parotid glands during radiotherapy has been reported in previous studies<sup>16,17</sup> and it was mainly caused by the loss of gland parenchyma and acinar cell atrophy due to high dose radiation.<sup>18,19</sup> The volume reduction of the parotid gland subsequently changed its shape and therefore resulted in a similar trend in DSC as for Δ%V. This medial migration of the parotid gland during radiotherapy was caused by the shrinkage of radiosensitive NP tumour, which was situated medially to the parotid gland and created space for the parotid gland to move in. Another associated factor could be due to the weight loss of the patients, whose head size became smaller leading to the lateral structures moved closer to the mid-plane. Actually such medial movement of the parotid gland during radiotherapy course has been reported by some studies.<sup>20,21</sup> Our study has shown that NPC patients generally had gradual weight loss during a course of radiotherapy. This was reflected by the reduction of the lateral head dimension. The phenomenon of weight lost, however, may vary across other institutions depending on nutritional support given. This is a common phenomenon for head and neck cancer patients as a result of poorer nutritional status due to radiation induced oral mucositis and xerostomia. The effect would be compounded with

concurrent chemotherapy, which is commonly applied for stage II disease or above for NPC patients.

Due to the better target dose conformity in IMRT plans, they were more effective in sparing the parotid gland than the conRT plans in NPC patients. This was proven in our study in which the average mean parotid dose of the IMRT group was about 12 Gy lower than that of the ConRT group. This was also the reason that higher prescribed dose to the target could be given in IMRT than in ConRT plans, which subsequently led to better tumour control.<sup>22,23</sup> Although the geometric changes of the ConRT group appeared relatively greater than that of the IMRT group during the radiotherapy course, their differences did not reach significance. This implied that the extra dose delivered by the ConRT to the parotid gland did not lead to significant geometric change during the treatment course. The possible reasons were because the mean doses of both groups had already exceeded the recommended tolerance mean dose of 25 Gy,<sup>24</sup> the extra dose delivered by the ConRT would not cause significant increase of parotid gland damage. Nevertheless, the results obtained at 3 months after treatment demonstrated that IMRT plans showed better recovery of parotid gland volume, shape and centroid position. For instance, the mean parotid volume returned to 85% of pre-treatment volume in IMRT group, compared with 75% in ConRT group. This indicated that although the rate of parotid gland damage was similar during the course of radiotherapy, the rate of recovery after completion of treatment was different between the two techniques. It has been reported that parotid recovery took place after completion of radiotherapy<sup>25</sup> which were in line with the geometric changes obtained in our study. In addition, study by Hey et al.<sup>25</sup> reported that the recovery process of the parotid gland could be dose dependent. It was also proposed in some studies that stem cells in the parotid gland were responsible for the post-RT repair if they were not eliminated in the treatment course.<sup>26</sup> As the more conformal IMRT plans are better equipped to limit the high dose to a smaller volume, and deliver lower mean dose to the gland, it can help to preserve more stem cells in the gland and facilitate better recovery. The improved recovery of the parotid gland in the IMRT cohort may be attributed to this improved opportunity for stem cell recovery.

This study is the first to demonstrate that in radiotherapy of NPC patients, the geometric changes of parotid gland started at around the 2<sup>nd</sup> week of the radiotherapy course. Despite the changes in ConRT and IMRT during the radiotherapy course remain similar, patients in the IMRT group showed better parotid gland recovery after treatment. One limitation of this study was that the use of the parotid gland size as a surrogate measure for its function has not been proven, although there have been studies reported that the geometric changes of the parotid gland was associated with saliva production.<sup>10,27</sup> Another limitation of this study was that we could not conduct examinations after 3 months post-RT and changes of the parotid gland at later stages was not assessed. Therefore, studies with longer follow-up duration are suggested to evaluate the long-term difference between the two techniques. In addition, assessment of the salivary flow rate and patient xerostomia condition feedback at a longer follow-up time would reveal more information.

## Conclusion

In the radiotherapy of NPC patients, both ConRT and IMRT demonstrated similar degree of parotid gland shrinkage and shifting during the radiotherapy course. However, the recovery of the parotid gland volume after treatment was more significant in

the IMRT group. Our study demonstrated lower parotid dose from the IMRT technique brought about better volume recovery of the gland shortly after completion of radiotherapy.

**Acknowledgements.** None.

**Financial support.** None.

**Conflict of interest.** None.

**Ethical standards.** All procedures contributing to this work comply with the ethical standards of the relevant national guidelines on human experimentation and with the Helsinki Declaration of 1975, as revised in 2008, and has been approved by the institutional committee of Sun Yat-sen University Cancer Center.

## References

- Teo P M, Ma B B, Chan A T. Radiotherapy for nasopharyngeal carcinoma – transition from two-dimensional to three-dimensional methods. *Radiother Oncol* 2004; 73: 163–172.
- Luo W, Ye L, Yu Z, He Z, Li F, Liu M. Effectiveness of three-dimensional conformal radiotherapy for treating early primary nasopharyngeal carcinoma. *Am J Clin Oncol* 2010; 33: 604–608.
- Zhang B, Mo Z, Du W, Wang Y, Liu L, Wei Y. Intensity-modulated radiation therapy versus 2D-RT or 3D-CRT for the treatment of nasopharyngeal carcinoma: A systematic review and meta-analysis. *Oral Oncol* 2015; 51: 1041–1046.
- Lee A W, Ng W T, Hung W M et al. Major late toxicities after conformal radiotherapy for nasopharyngeal carcinoma-patient- and treatment-related risk factors. *Int J Radiat Oncol Biol Phys* 2009; 73: 1121–1128.
- Kam M K, Chau R M, Suen J, Choi P H, Teo P M. Intensity-modulated radiotherapy in nasopharyngeal carcinoma: Dosimetric advantage over conventional plans and feasibility of dose escalation. *Int J Radiat Oncol Biol Phys* 2003; 56: 145–157.
- Peng G, Wang T, Yang K Y et al. A prospective, randomized study comparing outcomes and toxicities of intensity-modulated radiotherapy vs. conventional two-dimensional radiotherapy for the treatment of nasopharyngeal carcinoma. *Radiother Oncol* 2012; 104: 286–293.
- Porter S R, Scully C, Hegarty A M. An update of the etiology and management of xerostomia. *Oral Surg Oral Med Oral Pathol Oral Radiol Endod* 2004; 97: 28–46.
- Tribius S, Bergelt C. Intensity-modulated radiotherapy versus conventional and 3D conformal radiotherapy in patients with head and neck cancer: Is there a worthwhile quality of life gain? *Cancer Treat Rev* 2011; 37: 511–519.
- Zheng Y, Han F, Xiao W et al. Analysis of late toxicity in nasopharyngeal carcinoma patients treated with intensity modulated radiation therapy. *Radiat Oncol* 2015; 10: 17.
- Wu V W, Ying M T, Kwong D L. Evaluation of radiation-induced changes to parotid glands following conventional radiotherapy in patients with nasopharyngeal carcinoma. *Br J Radiol* 2011; 84: 843–849.
- Dirix P, Nuyts S, van den Bogaert W. Radiation-induced xerostomia in patients with head and neck cancer. *Cancer* 2006; 107: 2525–2534.
- Saarihtti K, Kouri M, Collan J et al. Intensity modulated radiotherapy for head and neck cancer: Evidence for preserved salivary gland function. *Radiother Oncol* 2005; 74: 251–258.
- Nutting C M, Morden J P, Harrington K J et al. Parotid-sparing intensity modulated versus conventional radiotherapy in head and neck cancer (PARSPORT): A phase 3 multicentre randomised controlled trial. *Lancet Oncol* 2011; 12: 127–136.
- Zou K H, Warfield S K, Bharatha A et al. Statistical validation of image segmentation quality based on a spatial overlap index. *Acad Radiol* 2004; 11: 178–189.
- Cao J, Luo J, Xu G et al. Probe into the clinical significance of target volume and change of the normal organs in image-guided radiotherapy for nasopharyngeal carcinoma. *Chin J Radiat Oncol* 2007; 16: 81–85.
- Barker J L Jr, Garden A S, Ang K K et al. Quantification of volumetric and geometric changes occurring during fractionated radiotherapy for head-and-neck cancer using an integrated CT linear accelerator system. *Int J Radiat Oncol Biol Phys* 2004; 59: 960–970.
- Zhang Y, Lin C, Wu J et al. A longitudinal evaluation of early anatomical changes of parotid gland in intensity modulated radiotherapy of nasopharyngeal carcinoma patients with parapharyngeal space involvement. *J Med Radiat Sci* 2017; 64: 188–194.
- Radfar L, Sirois D A. Structural and functional injury in minipig salivary glands following fractional exposure to 70 Gy of ionizing radiation: An animal model for human radiation induced salivary gland injury. *Oral Surg Oral Med Oral Pathol Oral Radiol Endod* 2003; 96: 267–274.
- Wang Z H, Yan C, Zhang Z Y et al. Radiation-induced volume changes in parotid and submandibular glands in patients with head and neck cancer receiving postoperative radiotherapy: A longitudinal study. *Laryngoscope* 2009; 119: 1966–1974.
- Fung W K, Wu V W, Teo P M. Developing an adaptive radiation therapy strategy for nasopharyngeal carcinoma. *J Radiat Res* 2014; 55: 293–304.
- Barker J L, Garden A S, Ang K K et al. Quantification of volumetric and geometric changes occurring during fractionated radiotherapy for head-and-neck cancer using an integrated CT/linear accelerator system. *Int J Radiat Oncol Biol Phys* 2004; 59: 960–970.
- Au K H, Ngan R K C, Ng A W Y et al. Treatment outcomes of nasopharyngeal carcinoma in modern era after intensity modulated radiotherapy (IMRT) in Hong Kong: A report of 3328 patients (HKNPCSG1301 study). *Oral Oncol* 2018; 77: 16–21.
- Yan H, Cao X, Wang J. Application of intensity-modulated radiation therapy in the treatment of nasopharyngeal carcinoma. *Oncol Lett* 2017; 14: 7773–7776.
- Deasy J O, Moiseenko V, Marks L et al. Radiotherapy dose-volume effects on salivary gland function. *Int J Radiat Oncol Biol Phys* 2010; 76: S58–S63.
- Hey J, Setz J, Gerlach R et al. Parotid gland-recovery after radiotherapy in the head and neck region–36 months follow-up of a prospective clinical study. *Radiat Oncol* 2011; 6: 125.
- Feng J, van der Zwaag M, Stokman M A, van Os R, Coppes R P. Isolation and characterization of human salivary gland cells for stem cell transplantation to reduce radiation-induced hyposalivation. *Radiother Oncol* 2009; 92: 466–471.
- Teshima K, Murakami R, Tomitaka E et al. Radiation-induced parotid gland changes in oral cancer patients: Correlation between parotid volume and saliva production. *Jpn J Clin Oncol* 2010; 40: 42–46.